



Abdominal Mondor disease mimicking acute appendicitis



Myriam Schuppisser^a, Joe Khallouf^a, Ziad Abbassi^b, Michel Erne^a, Denise Vettorel^a, Alexandre Paroz^a, Surennaidoo P. Naiken^{a,*}

^a Division of General Surgery, Etablissement Hospitalier du Nord Vaudois, Yverdon-les-Bains, Switzerland

^b Clinic for Visceral and Transplantation Surgery, Departments of Surgery, University Hospital of Geneva, Geneva, Switzerland

ARTICLE INFO

Article history:

Received 14 October 2015

Received in revised form 3 December 2015

Accepted 17 December 2015

Available online 13 January 2016

Keywords:

Mondor disease

Right lower quadrant pain

Thrombophlebitis

Epigastric vessels

ABSTRACT

INTRODUCTION: Mondor disease (MD), a superficial thrombophlebitis of the thoraco-epigastric veins and their confluents is rarely reported in the literature. The superior epigastric vein is the most affected vessel but involvement of the inferior epigastric vessels or their branches have also been described. There is no universal consensus on treatment in the literature but most authors suggest symptomatic treatment with non-steroid anti-inflammatory drugs (NSAIDs).

CASE REPORT: We report the case of a marathon runner who presented with right iliac fossa pain mimicking the clinical symptomatology of an acute appendicitis. The history and the calculated Alvarado score were not in favor of an acute appendicitis. This situation motivated multiple investigations and we finally arrived at the diagnosis of MD.

DISCUSSION: Acute appendicitis (AA) is the most common cause of surgical emergencies and one of the most frequent indications for an urgent abdominal surgical procedure around the world. In some cases, right lower quadrant pain remains unclear in spite of US, CT scan, and exclusion of urological and gynecological causes, thus we need to think of some rare pathologies like MD.

CONCLUSION: MD is often mentioned in the differential diagnosis of breast pathologies but rarely in abdominal pain assessment. It should be mentioned in the differential diagnosis of the right lower quadrant pain when the clinical presentation is unclear and when acute appendicitis has been excluded. Awareness of MD can avoid misdiagnosis and decrease extra costs by sparing unnecessary imaging.

© 2016 The Authors. Published by Elsevier Ltd. on behalf of IJS Publishing Group Ltd. This is an open access article under the CC BY-NC-ND license (<http://creativecommons.org/licenses/by-nc-nd/4.0/>).

1. Introduction

Mondor disease (MD) was first described by Henri Mondor in 1939 [1]. It is an uncommon condition which occurs mostly in the middle aged population and is three times more common in women than men [2,3]. It is characterized by superficial thrombophlebitis of the thoraco-epigastric veins and/or their confluents and mainly presents in the vessels of the anterolateral thoraco-abdominal wall which involves the superior epigastric vessels. There are cases of thrombophlebitis of the inferior epigastric vessels and veins of the

upper limbs [2]. This pathology can also rarely arise in the groin, arm, and axilla [4].

There are three classifications of MD. Type 1, involves the chest wall, Type 2 involves other venous districts, mainly the dorsal vein of the penis and Type 3 occurs after breast surgery [5].

It is a very rare condition where less than 500 cases have been reported in the literature [5]. It is underreported and underdiagnosed mainly because many patients do not seek medical attention as it is a benign and self-limited disorder [1]. There is no typical clinical presentation of this disease, however most of the reported cases present with a subcutaneous, tender, cord-like induration, where the overlying skin is freely mobile lacking inflammatory signs [1,3]. Some of these lesions are asymptomatic while others are extremely painful and cause severe discomfort [1]. Symptoms typically last from 6 to 8 weeks before complete resolution [2], but in some reported cases it can last up to 6 months [5]. There has been no evidence report of any long term sequelae as it is a benign self-limiting condition [2].

Diagnosis of Mondor disease is clinical, based on history and physical examination [2]. However ultrasound and Doppler ultrasonography may be necessary not only to confirm MD, but also to

Abbreviations: MD, Mondor disease; AA, acute appendicitis; CT, computed tomography; US, ultrasound; MRI, Magnetic Resonance Imaging; RLO, right lower quadrant; NSAIDs, non-steroid anti-inflammatory drugs.

* Corresponding author at: Rue Entremonts 17, 1400 Yverdon-les-bains, Switzerland.

E-mail addresses: myriam.schuppisser@gmail.com (M. Schuppisser), khallouf88@gmail.com (J. Khallouf), ziad.abbassi@hcuge.ch (Z. Abbassi), michel.erne@ehnv.ch (M. Erne), denise.vettorel@ehnv.ch (D. Vettorel), alexandre.paroz@ehnv.ch (A. Paroz), drnaikensuren@hotmail.com, drnaikensuren@gmail.com (S.P. Naiken).

<http://dx.doi.org/10.1016/j.ijscr.2015.12.031>

2210-2612/© 2016 The Authors. Published by Elsevier Ltd. on behalf of IJS Publishing Group Ltd. This is an open access article under the CC BY-NC-ND license (<http://creativecommons.org/licenses/by-nc-nd/4.0/>).

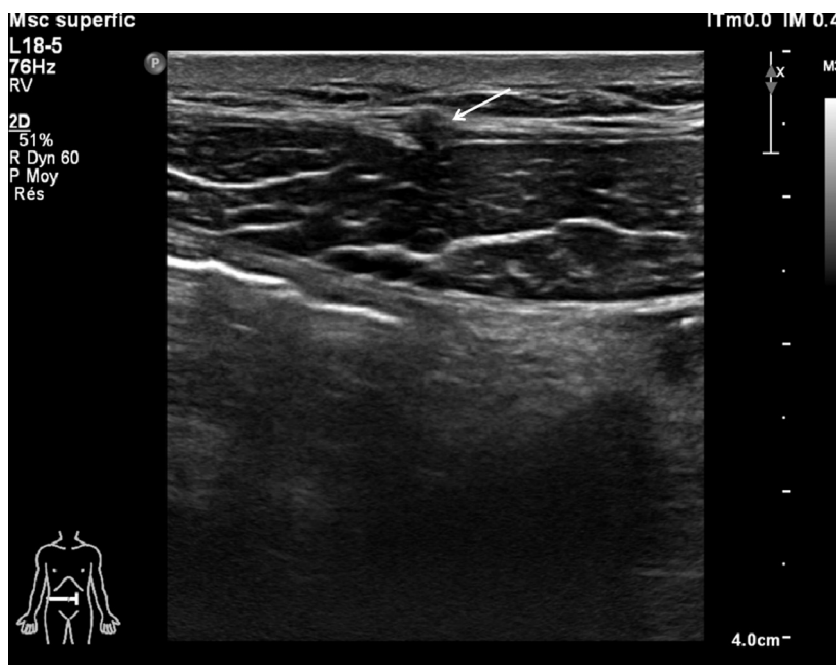


Fig. 1. Doppler US showing thrombophlebitis of the inferior epigastric veins superficial to the rectus abdominis muscle on the right.

exclude other differential diagnoses such as presence of an underlying compressing mass [1].

We discuss a case of an abdominal MD who presented right lower quadrant pain and clinical manifestation that mimicked an acute appendicitis. This case report highlights the difficulty to diagnose such a condition due to its rare entity.

2. Case report

A 46 year old male patient, marathon runner, presented to our Emergency Department with localized right lower quadrant pain (RLQ) of one week duration. The only past surgical intervention was an orchidopexy during childhood for right undescended testis.

The main complaints of the patient were excruciating RLQ pain mainly when seated and in upright positions. The symptoms were exacerbated with body movements but relieved only in supine position. The other associated symptoms were nausea.

Clinical examination revealed guarding and rigidity at the Mc Burney point. There was rebound tenderness and a positive psoas sign. The Rovsing sign was negative. There were neither palpable masses nor any cutaneous lesions. The patient felt pain on active and passive flexion above 90° on examination of the right hip; however no pain was reproduced on internal and external rotation. Neurological exam was normal.

Laboratory findings were within the normal range except for a mild isolated elevation of the CRP of 12.5 mg/l. The calculated Alvarado score was 4 [6,7]. Due to uncertainty of the diagnosis, a standard intravenously enhanced CT scan was performed without any abnormality detected. It also ruled out the classic differential diagnoses of right lower quadrant pain.

The patient was hospitalized for monitoring and pain management with non-steroid anti-inflammatory agents (NSAIDs). There was no improvement even when the daily laboratory investigations showed no inflammatory or infectious processes. Due to the exacerbating, movement dependent right lower quadrant pain (RLQ), a Magnetic Resonance Imaging (MRI) of the lumbar spine was performed and a specialized opinion of the neurologist was obtained.

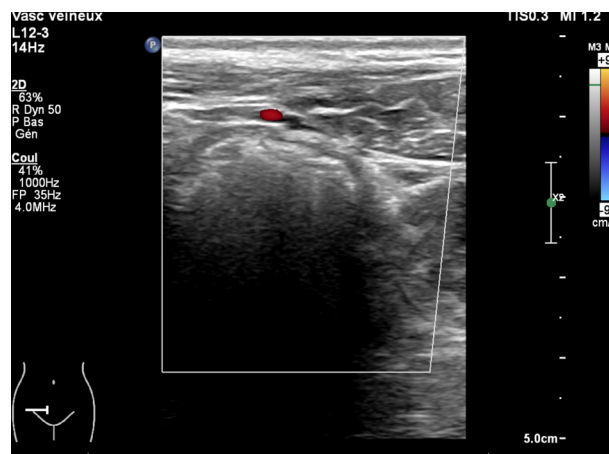


Fig. 2. Follow up US was performed 11 weeks later and showed a complete resolution of the thrombophlebitis.

The imaging and neurological assessment revealed no neurological pathologies.

Finally an abdominal Doppler US showed a thrombophlebitis of the inferior epigastric veins superficial to the rectus abdominis muscle on the right (Fig. 1). The patient was hospitalized for a total of 10 days and was discharged home after he regained near-normal mobility.

A follow up US was performed 11 weeks later and showed a complete resolution of the thrombophlebitis (Fig. 2). The patient's symptoms, however, persisted for 5 months after initial presentation. There was no recurrence during one year follow up and the patient resumed his marathon runs without any handicap.

3. Discussion

Right lower quadrant pain is a frequent complaint observed in the emergency department with appendicitis as the most featured

surgical pathology [8]. The physician is faced with differential diagnoses ranging from gastrointestinal, urological, and gynecological pathologies. In medium and high income countries, diagnosis is aided with a wide array of the radiological investigations [9,10]. Sensitivity and specificity of the US are highly operator dependent and on the patient's body size. CT exposes the patient to more ionizing radiation and therefore less suitable for young patients. In some cases, underlying cause of right lower quadrant pain may remain unclear in spite of US and CT scan. After exclusion of abdominal, urological and gynecological causes, the diagnosis of MD should be evoked in unclear presentation of RLQ pain, despite its rarity [11].

There are descriptions of several predisposing factors but the etiology of this disorder remains unclear. In most cases, MD is related to direct and indirect trauma such as surgery, muscular strain [12,13], electrocution, and venous compression from tight clothing [1]. Some authors related the condition to bacterial or viral infections, anatomical variation of the venous arcade, or the use of vasoconstrictor drugs [1]. Rarely, MD has been linked with prothrombotic states including protein S deficiency [14] and anticardiolipin antibody [15]. The most common cause however remains local trauma [2,11].

In elderly patients without an obvious triggering factor, it is imperative to exclude an underlying malignancy (especially in classic and penile syndrome), or other prothrombotic state [2]. For our patient, we retained that the repeated trauma, associated with running marathons, were the likely trigger for this condition [18,19]. We cannot exclude that the past surgery of right orchidopexy, during childhood, resulted to MD. There are reports in the literature that surgery and venous compression have both been associated with Mondor disease [1,12,13].

No universal consensus exists about the optimal therapeutic management of MD, as several treatment options are acceptable [5]. Most patients require symptomatic treatment with anti-inflammatory drugs [3,16]. Studies have showed that the administration of antiplatelet agents and heparin did not help to heal or to prevent additional local thrombosis [1]. In case of severe unrelenting pain, local infiltration of anesthetic agents may be required to help in the resolution of the symptoms [17]. When this treatment is not sufficient, or in case of recurrent disease, a thrombectomy or superficial vein resection may be necessary [1,6]. For our patient, a combination of NSAIDs and local infiltration of bupivacaine 0.25% achieved noticeable improvement of symptoms.

There is, however, evidence to suggest that patients who contract inguinal Mondor disease are predisposed to experience recurrent episodes [2].

4. Conclusion

Mondor disease is another rare cause of right lower quadrant pain and should be considered in the differential diagnosis of complex and unclear clinical manifestations, when acute appendicitis has been excluded. It is a very uncommon finding mainly due to underreporting by the patients, as it is often self-limiting disorder, but also due to the unfamiliarity of the physician with this pathology. Awareness can help to relieve the patients but also spare unnecessary investigations.

Conflict of interest

None.

Funding

No sources of funding for this research.

Ethical approval

Ethical approval has been granted from the concerned hospital.

Consent

Informed consent was obtained from the patient for publication and available upon request.

Author contributions

(1) Dr. Myriam Schuppisser—collecting the data, writing the paper, drafting the article and revising it.

(2) Dr. Joe Khallouf—writing the paper, drafting the article and revising it.

(3) Dr. Ziad Abassi—revising the article.

(4) Dr. Erne Miche—revising the article.

(5) Dr. Vettorel Denise—revising the article.

(6) Dr. Paroz Alexandre—revising the article.

(7) Dr. Surenaidoo P. Naiken—writing the paper and revising it.

Guarantor

Dr. Myriam Schuppisser is the sole guarantor.

Acknowledgements

Joseph Pacifique, MD for providing assistance and the review of the literature, Patricia Nin, MD for providing the radiological imagery and interpretations, Antonino Sgroi, MD-PhD, for final revision and corrections.

References

- [1] H. Alvarez-Garrido, A.A. Garrido-Ríos, C. Sanz-Muñoz, A. Miranda-Romero, Mondor's disease, *Clin. Exp. Dermatol.* 34 (October (7)) (2009) 753.
- [2] M. Tuveri, R. Spada, V. Borsezio, A. Gabbas, Atypical Mondor's disease mimicking a strangulated Spigelian hernia in a patient with a deep venous obstruction. A case report, *Chir. Ital.* 58 (September–October (5)) (2006) 649–653.
- [3] P. Fietta, P. Manganelli, Mondor's diseases spectrum of the clinical and pathological features, *Minerva Med.* 93 (December (6)) (2002) 453–456.
- [4] Y. Shoham, N. Rosenberg, Y. Krieger, E. Silberstein, O. Arnon, A. Bogdanov-Berezovsky, Axillary web syndrome: a variant of Mondor's disease, following excision of an accessory breast, *Harefuah* 150 (December (12)) (2011) 893–894, 937,936.
- [5] G. Cervellini, M. Creta, M. Riva, V. Di Comite, L. Buttarelli, G. Lippi, Abdominal Mondor's disease presenting as acute abdominal pain. A case report and literature review, *Acta Biomed.* 84 (September (2)) (2013) 155–158.
- [6] A. Alvarado, A practical score for the early diagnosis of acute appendicitis, *Ann. Emerg. Med.* 15 (May (5)) (1986) 557–564.
- [7] R. McKay, J. Shepherd, The use of the clinical scoring system by Alvarado in the decision to perform computed tomography for acute appendicitis in the ED, *Am. J. Emerg. Med.* 25 (June (5)) (2007) 489–493.
- [8] G.R. Williams, Presidential address: a history of appendicitis. With anecdotes illustrating its importance, *Ann. Surg.* 197 (1983) 495.
- [9] P.A. Poletti, A. Platon, T. De Perrot, F. Sarasin, E. Anderegg, O. Rutschmann, et al., Acute appendicitis: prospective evaluation of a diagnostic algorithm integrating ultrasound and low-dose CT to reduce the need of standard CT, *Eur. Radiol.* 21 (December (12)) (2011) 2558–2566.
- [10] C.D. Douglas, N.E. Macpherson, P.M. Davidson, J.S. Gani, Randomised controlled trial of ultrasonography in diagnosis of acute appendicitis, incorporating the Alvarado score, *BMJ* 321 (October (7266)) (2000) 919–922.
- [11] W.E. Jones, J.N. Hamm, Right lower quadrant pain due to thrombosis of the inferior epigastric vein: case report, *SD J. Med. Pharm.* 15 (May) (1962) 178–179.
- [12] M. Onder, B. Canpolat, B. Aksakal, M.A. Gurer, Case of Mondor's disease of the abdomen (body-building induced), *Int. J. Dermatol.* 44 (April (4)) (2005) 345–346.
- [13] S.E. Efem, Mondor's disease in the groin, *Br. J. Surg.* 74 (June (6)) (2016) 468.
- [14] J.M. De Godoy, M.F. Godoy, F. Bastigalia, D.M. Brail, The association of Mondor's disease with protein S deficiency: case report and review of literature, *J. Thromb. Thrombolysis* 13 (2002) 187–189.

- [15] F. Boehlen, M. Bader, P. de Moerloose, Superficial thrombophlebitis of the chest wall associated with anticardiolipin antibodies: antiphospholipid syndrome of Mondor's disease, *Lupus* 13 (2004) 70–71.
- [16] J. Bircher, A. Schirger, O.T. Clagett, E.G. Harrison Jr., Mondor's disease: a vascular rarity, *Mayo Clin. Proc.* 37 (1962) 651–656.
- [17] M. Mayor, J. Calvo-Mora, Mondor's disease, *Int. J. Dermatol.* 39 (2000) 922–925.
- [18] B.P. Greida, P.La. Luchko, Mondor's disease in athletes, *Klin. Med.* 61 (May (5)) (1983) 56–58.
- [19] B.P. Greida, T.A. Tkachenko, Etiology, clinical aspects and treatment of Mondor's disease in sportsmen, *Sov. Med.* (8) (1983) 101–103.

Open Access

This article is published Open Access at scimedirect.com. It is distributed under the [IJSCR Supplemental terms and conditions](#), which permits unrestricted non commercial use, distribution, and reproduction in any medium, provided the original authors and source are credited.