

Minimally Invasive Modified Latarjet Procedure in Patients With Traumatic Anterior Shoulder Instability

Mohammad Hossein Ebrahimzadeh^{1,*}; Ali Moradi²; Ahmad Reza Zarei¹

¹Orthopedic Research Center, Ghaem Hospital, Mashhad University of Medical Sciences, Mashhad, IR Iran

²Department of Orthopedic Surgery, Orthopedic Research Center, Mashhad University of Medical Sciences, IR Iran

*Corresponding author: Mohammad Hossein Ebrahimzadeh, Orthopedic Research Center, Ghaem Hospital, Mashhad University of Medical Sciences, Ahmad-Abad Street, P.O. Box: 91799-99199, Mashhad, IR Iran, Tel: +98-5138012610, Fax: +98-5138413494, E-mail: Ebrahimzadeh@ums.ac.ir

Received: July 3, 2014; Accepted: January 25, 2015

Background: Despite recent advances in arthroscopic soft tissue repair and reconstruction for shoulder instability, Latarjet procedure is continuously a method of choice for many cases of unstable shoulders.

Objectives: To evaluate the clinical results of minimally invasive modified Latarjet technique in recurrent, traumatic anterior shoulder instability associated with obvious Hill-Sachs and Bankart lesions.

Patients and Methods: Between 2007 and 2013, 36 consequent patients with traumatic anterior shoulder instability who underwent modified Latarjet operation were enrolled in this prospective study. The MRI studies revealed labrum detachment and Hill-Sachs lesion in all shoulders. For all patients, demographic and injury data were obtained and Constant Shoulder score, Rowe score, and UCLA scores were completed by related surgeon. Stability of the shoulder was assessed with the Jobe's relocation test preoperatively. The patients were followed up at two weeks, one month, three months, and six months from the date of the surgery and evaluated for probable complications. Above mentioned assessments were completed again at the time of the final follow-up.

Results: The average age of the enrolled patients was 24.6 (ranging from 18 to 33 years) and 35 patients out of the total of 36 patients were males. Motor-vehicle accidents were the major cause of the injuries (52%) with the average interval between the injury and operation of 3.1 ± 1.2 years (Ranging from 1 to 5 years). The average number of incidents of dislocations between the injury date and the surgery was 7.2 ± 2.1 (Ranging from 4 to 20). The average follow-up period was 37 months (Ranging from 12 to 65 months). All patients had Jobe's relocation test (Apprehension sign) pre-operatively and negative Jobe's relocation test post-operation. Significant improvements in functional scores were demonstrated postoperatively compared to preoperational assessment in all cases. Final follow up radiographs showed union of all the grafts and patients reported no incidents of re-dislocation during the follow-up period. One incidence of a superficial infection 2 weeks post operation was the only complication in this study. The infection was resolved with antibiotic treatment.

Conclusions: The Latarjet procedure demonstrated good or excellent short-term outcomes in management of patients with traumatic, recurrent anterior shoulder dislocation with a low level of post-operative complication risks.

Keywords: Shoulder; Joints; trauma

1. Background

The shoulder is the most commonly dislocated joint due to its large range of motion and weak bony support. It is estimated that this joint accounts for 50% of all major joint dislocations (1). The most common complication after a shoulder dislocation is recurrent dislocations (2). Bankart lesion, defined as labrum detachment from the glenoid rim, is the most significant pathological basis for the recurrent dislocations (3, 4). Bony defects in humeral head (Hill-Sachs lesion) and glenoid labrum, are the other two known causes of recurrent dislocation (1, 2). Up to 76% of recurrent shoulder dislocations show presence of Hill-Sachs lesions (5-7).

In 1950, Latarjet et al. proposed a successful technique to repair a glenoid rim defect using the coracoid process as a structural bone graft (8). The Latarjet technique used to be employed in patients suffering from recurrent shoulder dislocation particularly in glenoid bone defects (8).

The technique has been modified since the conception by extracapsular placing of the graft through the middle part of the subscapularis tendon rather than detaching the superior one-third of the subscapularis muscle (9). In this study, we evaluated the mid-term results of minimally invasive modified Latarjet technique in traumatic anterior recurrent dislocations associated with gross Hill-Sachs and Bankart lesions.

2. Objectives

To evaluate the clinical results of minimally invasive modified Latarjet technique in recurrent, traumatic anterior shoulder instability associated with obvious Hill-Sachs and Bankart lesions.

3. Patients and Methods

For this prospective observational study, we enrolled all 36 patients with recurrent traumatic anterior shoulder

instability who underwent minimally invasive modified Latarjet procedure in Ghaem Hospital, Mashhad, Iran between 2007 and 2013. All participants were consenting adults with a history of at least two previous anterior dislocations of the same shoulder and glenoid defect of more than 30% in CT scan. The exclusion criteria included a previous surgical stabilization of the shoulder. The osseous defects and Bankart lesion were evaluated preoperatively using plain radiographs, CT scan and MR imaging. The MRI studies revealed labrum detachment and Hill-Sachs lesion in all shoulders. Informed consent was obtained from all participating patients and the Ethical Research Committee of Mashhad Medical University approved the study.

For all patients, demographic and injury data were obtained and Constant Shoulder score, Rowe score, and UCLA scores were completed by the operating surgeon. The shoulder stability was assessed with the Jobe's relocation test preoperation. The patients were followed up at two weeks, one month, three months, and six months from the date of the surgery and evaluated for probable complications. Above mentioned assessments were completed again at the time of the final follow-up by the same surgeon.

The modified Latarjet technique was used in our study. In the original Latarjet technique, all the long part of coracoid process was detached from scapula. After that, the pectoralis minor tendon and coracoacromial

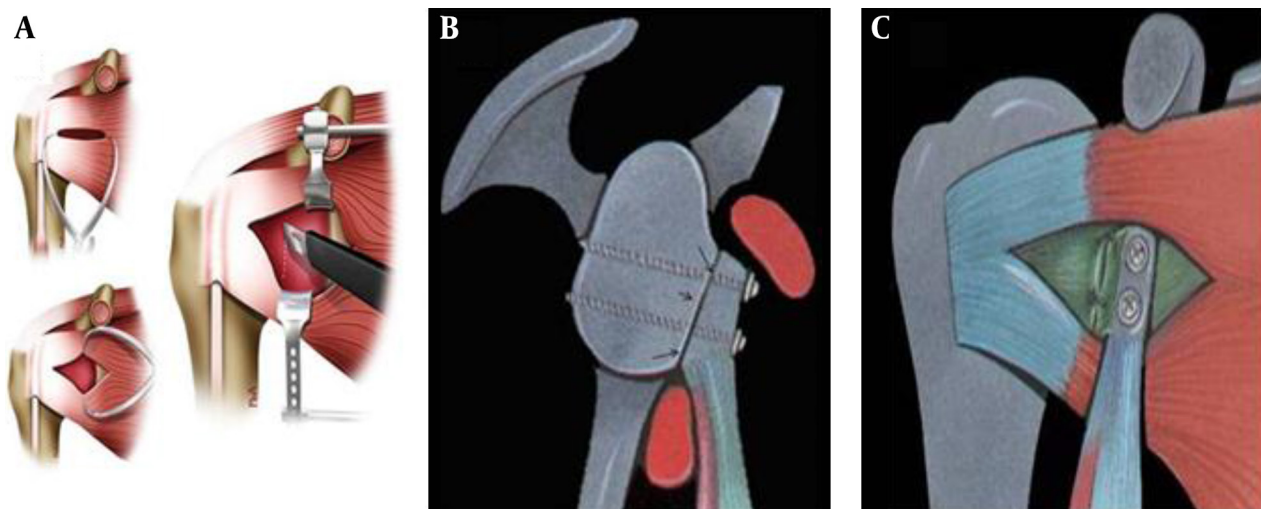


Figure 1. Modified Latarjet Technique

Table 1. Demographic Characteristics in Patient Undergoing Latarjet Operation

Variable	Frequency	Percent	P Value
Gender			< 0.001
Male	35	97.2	
Female	1	2.8	
Etiology			0.091
Motor-Vehicle Accident	19	52.8	
Fall from height	10	27.8	
Fall in sport	4	11.1	
Others	3	8.3	
Affected side			0.23
Right	23	63.9	
Left	13	36.1	
Dominant side			0.11
Right	25	69.4	
Left	11	30.6	

Table 2. Constant Shoulder Test Outcome in Patients Underwent Latarjet Operation

Results ^a	Before Operation		After Operation	
	Frequency	Percent	Frequency	Percent
Excellent	0	0	34	94.4
Good	1	2.8	2	5.6
Fair	14	38.8	0	0
Poor	21	58.4	0	0

^a Excellent = 100 to 90; Good = 89 to 75; Fair = 74 to 51; Poor ≤ 51.

Table 3. Rowe Shoulder Test Outcome in Patients who Underwent Latarjet Operation

Results ^a	Before Operation		After Operation	
	Frequency	Percent	Frequency	Percent
Excellent	0	0	34	94.4
Good	0	0	2	5.6
Fair	7	19.4	0	0
Poor	29	80.6	0	0

^a Excellent = 100 to 90; Good = 89 to 75; Fair = 74 to 51; Poor ≤ 51.

Table 4. UCLA Shoulder Test Outcome in Patients Undergoing Latarjet Operation

Results ^a	Before Operation		After Operation	
	Frequency	Percent	Frequency	Percent
Excellent	0	0	14	38.9
Moderate	0	0	22	61.1
Poor	36	100	0	0

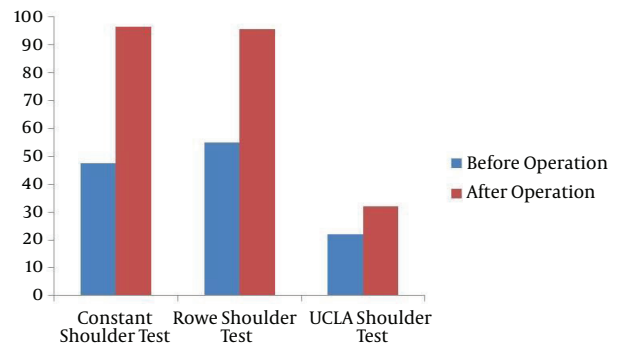
^a Excellent = 100 to 90; Good = 89 to 75; Fair = 74 to 51; Poor ≤ 51.

Table 5. Comparison of Different Shoulder Test Before and After Latarjet Operation

Tests	Before Operation ^a		After Operation ^a		P Value
	Mean	SD	Mean	SD	
Constant Shoulder Test	47.4	8.4	96.5	4	< 0.001
Rowe Shoulder Test	54.9	10.7	95.7	3.6	< 0.001
UCLA Shoulder Test	21.9	4.1	32.1	1.9	< 0.001

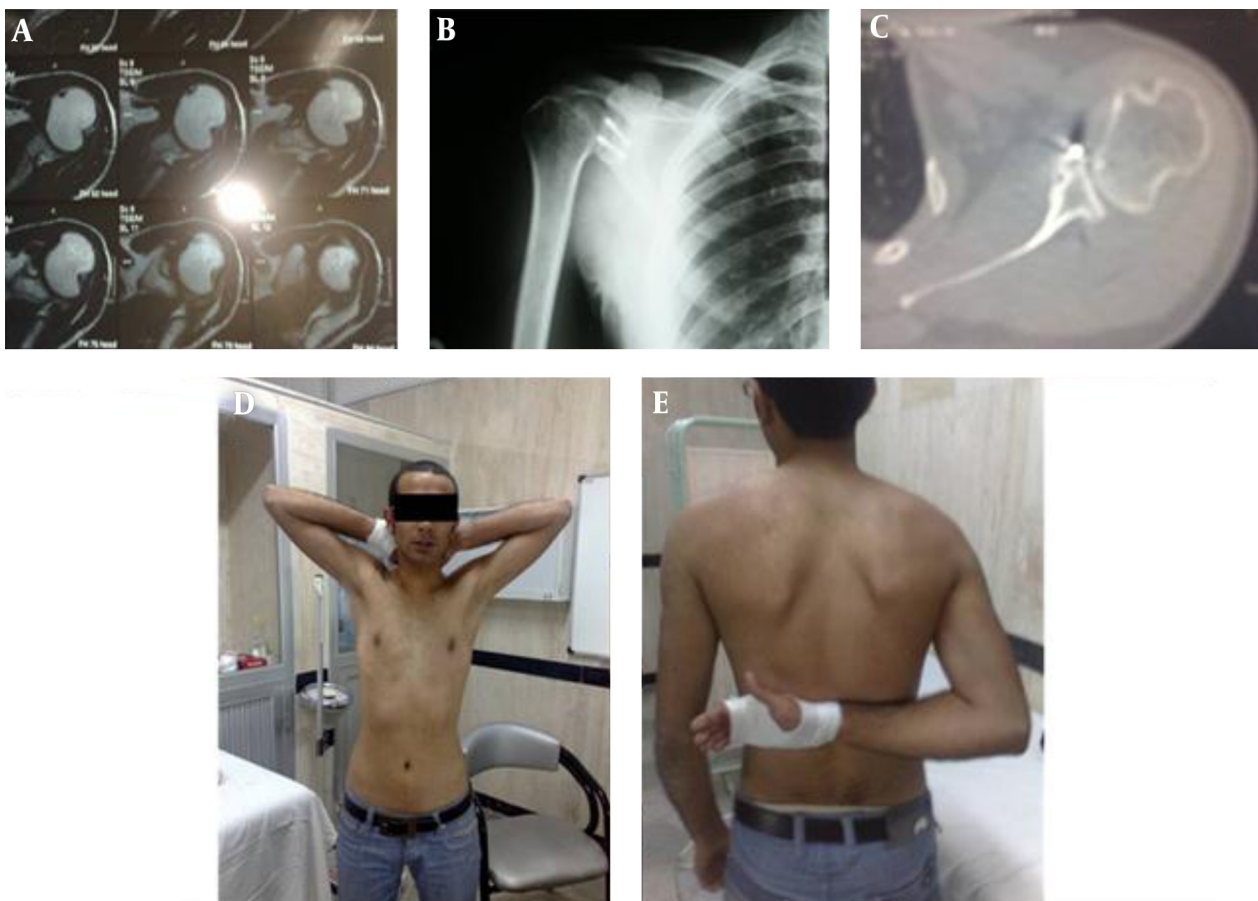^a All values are presented as Mean (SD).

Figure 2. The Mean Scores of Different Shoulder Functional Tests Before and After Latarjet Operation



(Y-axis indicates the tests scores).

Figure 3. A 21 Year-Old Man With History of Anterior Shoulder Instability



A) Bony Bankart lesion and a Hill Sachs lesion on humeral head; B) Post-Operative X-ray; C) Follow-up CT scan shows solid union of the coracoid graft; D) Normal external and internal rotation ranges of motion of the shoulder one year after surgery compared to unaffected side; E) Internal rotation range of motion of the shoulder one year after surgery

ligament were detached and the bone was used as a bony block in the anterior inferior glenoid region between su-

perior one-third two-third of the subscapularis muscle (8). In the modified technique, we split the muscle along the

middle portion of muscle fibers instead of detaching the superior one-third of subscapularis muscle (Figure 1) (9).

The average age of the enrolled patients was 24.6 ± 3.3 (ranging from 18 to 33 years) (Table 1) and 35 patients out of the total of 36 patients were males. Motor-vehicle accidents were the major cause of the injuries (52%, Table 2) with the average interval between the injury and operation of 3.1 ± 1.2 years (Ranging from 1 to 5 years). The average number of incidents of dislocations between the injury date and the surgery was 7.2 ± 2.1 (Ranging from 4 to 20). The average follow-up period was 37 months (ranging from 12 to 65 months).

SPSS version 16 (SPSS Inc, Chicago, IL) was utilized for statistical analysis. The data was presented using mean and standard deviation in continuous variables and frequency and percentage for string variables. Paired t-test was administered for comparing the means of different scores before and after the operation. ANOVA test was used to analyze categorical variables and P value of 0.05 was considered significant.

4. Results

All patients had positive Jobe's relocation test (Apprehension sign) pre-operatively and negative Jobe's relocation test post-operation. Significant improvements in scores were demonstrated after the surgery compared to pre-operational assessment in all cases (P value < 0.001 in all tests) (Table 2 - 5 and Figure 2). Final follow up radiographs showed union of all the grafts and patients reported no incidents of re-dislocation during the follow-up period (Figure 3). One incidence of a superficial infection two weeks post operation was the only complication in this study. The infection was resolved with antibiotic treatment.

5. Discussion

In this study, most of the patients were males in their twenties who sustained the injuries in motor vehicle accidents. The Latarjet procedure demonstrated good or excellent short-term outcomes in management of the patients with traumatic, recurrent anterior shoulder dislocation with a low level of post-operative complication risks.

There are several key points of comparison between this study and the previous studies. While the sample size of this study is within the range of the other studies, ranging for 11 to 113 patients, (3, 9-12), our follow-up period was close to most published studies (3, 9-12). The average age, 24 years old, is also younger than the population of participants in most studies (3, 9, 10, 13-16). The mean age in other studies varied between 26 to 58 years. In our study, almost all of the patients were males in contrast to the gender distribution of the other studies that ranged between 68 and 90 percent (3, 10, 17).

Another mismatch between our population and other studies was the cause of recurrent dislocation. In more

than half of our patients the major cause of the primary shoulder dislocations was motor-vehicle accidents while sports injuries were accounted for 11%. In the study by Cerciello et al. sport injuries were responsible for more than 80% of primary shoulder dislocations and motor-vehicle accidents were only accounted for 4% of patients (18). The discrepancy may be due to the high rate of motor-vehicle accidents in Iran.

In the current study, the time between initial shoulder dislocation due to trauma and surgical intervention was 3 years with on average 7 incidences of dislocations. Doursounian et al. reported the interval of 5 years (17). Lafosse et al. (16) and Hart et al. (12) reported the average of 6 and 5 dislocations before operation

Similar to our study, the Jobe's relocation test of pre-operative patients in previous literature was usually positive in all patients with recurrent dislocation (3, 9, 10, 16). This test was found positive in 2 to 33 percent of patients after operation (3, 9, 10, 16, 19), which is in contrast to our study which showed negative Jobe's relocation test in all shoulders after the operation.

Patients with recurrent shoulder dislocations experience high level of disability before surgical stabilization (10, 12). Hart et al. (12) reported the score of 56 according to Constant questionnaire and Allain et al. (10) reported the score of 51 according to Rowe score before operation indicating similar levels of disability as demonstrated in this study. The dramatic improvement of the shoulder function after the operation mirrored the results seen in the other studies. After operation, Constant score was reported as high as 84 to 95% (9, 10, 14, 16) and Rowe score 90 to 93% (10, 14). In our study, Constant and Rowe scores after operation were 96 and 94 respectively.

Latarjet procedure has known possible complications such as persistent instability (10, 20), fibrous nonunion (9), screw fractures (9), and osteoarthritis (19, 20). In our series we had only one superficial infection. However, the lower rate of complication may be due to the mid-term follow-up.

The key limitations of this study are the short follow-up period, restriction of the patients on one center, and the lack of control groups. The follow-up period was limited to 37 months, which is not long enough to reveal long-term complications such as osteoarthritis and screw breakage. Additionally, we were unable to assess the efficacy of the modified Latarjet technique compared to the other common techniques such as standard Latarjet, Bankart, or Bristow as control groups. Moreover, given the lack of control group, we could not prove that the good results of study were related to the surgery itself or they are the natural healing process or the rehabilitation program after operation. In conclusion, our study demonstrated the minimally invasive Latarjet technique is an effective management approach to recurrent traumatic anterior shoulder dislocations with good or excellent short-term outcomes with a minor complication risk.

References

- Iannotti JP, Gabriel JP, Schneck SL, Evans BG, Misra S. The normal glenohumeral relationships. An anatomical study of one hundred and forty shoulders. *J Bone Joint Surg Am.* 1992;**74**(4):491-500.
- Kroner K, Lind T, Jensen J. The epidemiology of shoulder dislocations. *Arch Orthop Trauma Surg.* 1989;**108**(5):288-90.
- Rowe CR, Patel D, Southmayd WW. The Bankart procedure: a long-term end-result study. *J Bone Joint Surg Am.* 1978;**60**(1):1-16.
- Warner JJ, Miller MD, Marks P. Arthroscopic Bankart Repair With the Suretac Device. Part I: Clinical Observations. *Arthroscopy J.* 1995;**11**(1):2-13.
- DiPaola MJ, Jazrawi LM, Rokito AS, Kwon YW, Patel L, Pahk B, et al. Management of humeral and glenoid bone loss-associated with glenohumeral instability. *Bull NYU Hosp Jt Dis.* 2010;**68**(4):245-50.
- Hovelius L, Eriksson K, Fredin H, Hagberg G, Hussenius A, Lind B, et al. Recurrences after initial dislocation of the shoulder. Results of a prospective study of treatment. *J Bone Joint Surg Am.* 1983;**65**(3):343-9.
- Tauber M, Resch H, Forstner R, Raffl M, Schauer J. Reasons for failure after surgical repair of anterior shoulder instability. *J Shoulder Elbow Surg.* 2004;**13**(3):279-85.
- Latarjet M. [Technic of coracoid pleglenoid arthroereisis in the treatment of recurrent dislocation of the shoulder]. *Lyon Chir.* 1958;**54**(4):604-7.
- Burkhart SS, De Beer JF, Barth JR, Cresswell T, Roberts C, Richards DP. Results of modified Latarjet reconstruction in patients with anteroinferior instability and significant bone loss. *Arthroscopy.* 2007;**23**(10):1033-41.
- Allain J, Goutallier D, Glorion C. Long-term results of the Latarjet procedure for the treatment of anterior instability of the shoulder. *J Bone Joint Surg Am.* 1998;**80**(6):841-52.
- Benammar MN, Saragaglia D, Legrand JJ, Faure C, Butel J. [Latarjet's surgery in recurrent anterior dislocations of the shoulder. 117 cases with an 8-year follow-up]. *Rev Chir Orthop Reparatrice Appar Mot.* 1986;**72**(6):447-54.
- Hart R, Svab P, Krejzla J. [Modified Latarjet procedure for recurrent shoulder dislocation in elderly patients]. *Acta Chir Orthop Traumatol Cech.* 2010;**77**(2):105-11.
- Cassagnaud X, Maynou C, Mestdagh H. [Clinical and computed tomography results of 106 Latarjet-Patte procedures at mean 7.5 year follow-up]. *Rev Chir Orthop Reparatrice Appar Mot.* 2003;**89**(8):683-92.
- Di Giacomo G, Costantini A, de Gasperis N, De Vita A, Lin BK, Francone M, et al. Coracoid graft osteolysis after the Latarjet procedure for anteroinferior shoulder instability: a computed tomography scan study of twenty-six patients. *J Shoulder Elbow Surg.* 2011;**20**(6):989-95.
- Edouard P, Beguin L, Degache F, Fayolle-Minon I, Farizon F, Calmels P. Recovery of rotators strength after Latarjet surgery. *Int J Sports Med.* 2012;**33**(9):749-55.
- Lafosse L, Boyle S, Gutierrez-Aramberri M, Shah A, Meller R. Arthroscopic Latarjet procedure. *Orthop Clin North Am.* 2010;**41**(3):393-405.
- Doursounian L, Debet-Mejean A, Chetboun A, Nourissat G. Bristow-Latarjet procedure with specific instrumentation: study of 34 cases. *Int Orthop.* 2009;**33**(4):1031-6.
- Cerciello S, Edwards TB, Walch G. Chronic anterior glenohumeral instability in soccer players: results for a series of 28 shoulders treated with the Latarjet procedure. *J Orthop Traumatol.* 2012;**13**(4):197-202.
- Collin P, Rochcongar P, Thomazeau H. [Treatment of chronic anterior shoulder instability using a coracoid bone block (Latarjet procedure): 74 cases]. *Rev Chir Orthop Reparatrice Appar Mot.* 2007;**93**(2):126-32.
- Dossim A, Abalo A, Dosseh E, Songne B, Ayite A, Gnandi-Pio F. [Bristow-Latarjet repairs for anterior instability of the shoulder: clinical and radiographic results at mean 8.2 years follow-up]. *Chir Main.* 2008;**27**(1):26-30.