



# Dendriform pulmonary ossification complicated by recurrent spontaneous pneumothorax: Two case reports and a review of the literature

Yang Gao<sup>a,b</sup>, Ashley M. Egan<sup>b</sup>, Teng Moua<sup>b,\*</sup>

<sup>a</sup> Division of Pulmonary Medicine, Guang'anmen Hospital China Academy of Chinese Medical Sciences, Beijing, China

<sup>b</sup> Division of Pulmonary and Critical Care Medicine, Mayo Clinic, Rochester, MN, USA

## ARTICLE INFO

### Keywords:

Dendriform pulmonary ossification  
Pneumothorax  
Obstructive lung disease  
Ectopic bone formation

## ABSTRACT

**Background:** Dendriform pulmonary ossification (DPO) is a rare disease characterized by the presence of mature bone in the lung parenchyma with typical radiologic findings of diffuse and numerous calcified nodules. We present two cases of primary DPO complicated by recurrent spontaneous pneumothorax.

**Case presentation:** Case 1 is a 53-year-old male with recurrent pneumothorax unresponsive to chest tube drainage or subtotal pleurotomy via video assisted thoracoscopy (VATS) who was finally treated with talc pleurodesis. Chest computed tomography (CT) revealed bilateral partially calcified reticulonodular opacities with a basal predominance. VATS biopsy revealed patchy foci of fibrous organizing pneumonia with multifocal ossifications confirming DPO histopathology. Pneumothorax recurred on the same side eight months later managed with talc pleurodesis. Case 2 is a 45-year-old Caucasian male who presented for evaluation of three prior spontaneous left-sided pneumothoraces occurring over eight years, treated with chest tube drainage and eventual talc pleurodesis. Chest CT demonstrated multiple high attenuation peripheral branching opacities greatest in the left lower lobe with several nonspecific, non-calcified pulmonary nodules. VATS biopsy revealed cicatricial organizing pneumonia with associated extensive intraalveolar ossification consistent with DPO.

**Conclusions:** We describe two cases of DPO complicated by recurrent pneumothorax and reviewed the world literature. Summarized findings included a propensity for middle-aged males with a generally indolent course though pneumothorax was often refractory to initial chest tube drainage requiring more definitive mechanical management. There was also a predominance of primary disease without associated causes other than several reports of obstructive lung disease (asthma).

## 1. Introduction

Dendriform pulmonary ossification (DPO) is a rare lung disease characterized by the presence of mature bone in the lung parenchyma with typical radiologic findings of diffuse and numerous calcified nodules. Its pathophysiology is not well understood and treatment options are limited. Although it is commonly described in association with inflammatory conditions or fibrosis such as pathologic usual interstitial pneumonia (UIP), we present two cases of idiopathic DPO complicated by recurrent spontaneous pneumothoraces.

## 2. Case presentation

### 2.1. Case 1

A 53-year-old Caucasian male without underlying cardiopulmonary disease presented to a local emergency room with a one-day history of severe right-sided back and chest pain. The patient was a minimal smoker of only five pack years having quit 30 years prior to presentation. He denied recent infection, trauma, or specific environmental and occupational exposures. On physical examination, vital signs were normal and respiratory auscultation revealed diminished breath sounds on the right compared to the left without wheeze or crackles. Cardiovascular exam was unremarkable. Chest x-ray revealed a moderate-sized

**Abbreviations:** CT, Computed tomography; COPD, chronic obstructive pulmonary disease; DPO, Dendriform Pulmonary Ossification; FEV1, Forced expiratory volume in 1 s; FVC, Forced expiratory vital capacity; NPO, nodular pulmonary ossification; VATS, video assisted thoracoscopy; UIP, usual interstitial pneumonia.

\* Corresponding author. Division of Pulmonary and Critical Care Medicine, Mayo Clinic, 200 First St SW, Rochester, 55905, MN, USA.

E-mail address: [moua.teng@mayo.edu](mailto:moua.teng@mayo.edu) (T. Moua).

<https://doi.org/10.1016/j.rmcr.2020.101067>

Received 4 November 2019; Accepted 21 April 2020

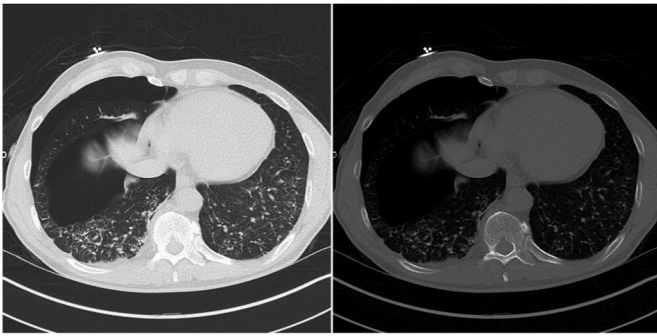
Available online 23 April 2020

2213-0071/© 2020 The Authors.

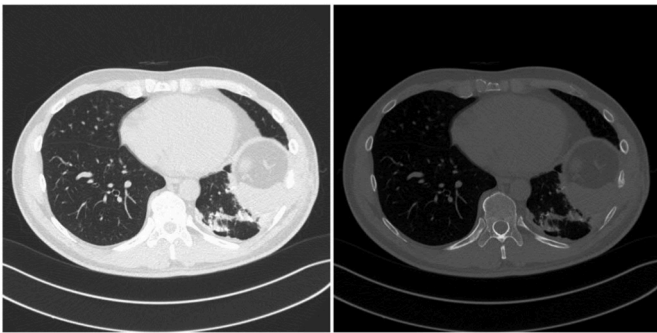
Published by Elsevier Ltd.

This is an open access article under the CC BY-NC-ND license

(<http://creativecommons.org/licenses/by-nc-nd/4.0/>).



**Fig. 1.** (legend) Chest CT showing moderate sized right pneumothorax and bilateral partially calcified branching reticulonodular opacities with a mild basal predominance. Mild architectural distortion was noted without traction bronchiectasis or fibrosis.

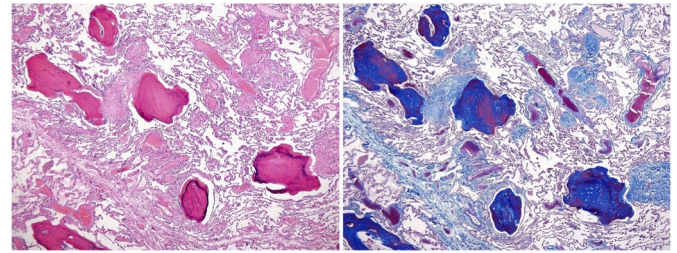


**Fig. 2.** (legend) Chest CT showing multiple foci of high attenuation peripheral branching opacities throughout the left lung, particularly in the left base. No evidence of fibrosis or bronchiectasis.

right pneumothorax. Computed tomography (CT) of the chest revealed bilateral partially calcified branching reticulonodular opacities with a basal predominance (Fig. 1). Mild architectural distortion was noted without traction bronchiectasis, reticulation, or honeycombing. Findings were consistent with likely dendriform pulmonary ossification. The patient was admitted for tube thoracostomy and subsequent video-assisted thoracoscopy (VATS) procedure with subtotal pleurectomy given prolonged air leak and difficulty with clearance. Biopsy results obtained during VATS revealed patchy foci of fibrous organizing pneumonia with multifocal ossifications. Post-procedure pulmonary function testing exhibited mild air trapping with a residual volume at 131% of predicted and isolated low diffusion capacity of 74%. Recurrent pneumothorax on the same side occurred eight months later with a similar presentation of acute dyspnea and chest discomfort. The patient underwent directed talc pleurodesis. After a normal recovery, no additional treatment was pursued with a recommended one-year follow-up chest CT and pulmonary function testing.

## 2.2. Case 2

A 45-year-old never-smoker Caucasian male presented for a second opinion regarding recurrent pneumothoraces. He had three prior left spontaneous pneumothoraces, the first being in 2011 that required chest tube drainage with two subsequent recurrences in 2017 and 2018 treated with mechanical and talc pleurodesis, respectively. Other medical history included childhood asthma with recurrence of symptoms around age 35 well controlled at the time of presentation with budesonide-formoterol, albuterol, and omalizumab. He was retired from the Navy and endorsed exposure to tear gas and beryllium. On presentation he was asymptomatic with normal vital signs. Respiratory auscultation revealed clear breath sounds bilaterally. Cardiovascular



**Fig. 3.** (legend) Section showing fibrotic organizing pneumonia undergoing collagen deposition as well as prominent intraalveolar ossification with branching, dendritic, mature bone formation.

exam was unremarkable. Moderate obstruction (FEV1 2.23L, 55% of predicted; FEV1/FVC 0.60) with positive bronchodilator response was observed on pulmonary function testing. Lung volumes, diffusing capacity, and oximetry at rest and with exercise were normal. Chest CT revealed postoperative changes with multiple foci of high attenuation peripheral branching opacities greatest in the left lower lobe and several small non-calcified pulmonary nodules unchanged in comparison to previous imaging (Fig. 2). Review of prior biopsies suggested DPO with findings of cicatricial organizing pneumonia and associated extensive intra-alveolar ossification (Fig. 3). As the patient was stable and asymptomatic after pleurodesis, it was recommended he repeat a chest CT in approximately one year.

## 3. Discussion and conclusions

DPO is the less common of the two histologic forms of pulmonary ossification, an osseous metaplasia disorder defined by heterotopic mature bone formation (calcification in a collagen matrix) in the lung parenchyma [1–3]. While nodular pulmonary ossification (NPO) is characterized by lobulated bone nodules within alveolar spaces in the absence of fat or marrow elements [4], DPO is characterized by formation of branching bone tissue with marrow elements preferentially affecting the alveolar interstitium and extending through the alveolar septae [2]. Overlap of the two patterns can be found in the same patient [2,5]. DPO is often associated with underlying fibrotic lung disease, chronic inflammation, or sequelae of acute respiratory distress syndrome but may also be idiopathic [9,12]. Pulmonary ossification is considered rare in clinical practice and is often a postmortem diagnosis due to subtle or nonspecific radiologic findings and clinical features. Prevalence in the general population is unknown, but reported incidence at autopsy ranges from 0.16 to 0.5% [2,3,6]. A recent study of 43 patients reported in the literature found a male to female ratio of 6:1 and a mean age at diagnosis of 64 years [6].

There are several proposed hypotheses regarding the etiology of DPO, however, the precise pathogenesis remains uncertain. DPO can be idiopathic or secondary to preexisting conditions such as fibrosis, chronic obstructive pulmonary disease (COPD), adult respiratory distress syndrome, organizing pneumonia, rare earth pneumoconiosis, asbestosis, medication-induced lung injury, and heavy metal exposure [2,7–11]. It is presumed that interactions between pulmonary fibroblasts and macrophages lead to DPO as mediated or induced by various factors including cell and tissue injury, cytokines, growth factors, free radicals, and enzymes [12–14]. Abnormal environmental pH caused by anoxia may also facilitate ossification [5,13]. The familial clustering of some reported cases may imply a genetic predisposition [15,16].

The clinical manifestations of DPO are usually insidious and nonspecific. Patients are often asymptomatic or exhibit only mild chronic cough or dyspnea [6]. DPO complicated by spontaneous pneumothorax is exceedingly rare with only a few previously reported cases [1,15–23]. The exact mechanism for pneumothorax in DPO remains unclear. One proposed mechanism is possible injury to the visceral pleura from exposed peripheral parenchymal ossifications as seen on

**Table 1**  
(Title) Summary of reported cases of diffuse pulmonary ossification complicated by pneumothorax.

Patient number	Gender	Age (at diagnosis)	Smoking history	Medical history	Occupational exposure	Family history	PFT pattern	CT pattern (UIP?)	Recurrence	Treatment	Prognosis	First author	Year
1	Male	51	Unknown	None	None	Unknown	Normal	Unknown	No	Surgery via thoracotomy	Stable	Ekholdt, P.F. [17]	1986
2	Male	42	Former smoker	Asthma	Unknown	Unknown	Obstructive impairment	Non-UIP	Yes	Surgery via thoracotomy	Stable	Ikeda, Y. [18]	1998
3	Male	29	Unknown	None	None	Pulmonary ossification	Unknown	Non-UIP	No	Surgery via VATS	Stable	Azuma, A. [18]	2003
4	Male	33	Non-smoker	Asthma	Unknown	Unknown	Unknown	Non-UIP	No	Surgery via VATS	Stable	Kato, T. [1]	2012
5	Male	83	Non-smoker	Hypertension; carotid and coronary angioplasties	Silica	Unknown	Unknown	Non-UIP	No	Surgery via VATS	Stable	Jungmann, H. [19]	2013
6	Male	68	Non-smoker	Hypertension; chronic bronchitis	Unknown	Unknown	Unknown	Non-UIP	No	Surgery via VATS	Stable	Konoglou, M. [20]	2013
7	Male	53	Unknown	None	Unknown	Unknown	Unknown	Non-UIP	Yes	Surgery via thoracotomy	Stable	Abe, J. [21]	2014
8	Male	26	Non-smoker	None	None	Father with similar chest CT findings in his 30s	Unknown	Non-UIP	Yes	Surgery via VATS	Stable	Tsai, A.P. [16]	2017
9	Male	43	Non-smoker	Atopic dermatitis	None	None	Unknown	Non-UIP	Yes	None	Stable	Edahiro, R. [22]	2018
10	Male	30	Former smoker	Hypertension	Industrial waste	Mother with pulmonary calcification	Restrictive impairment	Non-UIP	No	Tube thoracostomy	Slowly progressed, waiting for lung transplant at 46-years-old	Matsuo, H. [23]	2018
11	Male	53	Former smoker	None	None	None	Obstructive impairment	Non-UIP	Yes	Talc pleurodesis	Stable	Case 1	
12	Male	45	Non-smoker	Asthma	CS gas and beryllium	None	Obstructive impairment	Non-UIP	Yes	Talc pleurodesis	Stable	Case 2	

thoracoscopy [1].

With the addition of our two cases, we found several interesting clinical features of DPO-associated pneumothorax. Ten additional reported cases of DPO complicated by spontaneous pneumothorax [1, 15–23] were found and reviewed (Table 1). All patients including ours were male with an average age of  $46 \pm 17$  years (mean  $\pm$  SD) at the time of diagnosis. While there is a predominance of males in DPO, by comparison, DPO patients are generally diagnosed in their 60s ( $64 \pm 17$ ) [6]. There were no active smokers. Four had chronic lung disease and three had suspected occupational exposure. Asthma history or an obstructive ventilatory defect was found in three and four patients, respectively. This appears consistent with previous findings from an autopsy study noting four out of eight DPO patients also had a history of COPD [2]. Notably, there were no cases of associated lung fibrosis or usual interstitial pneumonia (UIP) pattern in this group [9,10]. Most cases had a favorable outcome, while only one patient experienced slow progression over 16 years leading to lung transplant [23].

No specific treatment for DPO has been identified. Therapeutic approaches reported in the literature are centered on symptom or complication management. Spontaneous pneumothorax in DPO tends to be resistant to conventional treatments. Fifty percent of cases had at least one recurrence; 83.3% of patients ultimately underwent pleurodesis, thoracoscopic surgery, or thoracotomy. Only one patient was stable without any kind of intervention and one was successfully treated with tube thoracostomy alone (Table 1). Although association with chronic lung disease has been reported, there is no data to suggest that DPO progression or risk of pneumothorax is limited by directed treatment of the underlying lung disorders. Individualized imaging and pulmonary function testing for follow-up is recommended. Lung transplant is reserved for severe and progressive cases which occur uncommonly [23, 24].

In conclusion, DPO is a rare disorder with insidious and nonspecific symptoms often diagnosed by imaging and pathologically confirmed on autopsy with a generally benign and slowly progressive course. Spontaneous pneumothorax is an uncommon but clinically significant complication with an apparent propensity (from our cases and a review of the published literature) for younger to middle-aged men demonstrating obstructive pulmonary function findings but not fibrotic or interstitial lung disease, recurring in at least half. DPO-associated pneumothorax has a generally indolent course with good prognosis, though pneumothorax tends to be refractory to initial conservative measures and often requires aggressive management with pleurodesis.

#### Ethics approval and consent to participate

No ethics committee approval was necessary for CASE reports as discussed with our Institutional Review Board (IRB) and its definition of research.

#### Consent for publication

Written informed consent was obtained from the CASE patients using a standardized institutional research consent form.

#### Availability of data and materials

Not applicable.

#### Funding

None.

#### Authors' contribution

YG drafted the manuscript, AME and TM revised and co-wrote the final version. All authors read and approved the final manuscript.

#### Declaration of competing interest

The authors declare that they have no competing interests.

#### Acknowledgements

None.

#### Appendix A. Supplementary data

Supplementary data to this article can be found online at <https://doi.org/10.1016/j.rmcr.2020.101067>.

#### References

- [1] T. Kato, K. Ishikawa, M. Kadoya, K. Okamoto, M. Kaji, Spontaneous pneumothorax in a patient with dendriform pulmonary ossification: report of a CASE, *Surg. Today* 42 (9) (2012) 903–908.
- [2] J.F. Lara, J.F. Catroppo, D.U. Kim, D. da Costa, Dendriform pulmonary ossification, a form of diffuse pulmonary ossification: report of a 26-year autopsy experience, *Arch. Pathol. Lab Med.* 129 (3) (2005) 348–353.
- [3] J. Tseung, J. Duflou, Diffuse pulmonary ossification: an uncommon incidental autopsy finding, *Pathology* 38 (1) (2006) 45–48.
- [4] L. Jamjoom, M. Meziane, R.D. Renapurkar, Dendriform pulmonary ossification: report of two cases, *Indian J. Radiol. Imag.* 23 (1) (2013) 15–18.
- [5] T. Peros-Golubicic, J. Tekavec-Trkanjec, Diffuse pulmonary ossification: an unusual interstitial lung disease, *Curr. Opin. Pulm. Med.* 14 (5) (2008) 488–492.
- [6] S. Fernandez-Bussy, G. Labarca, Y. Pires, J.C. Diaz, I. Caviedes, Dendriform pulmonary ossification, *Respir. Care* 60 (4) (2015) e64–67.
- [7] H.K. Yoon, H.S. Moon, S.H. Park, J.S. Song, Y. Lim, N. Kohyama, Dendriform pulmonary ossification in patient with rare earth pneumoconiosis, *Thorax* 60 (8) (2005) 701–703.
- [8] Y. Ohtsuki, A. Yamanaka, H. Ohyama, E. Yamada, N. Terada, J. Fujita, et al., Histochemical demonstration of aluminum and iron deposition in pulmonary bony tissues in three cases of diffuse pulmonary ossification, *Histol. Histopathol.* 23 (2) (2008) 137–141.
- [9] D.U. Kim, D. Guinee, T.L. Mohammed, Case of the season: usual interstitial pneumonia with dendriform pulmonary ossification, *Semin. Roentgenol.* 50 (1) (2015) 4–7.
- [10] T.S. Kim, J. Han, M.P. Chung, M.J. Chung, Y.S. Choi, Disseminated dendriform pulmonary ossification associated with usual interstitial pneumonia: incidence and thin-section CT-pathologic correlation, *Eur. Radiol.* 15 (8) (2005) 1581–1585.
- [11] J.B. Kuplic, C.S. Higley, D.E. Niewoehner, Pulmonary ossification associated with long-term busulfan therapy in chronic myeloid leukemia. CASE report, *Am. Rev. Respir. Dis.* 106 (5) (1972) 759–762.
- [12] E.D. Chan, D.V. Morales, C.H. Welsh, M.T. McDermott, M.I. Schwarz, Calcium deposition with or without bone formation in the lung, *Am. J. Respir. Crit. Care Med.* 165 (12) (2002) 1654–1669.
- [13] J.M. Jaderborg, R.F. Dunton, Rare clinical diagnosis of dendriform pulmonary ossification, *Ann. Thorac. Surg.* 71 (6) (2001) 2009–2011.
- [14] T. Tsuji, S. Nakamura, I. Komuro, M. Mikami, M. Baba, M. Tanaka, A living CASE of pulmonary ossification associated with osteoclast formation from alveolar macrophage in the presence of T-cell cytokines, *Intern. Med.* 42 (9) (2003) 834–838.
- [15] A. Azuma, H. Miyamoto, T. Enomoto, J. Usuki, S. Kudoh, Familial clustering of dendriform pulmonary ossification, *Sarcoidosis Vasc. Diffuse Lung Dis.* 20 (2) (2003) 152–154.
- [16] A.P. Tsai, J.C. English, D. Murphy, D.D. Sin, Recurrent pneumothorax related to diffuse dendriform pulmonary ossification in genetically predisposed individual, *Respirol. Case Rep.* 5 (2) (2017), e00211.
- [17] P.F. Ekholdt, B.R. Oppedal, P. Arva, Diffuse pulmonary ossification and spontaneous pneumothorax in a pilot: a CASE report, *Aviat Space Environ. Med.* 57 (7) (1986) 696–698.
- [18] Y. Ikeda, H. Yamashita, T. Tamura, Diffuse pulmonary ossification and recurrent spontaneous pneumothorax in a patient with bronchial asthma, *Respir. Med.* 92 (6) (1998) 887–889.
- [19] H. Jungmann, B. Godbert, M.P. Wissler, D. Regent, J.M. Vignaud, Z. Bavelele, et al., Diffuse pulmonary ossification in a patient exposed to silica, *Eur. Respir. Rev.* 22 (128) (2013) 189–190.
- [20] M. Konoglou, P. Zarogoulidis, A. Baliaka, E. Boutsikou, V. Dramba, K. Tsakiridis, et al., Lung ossification: an orphan disease, *J. Thorac. Dis.* 5 (1) (2013) 101–104.
- [21] J. Abe, H. Oura, H. Niikawa, H. Yaegashi, T. Kondo, Dendriform pulmonary ossification: unusual cause of spontaneous pneumothorax, *Thorax* 69 (1) (2014) 97–98.

- [22] R. Edahiro, H. Kurebe, S. Nakatsubo, Y. Hosono, N. Sawa, K. Nishida, et al., Three cases of idiopathic diffuse pulmonary ossification, *Intern. Med.* 58 (4) (2019) 545–551.
- [23] H. Matsuo, T. Handa, M. Tsuchiya, T. Kubo, A. Yoshizawa, Y. Nakayama, et al., Progressive restrictive ventilatory impairment in idiopathic diffuse pulmonary ossification, *Intern. Med.* 57 (11) (2018) 1631–1636.
- [24] J.M. Carney, J.G. Mammarrappallil, T.A. Sporn, E.N. Pavlisko, Dendriform pulmonary ossification leading to bilateral lung transplant: a CASE report, *Virchows Arch.* 473 (3) (2018) 379–383.