

Pitfalls in percutaneous ECMO cannulation

L. Rupprecht¹, D. Lunz², A. Philipp¹, M. Lubnow³, C. Schmid¹

¹Department of Cardiothoracic Surgery; ²Department of Anesthesiology; ³Department of Internal Medicine II/Pneumology, University Medical Center Regensburg, Regensburg, Germany

Heart, Lung and Vessels. 2015; 7(4): 320-326

ABSTRACT

Introduction: This observational report depicts typical problems of extracorporeal membrane oxygenation cannulation from a large case series of a single center.

Methods: We analysed our experience with 720 consecutive patients receiving veno-venous or veno-arterial extracorporeal membrane oxygenation focusing on the spectrum of complications occurring in a subset of 159 patients treated with percutaneous veno-arteria extracorporeal membrane oxygenation in our institution between January 2009 to December 2014.

Results: The main problems were: vascular complications or ischemia of the corresponding extremity (leading to surgical revision in 16.9% of patients); blood loss and/or relocation of cannulas. Hypoxia of the upper body (Harlequin syndrome) occurred in 8.8% of patients. Cannulation failure and malfunction were infrequent. Careful insertion technique, close surveillance and monitoring are compelling.

Conclusion: As lack of experience is the trigger of many complications, adequate training of cannulation techniques is essential to minimize adverse events.

Keywords: ECMO, cannulation, percutaneous, limb ischemia.

INTRODUCTION

More than 50 years ago, extracorporeal membrane oxygenation (ECMO) was designed in parallel to the development of heart-lung machines for long-term cardiopulmonary support. Historically, the two main indications consisted of pediatric respiratory distress and cardiosurgical post-cardiotomy failure.

Along with the availability of the new miniaturized and portable extracorporeal circulation systems, meanwhile, hype was generated for all sorts of extracorporeal support including heart and/or lung failure (1).

Basically, extracorporeal support systems consisting of a pump and an oxygenator are now divided in two major categories: veno-venous ECMO (vv-ECMO) for treatment of isolated severe acute pulmonary failure, and veno-arterial ECMO (va-ECMO), also termed extracorporeal life support (ECLS) to support patients with cardiogenic shock, and, to lesser extent patients with postcardiotomy failure (2). The main indication for va-ECMO is acute myocardial infarction with consequent low cardiac output: these patients are increasingly and have acceptable results when connected to ECMO during resuscitation (3). Few groups gained extensive experience transporting patients on ECMO to specialized tertiary centers for further treatment (4).

Irrespective of type and aim of ECMO support, percutaneous cannulation remains a

Corresponding author:

Leopold Rupprecht, MD
Department of Cardiothoracic Surgery
University Medical Center Regensburg
Regensburg, Germany
e-mail: leopold.rupprecht@klinik.uni-regensburg.de

basic need and sometimes also a challenge, and is prone to complications (5).

We present this observational report to depict and discuss typical ECMO cannulation problems in patients treated in our institution.

METHODS

Patients. From January 2009 to December 2014, 720 patients were treated with ECMO at the Medical Center Regensburg. Approval by the ethical committee was waived because of the retrospective nature of the study. Venous-arterial ECMO was instituted in 302 patients (42%), whereas 418 patients (58%) with severe acute lung failure received vv-ECMO support. Central cannulation was employed only in 63 va-ECMO patients through the ascending aorta (40 patients) or the right subclavian artery (23 patients) for arterial return. Overall, 81 patients (27%) required an open surgical approach for cannula placement: 18 patients with peripheral va-ECMO cannulation and all the 63 patients with central cannulation. Patients with vv-ECMO exclusively underwent percutaneous cannula placement via Seldinger's technique.

Overall, 264 patients (37%) had cannula insertion and ECMO initiation at a remote hospital by our mobile ECMO team and were then transported to our Institution. In 28% of these ECMO transport cases a va-ECMO was inserted.

Cannulation. Our standard femoral cannulation for va-ECMO included a 15 or 17 Fr arterial cannula (length 15 cm) and a 21 or 23 Fr venous cannula (length 55). Cannulas for vv-ECMO were 17 or 19 Fr (length 15 cm) in size for inflow, and 21 or 23 Fr (length 38 cm) in size for outflow. In particular cases of vv-ECMO, the dual lumen single catheter (Avalon, Maquet, Rastatt, Germany) was used in the jugular vein (n = 76, 18%) in various sizes and the sin-

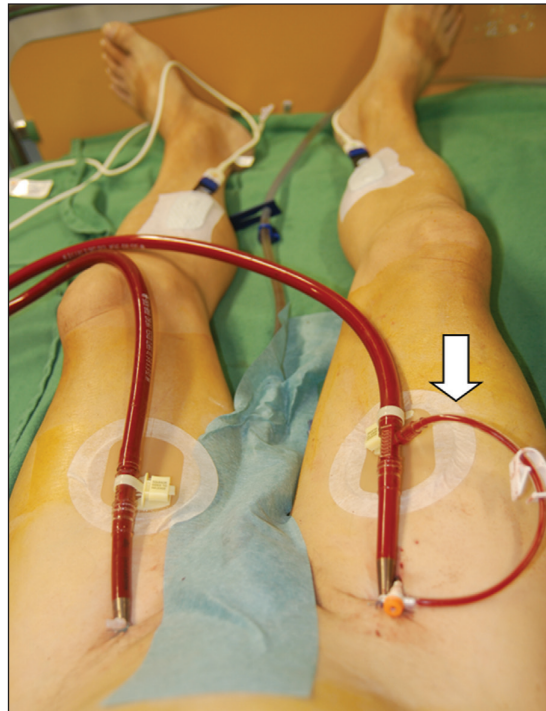


Figure 1 - Correct cannula placement with a distal leg perfusion system for the right femoral artery (arrow).

gle dual lumen NovaPort twin (Novalung, Heilbronn, Germany) was used in the femoral vein (n = 23, 5.5%) (Figure 1).

Data analysis. Detailed data of complications during cannula placement were obtained from a subset of 159 patients with va-ECMO.

In this subset, incidences of conspicuous events were calculated. Complications related to cannulation were exemplified in vivid figures and categorized into cannulation failure, vessel laceration, and cannula malfunction.

RESULTS

Incidences of cannulation problems. Out of the 720 consecutive patients receiving venous-venous or venous-arterial extracorporeal membrane oxygenation in the study period

Table 1 - Conspicuous events and complications during and after percutaneous cannula placement in 159 patients with venous arterial extracorporeal membrane oxygenation.

Event	Consequence	Incidence
Mild limb ischemia	Clinical control	9.4%
Difficult puncture	Multiple attempts	8.8%
Bleeding during cannulation	Blood transfusion	5.7%
Vessel perforation during cannula placement	Surgical revision	1.9%
Upper body hypoxia	Cannula relocation (Subclavian artery)	8.8%
Vascular (femoral) complication	Surgical revision/ contralateral cannula relocation	7.5%
Mild bleeding after cannula removal	No revision	3.8%
Significant bleeding after cannula removal	Surgical revision	3.1%
Cannula dislocation	Cannula reinsertion	0.6%
Wound infection	Wound debridement	0.6%

we describe in *table 1* the spectrum of complications that occurred in a subset of 159 patients treated with percutaneous venoarteria extracorporeal membrane oxygenation. Limb ischemia (16.9%) was the most frequent complication: in 9.4% of patients it was mild and tolerable, whereas in 7.5% of patients it required surgical revision and cannula relocation, mainly to the contralateral side. The second leading problem was the cannulation procedure itself.

In 8.8% of patients vessel puncture was difficult and multiple attempts were necessary to forward a guide wire into the vessel lumen: of these patients vessel perforation occurred in 1.9% of patients and significant blood loss during cannulation was noted in 5.7% of cases. Cannula relocation to the subclavian artery despite an initial correct bifemoral cannula insertion due to an upper body hypoxia, also termed Harlequin syndrome and better described below, was imperative in 8.8% of patients.

After closed cannula removal with local compression of the access site, bleeding was seen in 6.9% of patients, half of them mandated surgical revision.

DISCUSSION

The proper placement of one or two cannulas is a prerequisite for ECMO therapy.

Even if there is no defined technical gold standard for cannula placement, perfect cannulation usually means safe puncture of the correct vessel, insertion of the cannula without vessel laceration and obstruction of the peripheral run-off as well as adequate cannula fixation. Surgical cannula placement remains an appreciated first-line alternative.

In general, all percutaneous cannulations should be accomplished with Seldinger's technique. Long and smooth guide wires are forwarded, if possible under echocardiographic or fluoroscopic control, and the access can be stepwise widened with appropriate dilators before advancing the cannula. An ultrasound estimation of the vessel size can be helpful especially in small patients, and predict the implicit need of a so-called distal limb perfusion (6, 7). Interestingly, in large patients the use of 15F cannulas had no impact on vasoactive medication, hemodynamic parameters, and laboratory parameters, i.e. the small cannulas provided comparable clinical support (8). Vascular calcifications and previous vascular surgery may render cannulation difficult or even impossible. Alternative strategies are then needed, which include targeting another vessel or open surgical cannulation (possibly suturing a Dacron tube).

Close surveillance of limb perfusion is cru-

cial to avoid disastrous ischemic complications. Clinical judgement, pulse palpation, and Doppler sonography of limb vessels serve the purpose well. Recently, it has been demonstrated that near-infrared spectroscopy is another valuable method to monitor tissue oxygenation of lower extremities in ECMO patients (9). Ischemic episodes of lower extremities can be prevented or treated with the insertion of a distal perfusion catheter (10).

Incorrect cannulation. Insertion of multiple catheters and cannulas into femoral vessels may be well performed during percutaneous coronary interventions (*Figure 2*) but is not meaningful for longer-term support such as ECMO.

The compromised flow within the vessels predispose to thrombosis and ischemia of

the lower extremity. Likewise, an additional intra-aortic balloon pump, if indicated, should not be inserted into the same vessel as the arterial ECMO cannula (11). Moreover, if cannula-related bleeding occurs it can be quite cumbersome to achieve proper hemostasis. The amount of catheters also renders wound care difficult and predisposes to infection. Perfect cannula placement is useless unless the cannula is appropriately fixed in its position as it may dislodge easily. Inadequate cannula fixation by loosened sutures or far too distant lashing straps is depicted in *figure 3*.

Unintentional cannulation of a wrong vessel, e.g. a vein for an artery is not uncommon under emergency conditions. No cardiovascular stability with an adequate blood pressure can be reached. Only if hypoxia triggered the low output situation, a hemodynamic improvement with the inadvertently installed vv ECMO can be achieved. Therefore, cannula visualization, usually via Angio-CT scan, is strongly recommended if there is any doubt of cannulation failure.

Cannulation failure. The inability to insert cannulas into the appropriate vessels has the consequence that extracorporeal support is not possible and the patient most likely is threatened with imminent or early death. Main underlying reasons are responsible for cannulation failure:

- 1) morbidly obese patients,
- 2) resuscitation scenarios,
- 3) severe vascular calcifications or scarring.

Either the appropriate vessel cannot be found or the assumed target vessel turns out to be the wrong one. *Figure 4* shows an arterial cannula accidentally placed in the left femoral vein and not yet removed. A venous cannula in the right carotid artery instead of the internal jugular vein is depicted in *figure 5*.

Cannulation failure is a life-threatening

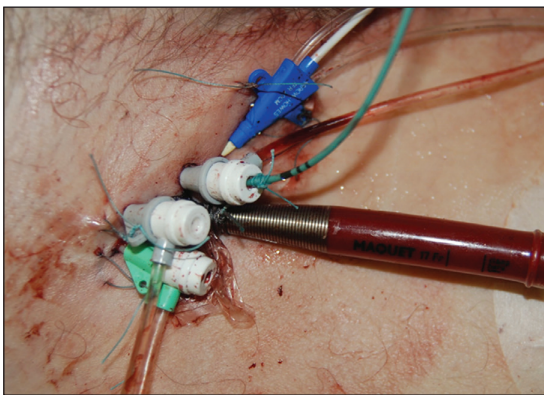


Figure 2 - Multiple catheter and cannula placement into the femoral vessels.

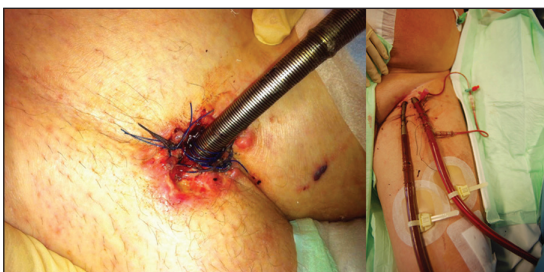

Figure 3 - Inadequate cannula fixation by loosened sutures (left) or far too distant lashing straps (right).

and frequently fatal complication. In a so-called urgent situation, an increase of catecholamine administration may help to stabilize the hemodynamic condition of the

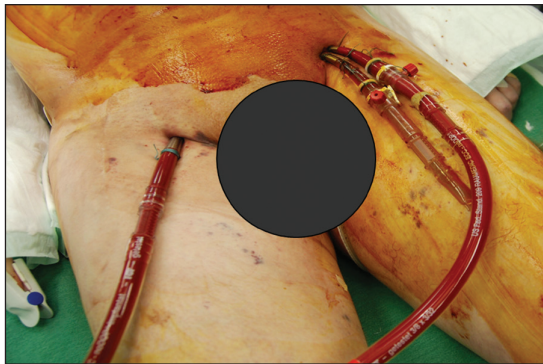


Figure 4 - Cannulation of the wrong vessel - arterial cannula in the left femoral vein.

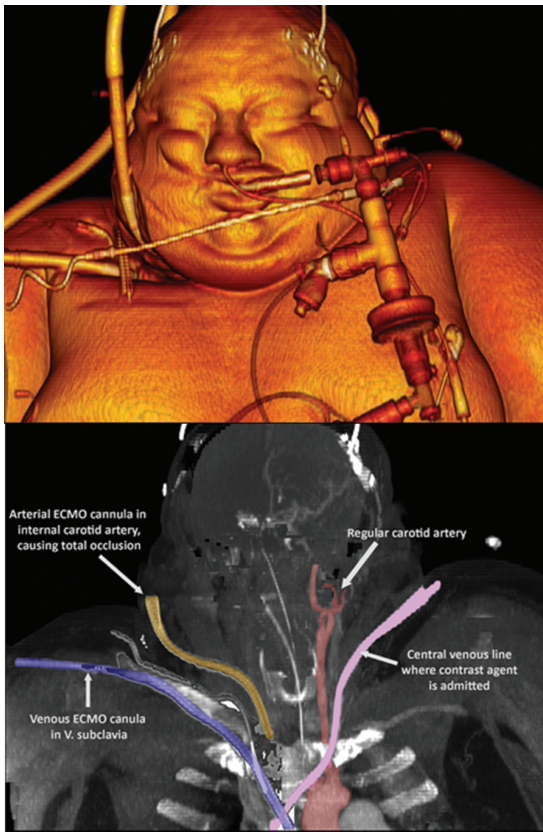


Figure 5 - Cannulation of the wrong vessel - venous cannula in the carotid artery.

patient until other therapeutic options are considered, whereas in an emergency scenario such as ongoing resuscitation with external cardiac massage the patient's only chances are an open access to the femoral vessels or rapid sternotomy with central cannulation. While preparation of the femoral vessels can be quite demanding during cardiac massage, redo surgery conditions and ECMO implantation outside a cardio-surgical center or outside of a hospital typically preclude a central cannulation under emergency conditions.

Vessel laceration. Perforation of a vessel is a serious complication, which can ensue considerable local bleeding. The most frequent serious complication is a large retroperitoneal hematoma. A dissection of the femoral artery is shown in figure 6. Figure 7 illustrates an exceptional venous cannula perforation, which did not bleed and even allowed a borderline pump output due to the side holes of the cannula. A massive retroperitoneal hematoma as typical consequence of a vessel perforation is seen.

Cannulation malfunction. Malfunction of an ECMO system despite intravascular placement of the cannulas means that the flow to or off the cannulas is impaired. Impaired drainage of a venous cannula can occur especially in vv-ECMO. When the tips of the 2 cannulas are too close to each other

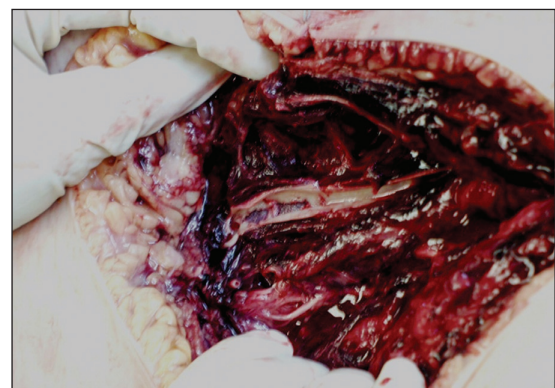

Figure 6 - Dissection of the femoral artery.

er, a short circuit phenomenon will be seen. A significant part of the arterialized blood is directed towards the drainage cannula instead of being routed to the pulmonary artery. The same phenomenon can happen when two femoral cannulas are used (*Figure 8*). When a long feeding femoral cannula in vv-ECMO with multiple side-holes is used a considerable amount of venous blood can be aspirated through the latter even if the tip-to-tip distance is adequate.

On rare occasions, especially when a rather short venous cannula has been used, an abdominal compartment syndrome can compress the inferior vena cava and thus reduce venous backflow (*Figure 9*).

A compromised arterial return can occur despite correct cannula placement. In a va-ECMO setting where the heart has recovered but the lungs are still poorly functioning the native cardiac output bounces against the pumped blood, usually in the aortic arch region. Accordingly, the coronary arteries and to a variable degree the supraaortic vessel as well, are provided with hypoxic blood, heart and brain are harmed. Upper extremity cyanosis has brought up the term “Harlequin syndrome” (*Figure 10*). Therapeutic options consist of a relocation of the arterial cannula in to right subclavian artery or aorta, or in converting the system into a va-v-setting (12). Fracture of a cannula is very uncommon but has to be considered as well (*Figure 11*).

CONCLUSION

Various complications can hamper percutaneous cannula placement while preparing an ECMO support. A careful insertion technique can minimize adverse events and ECMO malfunction, but not abolish it. Close surveillance is imperative. Since many problems during ECMO support arise from missing experience an increase of training capabilities should be provided.

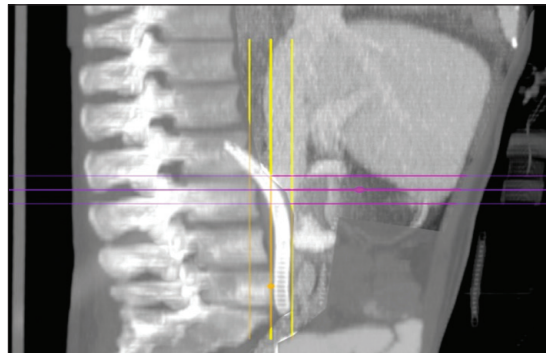


Figure 7 - Perforation of the inferior caval vein.

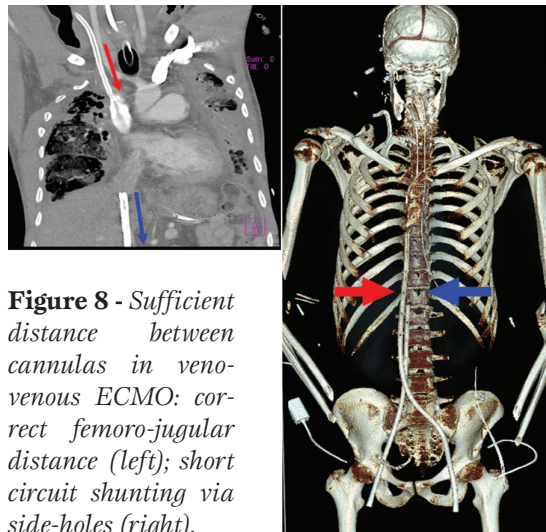


Figure 8 - Sufficient distance between cannulas in veno-venous ECMO: correct femoro-jugular distance (left); short circuit shunting via side-holes (right).

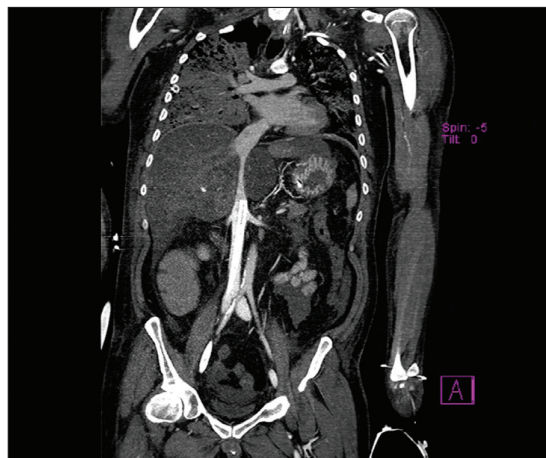


Figure 9 - Abdominal compartment compressing the inferior caval vein.

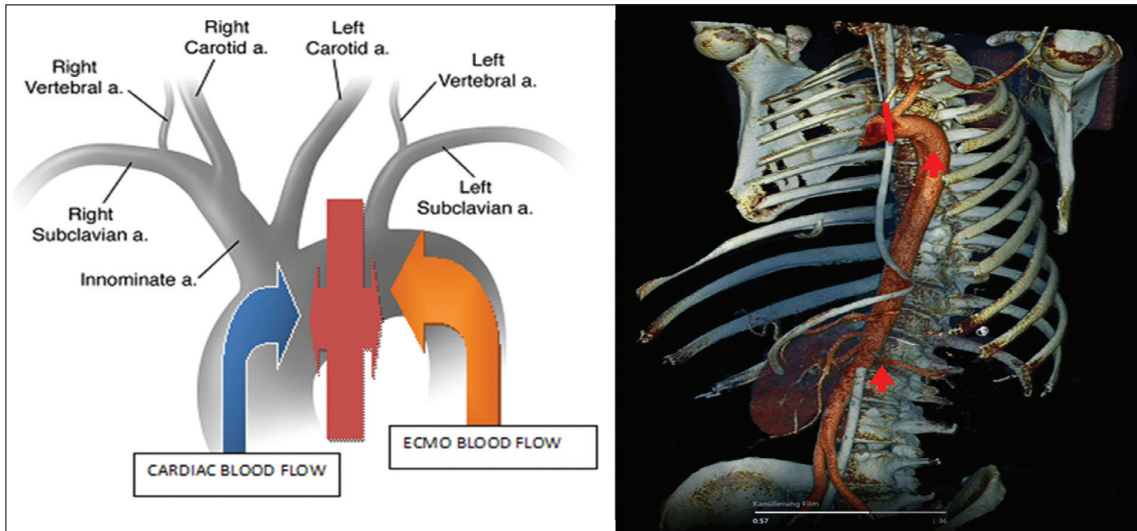


Figure 10 - Harlequin syndrome.



Figure 11 - Fracture of a double-lumen venous cannula (Avalon®)

REFERENCES

1. Tramm R, Ilic D, Davies A R, Pellegrino V A, Romero L, Hodgson C. Extracorporeal membrane oxygenation for critically ill adults. *Cochrane Database Syst Rev.* 2015; 1: CD010381.
2. Schmid C, Philipp A, Mueller T, Hilker M. Extracorporeal life support - systems, indications, and limitations. *Thorac Cardiovasc Surg.* 2009; 57: 449-454.
3. Arlt M, Philipp A, Zimmermann M, Voelkel S, Amann M, Bein T, et al. Emergency use of extracorporeal membrane oxygenation in cardiopulmonary failure. *Artif Organs.* 2009; 33: 696-703.
4. Philipp A, Arlt M, Amann M, Lunz D, Muller T, Hilker M, et al. First experience with the ultra compact mobile extracorporeal membrane oxygenation system Cardiohelp in interhospital transport. *Interact Cardiovasc Thorac Surg.* 2011; 12: 978-81.
5. Ganslmeier P, Philipp A, Rupprecht L, Diez C, Arlt M, Mueller T, et al. Percutaneous cannulation for extracorporeal life support. *Thorac Cardiovasc Surg.* 2011; 59: 103-7.
6. Conrad S A, Grier L R, Scott L K, Green R, Jordan M. Percutaneous cannulation for extracorporeal membrane oxygenation by intensivists: a retrospective single-institution case series. *Crit Care Med.* 2015; 43: 1010-5.
7. Benassi F, Vezzani A, Vignali L, Gherli T. Ultrasound guided femoral cannulation and percutaneous perfusion of the distal limb for VA ECMO. *J Card Surg.* 2014; 29: 427-9.
8. Takayama H, Landes E, Truby L, Fujita K, Kirtane A J, Mongero L, et al. Feasibility of smaller arterial cannulas in venoarterial extracorporeal membrane oxygenation. *J Thorac Cardiovasc Surg.* 2015.
9. Steffen R J, Sale S, Anandamurthy B, Cruz V B, Grady P M, Soltesz E G, et al. Using near-infrared spectroscopy to monitor lower extremities in patients on venoarterial extracorporeal membrane oxygenation. *Ann Thorac Surg.* 2014; 98: 1853-4.
10. Avalli L, Sangalli F, Migliari M, Maggioni E, Gallieri S, Segramora V, et al. Early vascular complications after percutaneous cannulation for Extracorporeal Membrane Oxygenation for cardiac assist. *Minerva Anestesiol.* 2015.
11. Gass A, Palaniswamy C, Aronow W S, Kolte D, Khera S, Ahmad H, et al. Peripheral venoarterial extracorporeal membrane oxygenation in combination with intra-aortic balloon counterpulsation in patients with cardiovascular compromise. *Cardiology.* 2014; 129: 137-43.
12. Abrams D, Combes A, Brodie D. Extracorporeal membrane oxygenation in cardiopulmonary disease in adults. *J Am Coll Cardiol.* 2014; 63: 2769-78.

Conflict of interest: Rupprecht L, Lunz D, Philipp A, Lubnow M, Schmid C. Pitfalls in percutaneous ECMO cannulation. *Heart, Lung and Vessels.* 2015; 7(4): 320-326.

Source of Support: Nil. **Disclosures:** None declared.

