

## Delineating Injectable Triamcinolone-Induced Cutaneous Atrophy and Therapeutic Options in 24 Patients—A Retrospective Study

### Abstract

**Background:** Steroids being the strongest anti-inflammatory agents are used in innumerable disorders in various formulations with excellent results and seemingly known side effects as well. Triamcinolone acetonide used as intralesional injections is seen to be associated with localized atrophy in some patients. **Aim:** To describe the cases of steroid-induced localized atrophy/lipoatrophy after intralesional triamcinolone over various parts of the body in a retrospective study. **Materials and Methods:** All patients, with localized atrophy/lipoatrophy with a history of intralesional triamcinolone, were evaluated clinically and histopathologically over the last 3 years. Patients with localized atrophy/lipoatrophy without a history of intralesional steroids were excluded from the study. Patients were evaluated for number, duration, sites, size, shape, and morphology of lesions and response to treatment. **Results:** There were 24 patients (13 females and 11 males) who had intralesional steroid-induced atrophy/lipoatrophy. All but one patient (4-year-old male child) were adults. Buttock (50%) was the most common site involved followed by wrist (25%), scalp (16.6%), malleolus, and neck (4.1%) each. The most common presentation was asymptomatic depigmented atrophic single oval or ameboid plaque with radial extensions. Histopathology was done in 10 patients showing diminished subcutaneous fat lobules with minimal inflammatory cells. Sixteen patients (66.6%) improved with medications (tacrolimus, platelet-rich plasma, and saline injections), and seven were lost to follow-up. **Conclusion:** Corticosteroids act as a double-edged sword so should be used cautiously. Depigmentation/atrophy is a peculiar side effect of intralesional triamcinolone. Depigmented lesions with minimal clinical atrophy respond well to topical tacrolimus, while normal saline injections appear to have promising results in steroid-induced lipoatrophy.

**Keywords:** Depigmented plaque, normal saline, steroid-induced lipoatrophy, triamcinolone

### Introduction

Triamcinolone acetonide is the most commonly administered intralesional corticosteroid by dermatologists as well as by untrained physicians for unsolicited indications, especially in India. Inadvertent high concentration, amount, wrong site, multiple doses, and co-administration with other agents can lead to localized or systemic side effects of these preparations. Any steroid preparation can lead to cutaneous changes, although preparation like triamcinolone having lesser water solubility is often associated with localized lipoatrophy.<sup>[1,2]</sup> In this retrospective study, we are describing the cases of triamcinolone-induced lipoatrophy in 24 patients during 3 years.

### Materials and Methods

We retrieved the records of triamcinolone-induced atrophy/lipoatrophy

This is an open access journal, and articles are distributed under the terms of the Creative Commons Attribution-NonCommercial-ShareAlike 4.0 License, which allows others to remix, tweak, and build upon the work non-commercially, as long as appropriate credit is given and the new creations are licensed under the identical terms.

For reprints contact: WKHLRPMedknow\_reprints@wolterskluwer.com

from the department of dermatology over 3 years (January 2018–January 2021). We evaluated retrospectively all the patients with depressed plaques for demographic profile, number of lesions, duration, size, shape, and morphological features as well as response to treatment. All those with a history of injections other than steroids or having personal or family history of vitiligo or collagen vascular disease were excluded. Histopathology records were found in 10 patients only where other causes of lipoatrophy were also suspected, while few patients had refused for it and were avoided in others for cosmetic reasons after probing the history and clear evident diagnosis. Treatment was given to all patients due to apprehension about the condition and few were having a misconception of vitiligo. Patients without clinically evident or minimal lipoatrophy were given tacrolimus

**How to cite this article:** Sharma RK, Gupta M, Rani R. Delineating injectable triamcinolone-induced cutaneous atrophy and therapeutic options in 24 patients—A retrospective study. *Indian Dermatol Online J* 2022;13:199-206.

**Received:** 25-Jul-2021. **Revised:** 15-Sep-2021.

**Accepted:** 17-Sep-2021. **Published:** 03-Mar-2022.

**Reena K. Sharma,  
Mudita Gupta<sup>1</sup>,  
Ritu Rani**

*Dermatologist, Civil Hospital,  
Kangra, Himachal Pradesh,  
India, <sup>1</sup>Department of  
Dermatology, Venereology  
and Leprosy, IGMC, Shimla,  
Himachal Pradesh, India*

### Address for correspondence:

*Dr. Mudita Gupta,  
Department of Dermatology,  
Venereology and  
Leprosy, IGMC, Shimla,  
Himachal Pradesh, India.  
E-mail: muditadr Gupta@yahoo.  
com*

### Access this article online

**Website:** www.idoj.in

**DOI:** 10.4103/idoj.idoj\_483\_21

### Quick Response Code:



only. Platelet-rich plasma (PRP) was done for scalp lesion with alopecia areata for resolution of lipoatrophy and hair regrowth while all remaining with evident lipoatrophy were given intralesional saline injections. Tacrolimus was given as a local application at bedtime, PRP was done monthly using the double spin method and saline injections were given every fortnightly for 2 months and then monthly for 6 months. Treatment modality was changed if no response occurred at 3 months.

## Results

There were 24 total patients [Table 1] with localized atrophy/lipoatrophy secondary to intralesional triamcinolone. Females (13,54.16%) outnumbered males (11,45.83%). The average age of presentation was 27.8 years ranging from 4 to 45 years. The minimum duration of the presentation was 2 weeks (range 2 weeks–3 months, average- 4.75 weeks). An average latency period of development of lesions after steroid injection was 4–8 weeks. Dermatological indications for triamcinolone injection were alopecia areata (16.6%) and keloid (4.1%). Nondermatological (orthopedic) indications were accounted for 16.6% of ganglions cases while the remaining (62.5%) were inadvertent use by unqualified private practitioners for generalized pruritus (allergic dermatitis, scabies, urticaria, and atopic dermatitis), pain in wrist and ankle joint, generalized weakness, and generalized body aches. Triamcinolone injections as per history obtained from patients ranged from 1 to 3 in numbers. None of the patients noticed any sign of erythema, erosions, ulceration, or thickening prior to the development of the lesion. All patients had self-limited nature of lipoatrophy without further progress after a certain stage and were asymptomatic at the time of presentation. Family history was not contributory in any of the patients. Buttock (50%) was the most common site involved followed by wrist (25%), scalp (16.6%), malleolus, and neck (4.1%) each. Morphology of lesion was same in all patients with atrophic depigmented plaque arranged in various shapes like ameboid, oval, circular, square shapes with radiating lines in some and linear, or comet-shaped with trailing end in others. All but one patient had a single lesion irrespective of the number of injections. Maximum/minimum size of the atrophic lesion was 20 × 0.5cm (linear)/1.5cm radius (circular) with an average size of 5.4 × 2.2 cm [Figure 1a-h].

Histopathology showed normal epidermis, minimal inflammatory infiltrate in a perivascular area in the dermis. In the subcutis, fat lobules were diminished in size and contained atrophic fat lobules with very minimal inflammatory cells [Figure 2].

Eight patients have given tacrolimus 0.1% ointment [Figure 1a and b] at bedtime for local application leading to complete resolution of the depigmented lesion over 2 months in two patients, over 3 months in other four patients, while two lost to follow-up. Four patients

with alopecia areata developing atrophy were treated with PRP [Figure 1c and d], three improved completely, and one did not return, while the remaining twelve patients were given intralesional saline injection [Figure 1e–h], out of which seven improved, three lost to follow-up, one did not show any improvement at 1 month and lost to follow-up thereafter while one did not show any response at 3 months of treatment and was advised autologous fat transfer.

## Discussion

Steroids, the magic bullets having the strongest anti-inflammatory effects, are used in myriads of indications ranging from their role as a topical application in minor skin disorders to systemic administration in severe life-threatening autoimmune and inflammatory conditions with excellent results. However, corticosteroids act as a double-edged sword if not used in the right concentration, dosage, duration, and formulation leading to various adverse effects ranging from local cutaneous changes to Cushing syndrome. Intralesional corticosteroids are indicated in all those conditions where topical ones are not effective and systemic can lead to adverse effects. However, intralesional steroids can also lead to local reactions like erythema, telangiectasias, alopecia, secondary infection, hypersensitivity reactions, panniculitis, hypopigmentation, and atrophy. Goldman reported these reactions in less than 0.5% of cases.<sup>[3,4]</sup> Atrophogenic potential of intralesional steroids does not only depend on the corticosteroid used but also hinges on the potency, volume, vehicle, and diluents. Common injectable steroids are triamcinolone, methylprednisolone, betamethasone, and dexamethasone. Betamethasone and dexamethasone are more soluble preparations, so taken up more rapidly by the cells, hence have a fast onset of action as compared to triamcinolone and methylprednisolone. Ester compounds in triamcinolone and methylprednisolone make them highly insoluble in water leading to form microcrystals as they require hydrolysis by cellular esterases to release the active moiety and hence the longer duration of action.<sup>[5]</sup> The solubility of the corticosteroids is inversely related to the duration of effect, with triamcinolone acetonide being the least soluble injectable steroid preparation and having along-lasting effect. But at the same time, dexamethasone and betamethasone are five times as potent as triamcinolone and methylprednisolone.<sup>[5]</sup> [Table 2] Methylprednisolone contains 3% polyethylene glycol and 0.9% benzyl alcohol, whereas triamcinolone acetonide contains benzyl alcohol only. Polyethyl alcohol has been found to be associated with neurotoxicity, while there are reports of flaccid paralysis with benzyl alcohol by epidural injection but not with intracutaneous.<sup>[6]</sup> Dexamethasone contains methylparaben and sodium bisulfite compounds that have been implicated in allergic reactions.<sup>[6]</sup>

If soft tissue atrophy and skin hypopigmentation are a significant concern, dexamethasone and a soluble

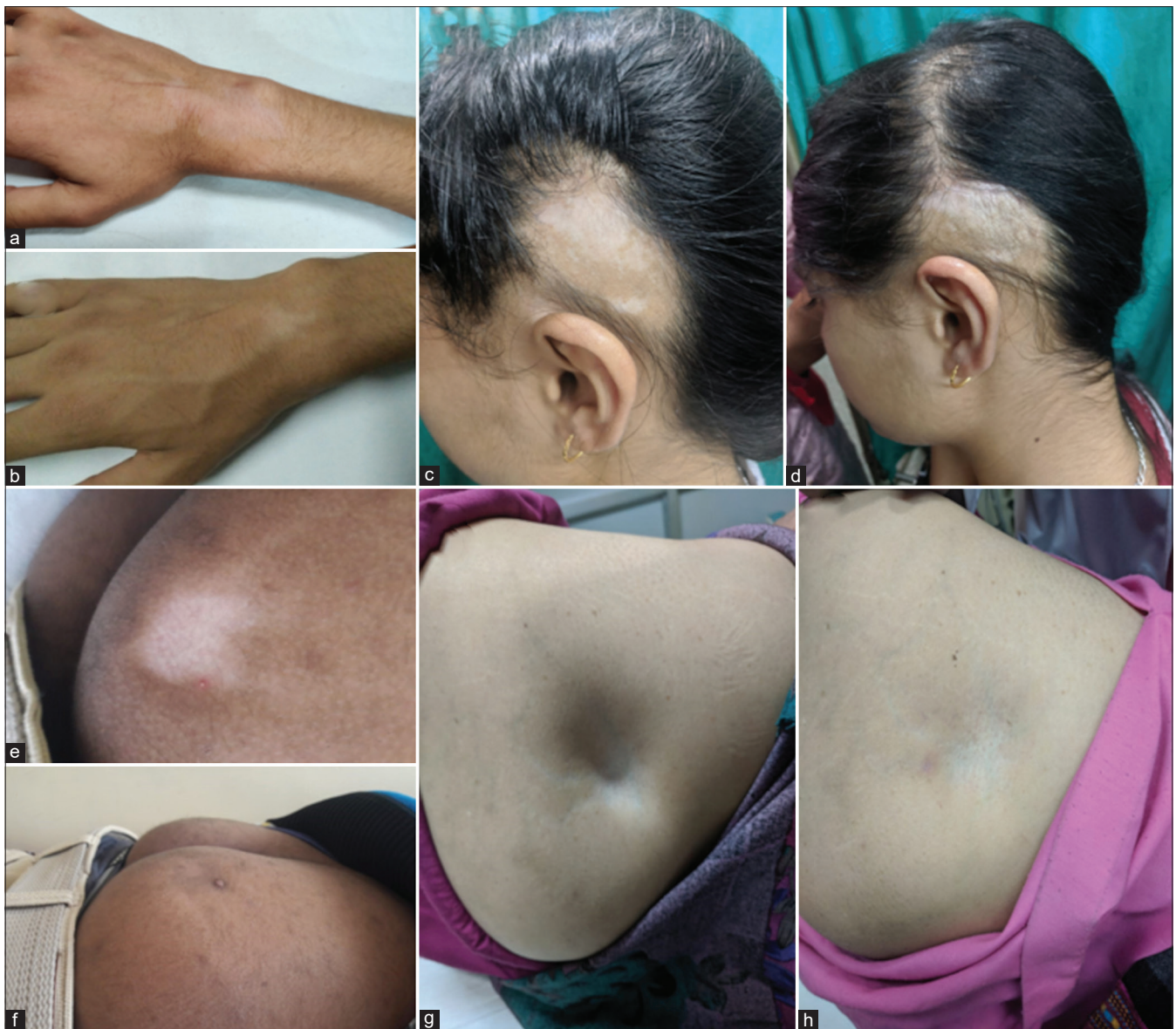**Table 1: Demographic profile and clinicomorphologic pattern of 24 patients with steroid-induced atrophy**

Age	Sex	Site	Duration of the lesion (weeks)	The interval between injection and lesion (weeks)	Clinical Morphology	Treatment given
20	M	Right buttock	4	6-8	Single well defined depigmented atrophic plaque of size about 4×3 cm, oval in shape with radial projections	Saline injection
32	F	Left wrist	3	3-6	Single well to ill-defined, comet-shaped atrophic plaque of size about 15 cm length and 5 cm width at the distal end and 0.5 cm at the proximal end	Tacrolimus
19	F	Scalp	4	4-6	Well-defined atrophic depigmented plaque of size about 3.5×3 cm, oval in shape	Platelet-rich plasma (PRP)
32	F	Left buttock	6	3-6	Single well-defined erythematous to a pigmented comet-shaped atrophic plaque of size about 2.5×2 cm at one end with 2×1 cm trailing end	Saline injection
28	F	Left wrist	4	4-6	Single, ill-defined, depigmented plaque without clinically evident atrophy of size 3.5×2.5 cm	Tacrolimus
42	F	Right Buttock	6	4-8	Ill-defined depigmented atrophic plaque of size about 4×3.5 cm, irregular borders	Saline injection
38	F	Right lateral ankle	3	3-4	Well- to ill-defined depigmented plaque having minimal atrophy of size about 4×3.5 cm, rectangular shaped with a linear streak of size about 10 cm along the feeding vein	Tacrolimus
25	M	Left buttock	8	6-8	Single ill-defined oval-shaped depigmented atrophic plaque of size about 3.5×2 cm with perilesional hypertrichosis	Saline
28	F	Left wrist	3	3-4	Ill-defined, mildly atrophic, ameboid shaped, depigmented plaque of size about 8×3 cm	Tacrolimus
22	F	Right buttock	3	6-8	Well-defined atrophic depigmented plaque, circular in shape of size about 1.5 cm radius	Saline
4	M Ch	Right buttock	4	4-6	Ill- to well-defined atrophic depigmented plaque, ameboid in shape of size about 5×3.5 cm with radial projections	Saline
18	F	Left side of scalp	4	4-8	Ill-defined triangular-shaped depigmented atrophic patch without clinically evident atrophy of size about 4×3 cm	PRP
26	M	Left buttock	8	8-12	Well- to ill-defined depigmented atrophic plaque, comma-shaped of size about 3.5×3 cm proximal end and 15×1 cm tail	Saline
30	M	Left wrist	2	4-6	Well- to ill-defined depigmented mildly atrophic plaque, comet-shaped of size about 3×2.5 cm distal end and 20×0.5 cm trail along the feeding vein	Tacrolimus
25	F	Left buttock	4	6-12	Single well-defined oval-shaped depigmented plaque with hyperpigmented borders with minimal atrophy, of size about 2×1.5 cm	Saline injection
32	M	Left parietal scalp	3	4-6	Ill-defined skin-coloured to depigmented patch of size about 2.5×1.5 cm without clinically evident atrophy	PRP
45	F	Right buttock	12	4-12	Single depigmented circular-shaped atrophic plaque of size about 2 cm in radius	Saline
30	M	Right Wrist	3	3-4	Ill-defined ameboid-shaped depigmented patch without clinically evident atrophy of size about 6×2.5 cm	Tacrolimus
42	F	Left side of the neck	3	4-12	Ill-defined ameboid-shaped depigmented plaque of size about 6×4 cm, with partially atrophied keloid at the center	Tacrolimus

Contd...

**Table 1: Contd...**

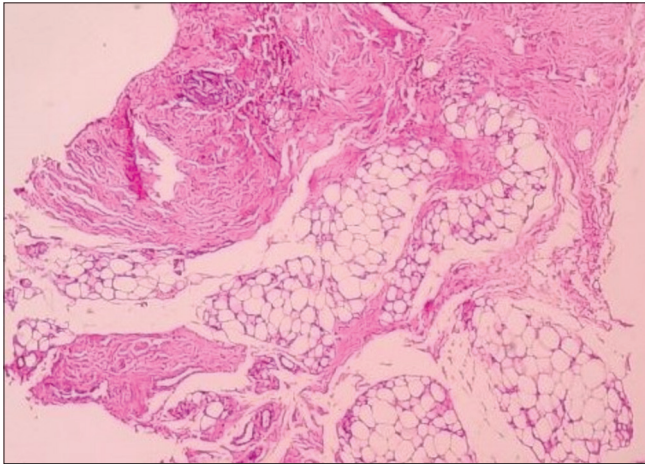
Age	Sex	Site	Duration of the lesion (weeks)	The interval between injection and lesion (weeks)	Clinical Morphology	Treatment given
21	M	Right buttock	8	4-12	Well to ill-defined scaly erythematous, atrophic plaques 2 in number, oval in shape, of size about 1.5×1 cm proximal and 3×1.5 cm distal	Saline
35	F	Left Buttock	4	4-6	Single atrophic depigmented plaque of size about 2.5×1.5 cm with radiating lines along the veins	Saline
22	M	Right Buttock	8	4-8	Well-defined square-shaped, depigmented atrophic plaque of size about 2×2 cm with surrounding scattered hypopigmentation	Saline
35	M	Left parietal scalp	4	4-8	Ill-defined skin-coloured to erythematous atrophic plaque of size about 3.5×2.5 cm	PRP
17	M	Right wrist	3	3-6	Well-defined depigmented plaque, ameboid-shaped, of size about 7×5 cm	Tacrolimus



**Figure 1:** (a) Depigmentation without evident atrophy over the wrist (b) Decrease in pigmentation after 4 weeks of tacrolimus (c) Depigmentation and atrophy in alopecia areata patch after triamcinolone (d) Hair regrowth after 4 weeks of single platelet-rich plasma injection (e and g) Single atrophic plaque over buttock with radial striations (f and h) Improvement in atrophy and depigmentation after 4 weeks—two injections of saline given fortnightly

**Table 2: Comparison of the different steroids in terms of glucocorticoid potencies, component vehicle, and preservatives**

Steroid	Relative Potency	Vehicle (polyethylene glycol)	Preservative		
			Benzyl alcohol	Methyl paraben	Sodium bisulfite
Methylprednisolone	5	+	+	-	-
Triamcinolone	5	-	+	-	-
Betamethasone	1	-	-	-	-
Dexamethasone	1	-	-	+	+

**Figure 2: Decreased size and number of adipocytes with mild inflammatory infiltrate in subcutaneous tissue**

betamethasone preparation appear to be more favorable; however, systemic absorption and hence side effects will be more, nullifying the purpose of local injection. Zaynoun and Salti<sup>[7]</sup> in 1973 studied the effect of intradermal glucocorticoids on plasma cortisol levels and concluded that glucocorticoid preparations designed for intradermal use should be composed of slowly released glucocorticoid components, such as triamcinolone acetonide, as more rapidly released products, such as betamethasone acetate, result in greater adrenal suppression. So, deciphering the puzzle, the choice of steroid preparation suitable for intralesional injection is long-acting triamcinolone. Type of steroid is not the only factor influencing atrophy and hypopigmentation but steroid equivalence (potency) of the various preparations determining the injection volume, the concentration of preparation, vehicle, preservative, depth of injection, frequency, site, needle size, and technique of injection are also in the long list. As triamcinolone is the most frequently used preparation for intralesional injections, chances of soft tissue injury with the preparation cannot be negated completely; however, studies have proven, if used judiciously, no detrimental soft tissue effects are seen with triamcinolone.<sup>[4]</sup>

Intralesional use of steroids was first started by Hollander (in 1953) when he found intra-articular hydrocortisone effective for rheumatic conditions. Later, in 1958, Hollander and various other authors used triamcinolone concluding that it had better therapeutic effects than other corticosteroids.<sup>[8,9]</sup>

Triamcinolone is mildly potent fluorinated prednisolone exhibiting both anti-inflammatory and immunosuppressant activity. Triamcinolone acetonide is used as a topical preparation (cream, ointment, and orabase) or injectable (intralesional, intra-articular, and intramuscular) in various cutaneous and noncutaneous (ophthalmic, rheumatologic, and orthopedic) indications. Injection triamcinolone is available as an aqueous suspension (of benzyl alcohol, sodium chloride, sodium carboxymethylcellulose, and polysorbate 80)<sup>[10]</sup> in concentrations of 10 mg/mL and 40 mg/mL. It can be conveniently diluted with normal saline to 2.5 mg/mL concentration; however, some prefer dilution with 1% lignocaine.

Triamcinolone injection should be given meticulously to reduce the rate of adverse reactions taking the following precautions.

Minimum effective concentration should be used depending upon the type of lesion. A small/moderate gauge needle (26–30) should be preferred as targeting the affected tissue precisely with a very small-sized needle is difficult and there are chances of leakage of steroid preparation into surrounding tissues with large sized needle thus increasing the chances of atrophy, as in normal skin, the crystals can remain longer than in pathologic skin.<sup>[3,4]</sup> Chances of skin atrophy are more in areas where the skin is thin and naturally occluded. The injection should be given with the patient lying on the table to minimize a possible syncopal episode. Depth of injection is also important as subcutaneous injections have more chances of lipoatrophy.<sup>[2]</sup> Aspiration before the injection is necessary as the intra-arterial injection can lead to embolization.<sup>[3,11]</sup> Triamcinolone acetonide has a longer shelf life, and refrigeration is not required.<sup>[9]</sup> Triamcinolone acetonide is a suspension, so it is essential to shake the bottle vigorously at every stage and before every use. The volume of solution injected influences the accuracy of steroid delivery as a small amount of solution (1 mL) will be able to be delivered more precisely than the same dose of corticosteroid diluted in 5 to 10 mL of solution.<sup>[4]</sup> Triamcinolone should be diluted in the saline vial rather than in the syringe to make a more consistent percentage steroid solution. Some authors also recommend dilution with 1% lignocaine; however, studies have shown that a mixture of triamcinolone and lignocaine should be injected

immediately as the size of particles of triamcinolone increases after 1 hour of mixing.<sup>[6,9,11,12]</sup>

Soft-tissue atrophy after intralesional injection is a peculiar side effect with an estimated incidence of 0.5–40%,<sup>[13,14]</sup> while skin hypopigmentation has been reported in 1.3–6% of cases.<sup>[13]</sup> The lipoatrophy which results due to triamcinolone has been explained by various hypotheses. Corticosteroids lead to vasoconstriction, triamcinolone, in addition, leads to crystal formation; these crystals in vasoconstricted vessels lead to tissue hypoxia, decreased glycosaminoglycans, collagen synthesis, and involution of subcutaneous fat lobules.<sup>[15]</sup> Steroid-induced inhibition of prostaglandin/cytokine production in the epidermal cells is hypothesized to cause melanocytes function suppression as proposed by Fangman that it is not the decreased number of melanocytes but impaired function, which is responsible for hypo/depigmentation.<sup>[16]</sup> Atrophy generally begins within 1 to 3 months of injection, our patients also had an average latency period of 4–8 weeks.<sup>[1]</sup> There may be a spontaneous resolution of atrophy within 1 to 2 years corresponding to the gradual disappearance of crystals.<sup>[1,3]</sup> However, atrophy persisting beyond 5 years has been reported and occasionally it can be permanent.<sup>[17]</sup> The longest duration of presentation in our patient was 3 months. We treated all our patients without waiting for spontaneous regression considering the apprehension and fear of mimickers. As discussed above, the extent and time course of cutaneous atrophy depend on the solubility and concentration of the steroid preparation as compounds with low solubility, such as triamcinolone acetonide, injected at higher concentrations are associated with greater atrophogenic potential. Pariser and Murray<sup>[1]</sup> noted a greater risk of cutaneous atrophy with concentrations above 5 mg/mL of triamcinolone acetonide. Cutaneous atrophy also reflects the depth and anatomic location of the injection given. Injections into the superficial dermis can result in epidermal atrophy, whereas those in the deep dermis and subcutis may result in lipoatrophy with minimal epidermal change.<sup>[1]</sup> Buttock is the most common site involved in our patients followed by wrist, similar to what has been noticed by Margulies *et al.*<sup>[15]</sup> The female gender is more commonly involved though the reason for this is not clear, females outnumbered males in the present study also.<sup>[4]</sup> Skin atrophy can localize to the area of injection or progress in a linear fashion, along lymphatic channels or superficial veins. Six of our patients presented with linear streaks while nine had radial striations. Linear streaks were usually present over distal extremities where veins and lymphatics were superficial and radial striations were more common over the gluteal regions. Linear extension of the lesions is explained by uptake of steroid crystals by lymphatics as local lymphatic vessels are responsible for removing the macromolecules and proteins. The steroid crystals cause localized lipolysis and depigmentation along the lymphatics.<sup>[16]</sup>

Histopathologically, there is epidermal and dermal atrophy, flattening of rete ridges, homogenization of collagen, degeneration of sebaceous glands, and decreased elastin. Steroid crystals can be seen on polarized microscopy.<sup>[1]</sup> Adipocytes decrease in size and number after the steroid injection and resemble embryonic fat cells because of the prominence of vessels, termed involutinal adipocytes. Macrophages engulf adipose tissue and become lipophages.<sup>[4,15]</sup>

The closest differential in these patients was idiopathic localized involutinal lipoatrophy (ILIL), which was excluded by history and clinical examination [Table 3]. All patients diagnosed with ILIL should be thoroughly interrogated for the history of injections, as few of our patients who were denying the history of injections later confessed on further probing or asking records, to have had it from the private practitioners for minor ailments. In addition to steroids, other injections like insulin (nonhuman), antibiotics (amikacin and benzathine penicillin), methotrexate, bleomycin, iron, heparin, vaccines, growth factors, and glatiramer can also cause lipoatrophy but excluded from the study.<sup>[18]</sup> Depigmentation after steroid injections can mimic vitiligo; however, atrophy with depigmentation rules out vitiligo.

Treatment options recommended for steroid-induced atrophy are fillers like autologous fat injection, poly-L-lactic acid, calcium hydroxyapatite, etc., However, these modalities of treatment are expensive and need expertise. We customized treatment in our patients depending upon atrophy. Of our eight patients with minimal or no clinically evident atrophy started on tacrolimus, six recovered completely in 3 months while two never returned. Tacrolimus was also used by Ghunawat *et al.*<sup>[16]</sup> in triamcinolone-induced linear atrophy showing repigmentation in 20 days while atrophy persisted. In 2005, Shumaker *et al.*<sup>[1]</sup> treated corticosteroid-induced atrophy with normal saline infiltration. After this, various authors have used normal saline in the treatment of triamcinolone-induced lipoatrophy.<sup>[19,20]</sup> Normal saline leads to resuspension of crystals which are then engulfed by macrophages and cleared by the natural defense of the body.<sup>[20]</sup> Shumaker *et al.*<sup>[1]</sup> used a weekly regime, had faster improvement as compared to, Margulies *et al.*<sup>[15]</sup> who used a monthly regime, Tiwary *et al.*<sup>[20]</sup> and Sadati *et al.*<sup>[21]</sup> a fortnightly. The amount of saline used was also different in all cases. In our patients, saline was injected at a fortnightly interval and the amount was decided by blanching and tumescence effect due to distension. Most of the patients improved with this modality while few lost to follow-up. Four patients of alopecia areata with atrophy were injected with PRP which worked on the principle of normal saline injection.

## Conclusion

Though triamcinolone comparatively having the least solubility has more chances of atrophy, but considering

**Table 3: Difference between idiopathic localized involutinal lipoatrophy and steroid-induced atrophy**

<b>Idiopathic Localised Involutinal Lipoatrophy (ILIL)</b>	<b>Steroid-Induced Atrophy/Lipoatrophy</b>
Spontaneous development of lipoatrophy without a history of steroid or any other injection	History of steroid injection present
More common in children and females	Any age/sex can be involved
Buttocks (the most common reported site), also seen in arms and thighs	Any injection site can be involved. Buttock, extremities, face, and scalp are commonly involved
May be unilateral or bilateral	Usually unilateral
Number of lesions usually single or few	Usually single
No linear striations along lymphatics or veins	Linear striations along lymphatics or veins usually present
Usually oval or round in shape	May present as linear, ameboid, comet-, or round shaped
Presents as depigmented depressed plaque	Presents as a depigmented plaque with or without clinically evident lipoatrophy
Histopathologically absent or sparse perivascular lymphohistiocytic infiltrate, mild-to-moderate hyalinization and diminished fat lobules lymphohistiocytic infiltrate, mild-to-moderate hyalinization, and diminished fat lobules	Indistinguishable from ILIL except for the presence of corticosteroid crystals, better identified on polarised microscopy
Spontaneous resolution present	May or may not resolve spontaneously

systemic absorption, is the steroid of choice for intralesional injection. So it is prudent to use precise dilution, amount, and injection technique to avoid the cosmetic defect, as maximum cases of steroid-induced atrophy/lipoatrophy are reported in nondermatological and inadvertent use. Buttock is the commonest site involved followed by extremities. Cases with minimal clinical atrophy responded well to tacrolimus, hair regrowth occurred as well as atrophy improved following PRP in alopecia areata cases while saline injection proved a promising option for triamcinolone-induced lipoatrophy.

### **Declaration of patient consent**

The authors certify that they have obtained all appropriate patient consent forms. In the form, the patient(s) has/have given his/her/their consent for his/her/their images and other clinical information to be reported in the journal. The patients understand that their names and initials will not be published and due efforts will be made to conceal their identity, but anonymity cannot be guaranteed.

### **Financial support and sponsorship**

Nil.

### **Conflicts of interest**

There are no conflicts of interest.

### **References**

- Shumaker PR, Rao J, Goldman MP. Treatment of local, persistent cutaneous atrophy following corticosteroid injection with normal saline infiltration. *Dermatol Surg* 2005;31:1340-3.
- Lambro G, Lagrata S, Matharu MS. Cutaneous atrophy and alopecia after greater occipital nerve injection using triamcinolone. *Headache* 2012;52:1596-9.
- Goldman L. Reactions following intralesional and sublesional injections of corticosteroids. *JAMA* 1962;182:613-6.
- Pace CS, Blanchet NP, Isaacs JE. Soft tissue atrophy related to corticosteroid injection: Review of the literature and implications for hand surgeons. *J Hand Surg Am* 2018;43:558-63.
- MacMahon PJ, Eustace SJ, Kavanaugh EC. Injectable corticosteroid and local anesthetic preparations: A review for radiologists. *Radiol* 2009;252:647-61.
- Benzon HT, Chew TL, McCarthy RJ, Benzon HA, Walega DR. Comparison of the particle sizes of different steroids and the effect of dilution: A review of the relative neurotoxicities of the steroids. *Anesthesiol* 2007;106:331-8.
- Zaynoun ST, Salti IS. The effects of intracutaneous glucocorticoids on plasma cortisol levels. *Br J Dermatol* 1973;88:151-6.
- Hollander A. Intralesional injection of triamcinolone acetonide: Therapy for dermatoses. *Antibiotic Med Clin Ther (New York)* 1961;8:78-83.
- Richards RN. Update on intralesional steroid: Focus on dermatoses. *J Cutan Med Surg* 2010;14:19-23.
- Sexton GB. Local injection of triamcinolone acetonide in the management of certain skin conditions: Preliminary report. *Can Med Assoc J* 1960;83:1379-81.
- Francis BA, Chang EL, Haik BG. Particle size and drug interactions of injectable corticosteroids used in ophthalmic practice. *Ophthalmol* 1996;103:1884-8.
- Wahezi SE, Mohamed SE, Lederman A, Beck AP. Aggregation properties of triamcinolone acetonide injection in human serum: Considerations when performing epidural steroid injections. *J Pain Res* 2019;12:1033-9.
- Martins N, Polido-Peeira J, Caneira M, Fonseca JE. Treatment of persistent cutaneous atrophy after corticosteroid injection with fat graft. *Reumatol Clin* 2019;15:122-4.
- Kim I, Lee HL, Lee SS. Two cases of lipoatrophy after local corticosteroid injection. *Korean J Clin Neurophysiol* 2015;17:91-4.
- Margulies SL, Morris A. Successful treatment of lipoatrophy with normal saline. *JAAD Case Rep* 2015;1:415-7.
- Ghunawat S, Sarkar R. Steroid-induced perilymphatic hypopigmentation: Response to tacrolimus. *Pigment Int* 2018;5:114-6.
- Lund IM, Donde R, Knudsen EA. Persistent local cutaneous atrophy following corticosteroid injection for tendinitis. *Rheumatol Rehabil* 1979;18:91-3.
- Sharma RK, Gupta M, Negi L. Idiopathic localized involutinal lipoatrophy: A retrospective study of 12 cases. *Indian Dermatol Online J* 2019;10:149-52.
- Shiffman MA. Letter: Treatment of local, persistent cutaneous

- atrophy after corticosteroid injection with normal saline infiltration. *Dermatol Surg* 2010;36:436.
20. Tiwary PK, Gurudiwan P, Chaudhary RKP. Normal saline used in successful treatment of localised lipoatrophy in children. *Indian J Clin Exp Dermatol* 2016;2:174-6.
21. Sadati MS, Boroujeni NH, Sepaskhah M. Normal saline injection; a promising method to treat steroid induced atrophy. *Iran J Dermatol* 2018;21:20-2.