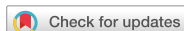

Case Report



Mycobacterium avium Complex Infection-Related Immune Reconstitution Inflammatory Syndrome Mimicking Lymphoma in an Human Immunodeficiency Virus-Infected Patient

Sungmin Sohn ¹, Hye Jin Shi¹, Sung Ho Wang¹, Sang Ki Lee¹, So Yeon Park ¹, Jin Seo Lee ¹, and Joong Sik Eom ²

¹Department of Internal Medicine, Kangdong Sacred Heart Hospital, Hallym University Medical College, Seoul, Korea

²Division of Infectious Diseases, Department of Internal Medicine, Gil Medical Center, Gachon University College of Medicine, Incheon, Korea

OPEN ACCESS

Received: Jul 13, 2017

Accepted: Dec 15, 2017

Corresponding Author:

Joong Sik Eom, MD, PhD

Department of Internal Medicine, Gil Medical Center, Gachon University College of Medicine, ADD 21, Namdong-daero 774 beon-gil, Namdong-gu, Incheon 21565, Korea.

Tel: +82-32-458-2789

Fax: +82-32-460-3630

E-mail: helppl@gachon.ac.kr

Copyright © 2018 by The Korean Society of Infectious Diseases and Korean Society for Chemotherapy

This is an Open Access article distributed under the terms of the Creative Commons Attribution Non-Commercial License (<https://creativecommons.org/licenses/by-nc/4.0/>) which permits unrestricted non-commercial use, distribution, and reproduction in any medium, provided the original work is properly cited.

ORCID iDs

Sungmin Sohn

<https://orcid.org/0000-0003-2402-7585>

So Yeon Park

<https://orcid.org/0000-0002-5318-8305>

Jin Seo Lee

<https://orcid.org/0000-0003-3913-6370>

Joong Sik Eom

<https://orcid.org/0000-0003-2744-1159>

ABSTRACT

In acquired immunodeficiency syndrome (AIDS) patients, immune reconstitution inflammatory syndrome (IRIS) due to *Mycobacterium avium complex* (MAC) infection is one of the most difficult IRIS types to manage. We report an unusual case of MAC-associated IRIS. At first the patient was diagnosed human immunodeficiency virus (HIV) infection after he was admitted with pneumocystis pneumonia. After starting antiretroviral therapy he presented unmasked IRIS with MAC infection. Next, he was hospitalized with continuous loose stools and new-onset fever. Investigation included computed tomography (CT), which showed homogeneous enhancement and enlargement of the lymph nodes (LN), elevation of ferritin (>1,650 ng/mL) and lactate dehydrogenase (306 IU/L) levels, and F- fluorodeoxyglucose positron emission tomography/computed tomography (FDG PET/CT) scan, which showed increased FDG uptake. These findings were highly indicative of lymphoma. We performed laparoscopic biopsy of the mesenteric LN, and the biopsy culture grew MAC. So we made a diagnosis of MAC-associated. Therefore, IRIS must be considered as a possible diagnosis when AIDS patients develop new symptoms or exhibit exacerbations of existing symptoms. Furthermore the biopsies should be conducted.

Keywords: Acquired immunodeficiency syndrome; *Mycobacterium avium* complex; Lymphoma

INTRODUCTION

Disseminated *Mycobacterium avium* complex (MAC) infection appears late in the course of human immunodeficiency virus (HIV) disease and is an independent predictor of mortality, even after adjusting for CD4 T cell count [1]. In recent years, the annual rate of disseminated MAC has fallen substantially owing to the availability of highly active antiretroviral therapy (HAART) [2]. However, during the initial months of HAART, immune reconstitution is



Conflict of Interest

No conflicts of interest.

Author Contributions

Investigation: HJS, SHW, SKL. Supervision: SYP, JSL. Writing - original draft: SS. Writing - review & editing: JSE.

complicated by an adverse clinical phenomenon in which either previously subclinical infections are “unmasked” or pre-existing partially treated, opportunistic infections deteriorate. This immune reconstitution inflammatory syndrome (IRIS) has been associated with various medical conditions. Non-tuberculous mycobacterium (NTM)-associated IRIS is one of the most difficult to diagnose and manage. Even with intensive anti-NTM chemotherapy, the prognosis is often poor due to the absence of a standard treatment [3]. The diagnosis of IRIS is often challenging because its clinical presentation is nonspecific and is complicated by opportunistic infections, drug failure, toxicity, and malignancies. The most common IRIS-associated symptoms of fever, lymphadenopathy, and pulmonary symptoms [3], resemble those seen in patients with acquired immunodeficiency syndrome (AIDS)-related lymphoma (ARL) [4]. In addition, the recently reported high ARL rates shortly after initiation of the newer-class of antiretrovirals [5], makes the distinction between ARL and IRIS important.

We present the case of a patient who following anti-NTM chemotherapy and HAART, exhibited symptoms resembling ARL that were diagnosed as IRIS.

CASE REPORT

A 43-year-old man visited the emergency department owing to 3 days of dyspnea and had a history of tuberculosis (TB) in his 20s. A chest computed tomography (CT) at this time showed diffuse ill-defined ground glass opacities in both lung. A pneumocystis pneumonia (PCP) polymerase chain reaction (PCR) test on the bronchoalveolar lavage fluid returned positive result. Moreover respiratory virus multiplex PCR, acid-fast bacilli (AFB) stain, TB PCR, gram stain, and culture returned negative results, we confirmed our diagnosed of PCP. He was treated PCP with trimethoprim (15 mg/kg), sulfamethoxazole (75 mg/kg) combination (TMP-SMX) in addition to prednisolone (PD; 80 mg/day). His CD4 T cell count was 31 cells/μL, an HIV antibody revealed positive and an HIV PCR was a viral load of 47,800 copies/mL. After 9 days of admission, he was discharged.

Twenty-one days after his first visit, an HIV western blot test returned positive results, and we started HAART with tenofovir disoproxil (245 mg/day), emtricitabine (200 mg/day), elvitegravir (150 mg/day), and cobicistat (150 mg/day). However, he has stopped taking the medications after 7 days due to diarrhea. Thirty days after his first visit, we restart HAART with emtricitabine (200 mg/day), tenofovir disoproxil (300 mg/day) and raltegravir (800 mg/day). His CD4 T cell count had increased to 60 cells/μL, and the HIV viral load had decreased to 3,690 copies/mL (Fig. 1).

Sixteen days after starting HAART, he was hospitalized with continuous loose stools and new-onset fever. We suspected a drug side effect, and changed his second-line antiretroviral therapy (ART) to abacavir (600 mg/day), lamivudine (300 mg/day) and raltegravir (800 mg/day). Even though his diarrhea resolved with this change in treatment, his fever persisted (38°C). His white blood cell count was 5,340 cells/mm³, C-reactive protein level was 181 mg/L, and procalcitonin level was 2.08 ng/mL. His chest CT scan demonstrated a decrease in the bilateral ground glass opacities; however, new peribronchial consolidations were seen in both upper lobes. Abdomen/pelvic CT scan exhibited borderline size of paraaortic, aortocaval, retrocaval, and mesenteric lymph nodes (LNs) (Fig. 2). A transthoracic echocardiography did not reveal any evidence of vegetation. For further investigation, bone marrow biopsy was performed. It showed

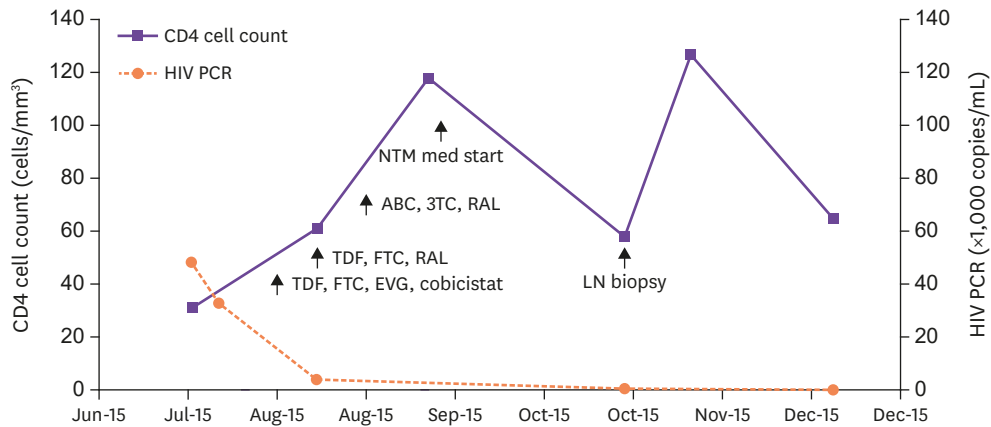


Figure 1. The series of CD4 cell count and HIV RNA PCR level. The arrows indicate the date of important medication or procedure were conducted. HIV, human immunodeficiency virus; RNA, ribonucleic acid; PCR, polymerase chain reaction; NTM, non-tuberculous mycobacterium; ABC, abacavir; 3TC, lamivudine; RAL, raltegravir; TDF, tenofovir disoproxil; FTC, emtricitabine; LN, lymph node; EVG, elvitegravir.

non-caseous necrosis and AFB (**Fig. 3**); however, the TB-PCR test result was negative. In his sputum culture, MAC was cultivated.

Accordingly, the patient was diagnosed with MAC in his sputum and bone marrow, and anti-MAC chemotherapy with rifampicin (450 mg/day), ethambutol (400 mg/day), clarithromycin

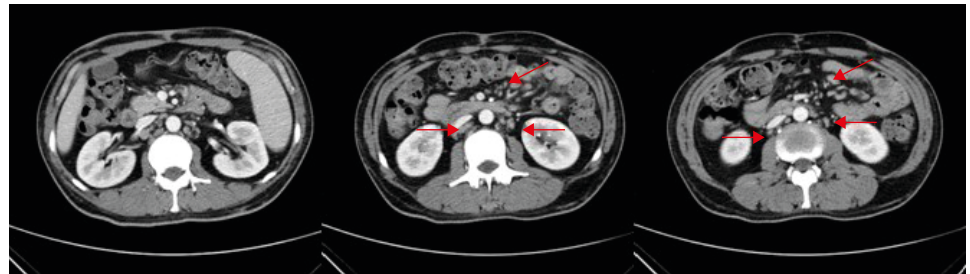


Figure 2. Abdomen/pelvic computed tomography axial plane shows multiple borderline size lymph nodes, paraaortic, aortocaval, retrocaval, and mesentery (red arrows). (Sixteen days after starting HAART). HAART, highly active antiretroviral therapy.

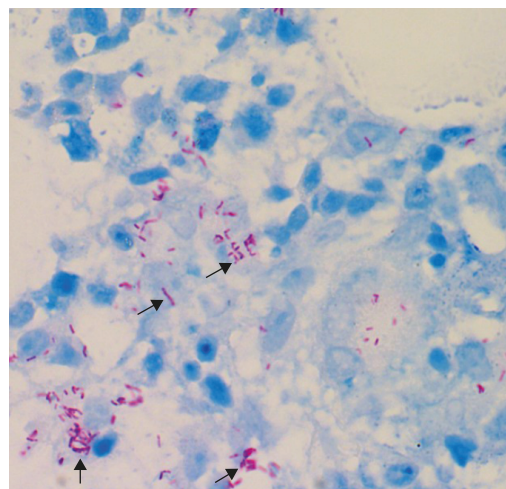


Figure 3. Bone marrow biopsy specimen revealed positive staining for acid fast bacilli. ositive (black arrows). (Ziehl-Neelsen stain, x 400).

(500 mg/day), and levofloxacin (500 mg/day) was started. His fever subsided with anti-MAC chemotherapy and he was discharged 3 days after starting anti-MAC chemotherapy.

Thirty four days of starting anti-MAC chemotherapy, he presented at the outpatient department with abdominal pain. Abdomen/pelvic CT (Fig. 4) showed multiple enlargement mesenteric LNs and hepatosplenomegaly. After a week of abdominal pain and fever (38.3°C), he was readmitted to the hospital. We performed a positron emission tomography (PET)-CT scan (Fig. 5A and 5B) for excluding the possibility of a lymphoma. The scan images showed multiple enlarged hypermetabolic LNs in the mesentery and retroperitoneum of the abdomen,

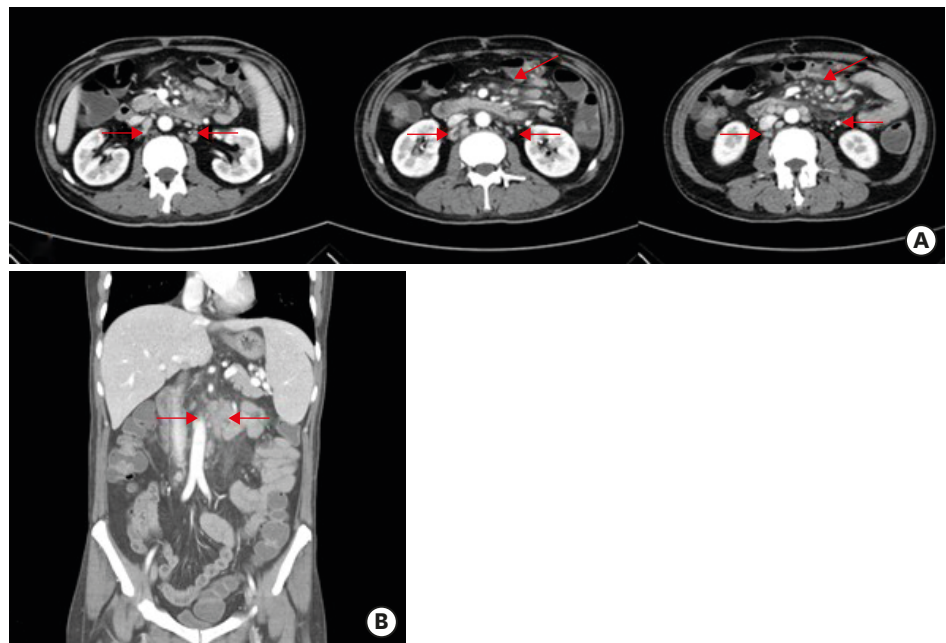


Figure 4. (A) Abdomen/pelvic computed tomography axial plane shows multiple lymph nodes enlargement along mesentery (red arrows, Thirty four days of starting anti-MAC chemotherapy); (B) Abdomen/pelvic computed tomography shows multiple lymph nodes enlargement along mesentery (red arrows). MAC, *Mycobacterium avium complex*.

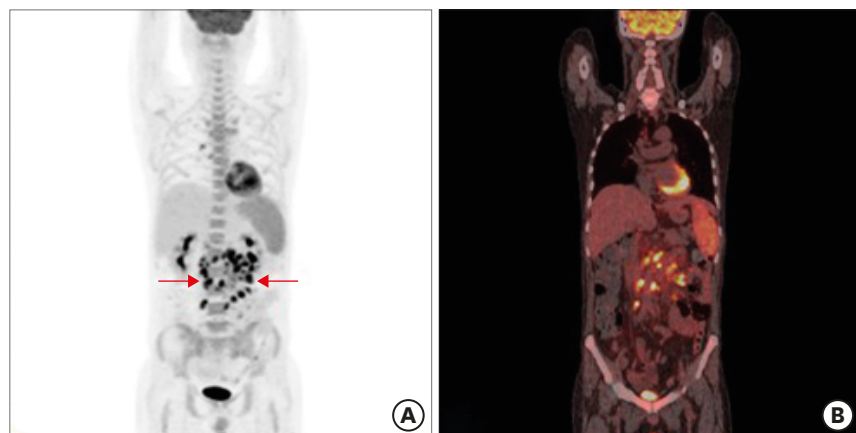

Figure 5. (A) Positron emission tomography image shows multiple enlarged hypermetabolic LNs in mesentery and retroperitoneum of abdomen, right retrocrural area (maximum standard uptake value = 13.4), right lower paratracheal, subcarinal and right hilar area and diffuse hypermetabolic activity in spleen and bone marrow (red arrows); (B) positron emission tomography/computed tomography image.

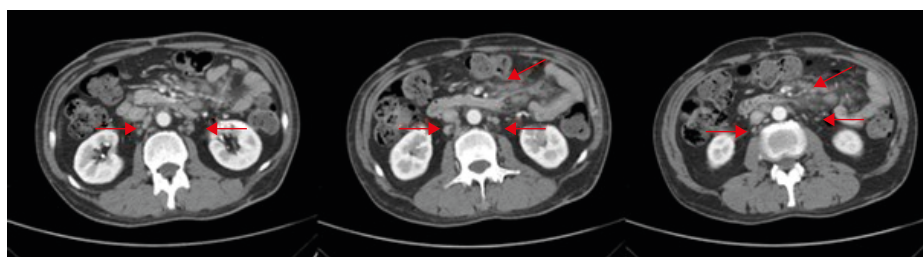
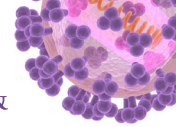


Figure 6. After 10 months of first visit, follow up abdomen/pelvic computed tomography shows slightly decreased size, but still remained multiple enlarged lymph nodes along mesentery (red arrows).

right retrocrural, right lower paratracheal, subcarinal, and right hilar areas, along with diffuse hypermetabolic activity in the spleen and bone marrow. The maximum standard uptake value (SUV) was 13.4. The patient's ferritin level was $> 1,650$ ng/mL, and lactate dehydrogenase (LDH) level was 306 IU/L. We next performed laparoscopic biopsy of the mesenteric LN, and a histological examination of the biopsy specimen revealed partial necrosis (20%); however, no typical granulomas, giant cells, or severe acute and chronic abscesses were found. An AFB staining yielded a positive result, and the biopsy culture grew MAC that was susceptible to macrolides. We started treating him with PD (40 mg), and his abdominal pain and fever resolved. He was discharged on 11th hospital day, and his medication at this time included antiretroviral and antitubercular drugs, along with the steroid.

Eight months of starting anti-MAC chemotherapy, abdomen/pelvic CT (Fig. 6) demonstrated a slightly decreased multiple enlarged LNs were still present. We accordingly recommended treatment continuation; after 4 months of anti-MAC chemotherapy, his symptoms subsided completely, and the steroid was discontinued. In a final drug susceptibility test, minimal inhibitory concentrations were 2 $\mu\text{g}/\text{mL}$ for clarithromycin, 32 $\mu\text{g}/\text{mL}$ for ethambutol, and 4 $\mu\text{m}/\text{mL}$ for rifampin.

DISCUSSION

The present case emphasizes, the importance of considering a diagnosis of IRIS in AIDS patients, when there is a new symptom or aggravation of an existing symptom.

In this case, we experienced two IRIS event: first, unmasked IRIS after the initiation of ART. second, paradoxical IRIS result from anti-MAC chemotherapy. Unmasking IRIS is defined as the presentation of a new disease within the first 3 months of ART [6]. In our patient, we diagnosed a disseminated MAC infection on 17th day of after ART initiation. There are several cases where an unmasked IRIS was reported within 2 weeks of HAART initiation [7, 8]. Even though our patient's medication was stopped for 3 days, the total duration of medication was 2 weeks at the time of fever. Ten days after ART initiation, his CD4 T cell count increased from 31 cells/ mm^3 to 60 cells/ mm^3 . Based on these facts, we thought it was unmasked IRIS with MAC and started anti-NTM treatment.

Paradoxical IRIS occurs in HIV-infected patients with very low CD4 T cell counts at ART initiation; the exact underlying mechanism is not fully understood [9]. As many as 31.4% of MAC infected patients develop IRIS after the initiation of ART [10]. MAC-IRIS occurs in about 3.5% of all HIV-infected patients treated with ART, and 20% of the MAC-IRIS cases are fatal

[11]. Our patient's abdomen/pelvic CT showed homogeneous enhancement and enlargement of the paraaortic, aortocaval, retrocaval, and mesenteric LNs. Even though LNs are invaded in HIV infection, the sites of invasion are typically the cervical, axillary, and inguinal LNs, with the median number of invasion sites being 3 (range 1-7) [12]. Homogeneous LN enhancement is seen in lymphoma, whereas peripheral enhancement is observed in TB [13]. Up to 10% of HIV-infected patients develop non-Hodgkin's lymphoma [14], and our patient's elevated ferritin and LDH levels suggested the possibility of a lymphoma and we conducted a PET-CT to confirm this. A variety of infections and malignancies can result in increased FDG uptake [15]; however there are disease-specific differences in the uptake pattern. Our patient's SUV max was 13.4, while in lymphoma, the reported median SUV max is 12.8 [16]. HIV infection itself, can result in increased FDG uptake in the LNs; however, here the reported average SUV mean values are 3.4 (range 1.8-9.0) [12]. In MAC infection, macrophages are activated and play an important role in the formation of granulomas which increases the FDG uptake, and consequently, PET-CT scans show enhanced FDG uptake in patients with MAC infection. The average SUV max for LNs in NTM infection is 3.59 ± 2.32 (range 1.14 - 9.01), while for TB infection, this value is 7.23 ± 3.03 (range 1.78- 15.72) [17]. Based on our patient's abdomen/pelvic CT and PET-CT finding, we suspected a lymphoma and conducted a LN biopsy that revealed LN involvement of MAC. There has been one reported case of MAC-IRIS where the SUV max was 18.42 [18]. Therefore, a PET-CT is not sufficient to distinguish between a lymphoma and a LN involvement of MAC-IRIS [19], even though it has been an important clinical tool for diagnosing, staging, and monitoring cancer over the last several years [20]. As we have seen, the clinical signs and symptoms of IRIS overlap with those of ARL [4], and it is important to distinguish between the two diseases. Moreover, pathology and culture results remain important for an accurate diagnosis of IRIS.

In the present case, the pronounced LN enlargements and increased FDG-uptake were indicative of ARL; however, as we have shown, the presence of HIV should always increase the index of suspicion for pathologies other than lymphoma. The present case further illustrates the pitfalls of standard techniques, including 18F-FDG PET-CT scan and microscopic examination of biopsies in the setting of HIV. In conclusion, if an HIV-infected patient with a low CD4 T cell count develops signs of ARL shortly after the initiation of HAART, clinicians must consider IRIS as a possible cause. In such cases, definitive diagnostic LN excisional biopsy is mandatory.

REFERENCES

1. Chaisson RE, Moore RD, Richman DD, Keruly J, Creagh T. Incidence and natural history of *Mycobacterium avium*-complex infections in patients with advanced human immunodeficiency virus disease treated with zidovudine. The Zidovudine Epidemiology Study Group. *Am Rev Respir Dis* 1992;146:285-9.
[PUBMED](#) | [CROSSREF](#)
2. Karakousis PC, Moore RD, Chaisson RE. *Mycobacterium avium* complex in patients with HIV infection in the era of highly active antiretroviral therapy. *Lancet Infect Dis* 2004;4:557-65.
[PUBMED](#) | [CROSSREF](#)
3. Phillips P, Bonner S, Gataric N, Bai T, Wilcox P, Hogg R, O'Shaughnessy M, Montaner J. Nontuberculous mycobacterial immune reconstitution syndrome in HIV-infected patients: spectrum of disease and long-term follow-up. *Clin Infect Dis* 2005;41:1483-97.
[PUBMED](#) | [CROSSREF](#)
4. Powles T, Matthews G, Bower M. AIDS related systemic non-Hodgkin's lymphoma. *Sex Transm Infect* 2000;76:335-41.
[PUBMED](#) | [CROSSREF](#)

5. Huhn GD, Badri S, Vibhakar S, Tverdek F, Crank C, Lubelchek R, Max B, Simon D, Sha B, Adeyemi O, Herrera P, Tenorio A, Kessler H, Barker D. Early development of non-hodgkin lymphoma following initiation of newer class antiretroviral therapy among HIV-infected patients - implications for immune reconstitution. *AIDS Res Ther* 2010;7:44.
[PUBMED](#) | [CROSSREF](#)
6. Lapadula G, Soria A, Bandera A, Squillace N, Sabbatini F, Franzetti F, Migliori GB, Gori A. Unmasking tuberculosis in the era of antiretroviral treatment. *Eur Respir J* 2012;39:1064-75.
[PUBMED](#) | [CROSSREF](#)
7. Girardi E, Sabin CA, d'Arminio Monforte A, Hogg B, Phillips AN, Gill MJ, Dabis F, Reiss P, Kirk O, Bernasconi E, Grabar S, Justice A, Staszewski S, Fätkenheuer G, Sterne JA; Antiretroviral Therapy Cohort Collaboration. Incidence of tuberculosis among HIV-infected patients receiving highly active antiretroviral therapy in Europe and North America. *Clin Infect Dis* 2005;41:1772-82.
[PUBMED](#) | [CROSSREF](#)
8. Ko J, Shin B, Lee SS, Lim KS, Lee WJ, Yoo JR, Kang CI. Immune reconstitution inflammatory syndrome presenting as cutaneous miliary tuberculosis in an HIV-infected patient. *Korean J Med* 2014;86:647-50.
[CROSSREF](#)
9. Murdoch DM, Venter WD, Van Rie A, Feldman C. Immune reconstitution inflammatory syndrome (IRIS): review of common infectious manifestations and treatment options. *AIDS Res Ther* 2007;4:9.
[PUBMED](#) | [CROSSREF](#)
10. Wu UI, Chen MY, Hu RH, Hsieh SM, Sheng WH, Lo YC, Hung CC, Chang SC. Peritonitis due to *Mycobacterium avium* complex in patients with AIDS: report of five cases and review of the literature. *Int J Infect Dis* 2009;13:285-90.
[PUBMED](#) | [CROSSREF](#)
11. Müller M, Wandel S, Colebunders R, Attia S, Furrer H, Egger M; IeDEA Southern and Central Africa. Immune reconstitution inflammatory syndrome in patients starting antiretroviral therapy for HIV infection: a systematic review and meta-analysis. *Lancet Infect Dis* 2010;10:251-61.
[PUBMED](#) | [CROSSREF](#)
12. Sathekge M, Maes A, Kgomo M, Van de Wiele C. Fluorodeoxyglucose uptake by lymph nodes of HIV patients is inversely related to CD4 cell count. *Nucl Med Commun* 2010;31:137-40.
[PUBMED](#) | [CROSSREF](#)
13. Yang ZG, Min PQ, Sone S, He ZY, Liao ZY, Zhou XP, Yang GQ, Silverman PM. Tuberculosis versus lymphomas in the abdominal lymph nodes: evaluation with contrast-enhanced CT. *AJR Am J Roentgenol* 1999;172:619-23.
[PUBMED](#) | [CROSSREF](#)
14. Remick SC. Acquired immunodeficiency syndrome-related Non-Hodgkin lymphoma. *Cancer Control* 1995;2:97-103.
[PUBMED](#)
15. Barrington SE, O'Doherty MJ. Limitations of PET for imaging lymphoma. *Eur J Nucl Med Mol Imaging* 2003;30 (Suppl 1):S117-27.
[PUBMED](#) | [CROSSREF](#)
16. Ngeow JY, Quek RH, Ng DC, Hee SW, Tao M, Lim LC, Tan YH, Lim ST. High SUV uptake on FDG-PET/CT predicts for an aggressive B-cell lymphoma in a prospective study of primary FDG-PET/CT staging in lymphoma. *Ann Oncol* 2009;20:1543-7.
[PUBMED](#) | [CROSSREF](#)
17. Del Giudice G, Bianco A, Cennamo A, Santoro G, Bifulco M, Marzo C, Mazzarella G. Lung and nodal involvement in nontuberculous mycobacterial disease: PET/CT role. *Biomed Res Int* 2015;2015:353202.
[PUBMED](#) | [CROSSREF](#)
18. Namkoong H, Fujiwara H, Ishii M, Yagi K, Haraguchi M, Matsusaka M, Suzuki S, Asakura T, Asami T, Saito F, Fukunaga K, Tasaka S, Betsuyaku T, Hasegawa N. Immune reconstitution inflammatory syndrome due to *Mycobacterium avium* complex successfully followed up using 18 F-fluorodeoxyglucose positron emission tomography-computed tomography in a patient with human immunodeficiency virus infection: a case report. *BMC Med Imaging* 2015;15:24.
[PUBMED](#) | [CROSSREF](#)
19. Sathekge M, Maes A, Van de Wiele C. FDG-PET imaging in HIV infection and tuberculosis. *Semin Nucl Med* 2013;43:349-66.
[PUBMED](#) | [CROSSREF](#)
20. Schöder H, Gönen M. Screening for cancer with PET and PET/CT: potential and limitations. *J Nucl Med* 2007;48 (Suppl 1):4S-18S.
[PUBMED](#)