



Case report

Rescue therapy using an endobronchial valve and digital air leak monitoring in Invasive Pulmonary Aspergillosis

Selina Tsim^a, Lia Paton^b, Fiona Nicholson^c, Kevin G. Blyth^{a,*}^a Department of Respiratory Medicine, Southern General Hospital, Glasgow G51 4TF, United Kingdom^b Department of Anaesthesia and Intensive Care Medicine, Southern General Hospital, Glasgow, United Kingdom^c Department of Haematology, Southern General Hospital, Glasgow, United Kingdom

A B S T R A C T

Keywords:

Pneumothorax
Aspergillosis
Bronchoscopy
Immunosuppression
Pulmonary fungal infections
Critical care

In this case report, we describe the utilisation of two recently developed technologies for the successful management of a persistent air leak (PAL) in a critically ill patient in whom cardiothoracic surgical intervention was not possible. We report the case of a young leukaemic woman with a PAL complicating Invasive Pulmonary Aspergillosis (IPA), who was effectively managed using an Endobronchial Valve, supplemented by objective, digital air leak data provided by a Thopaz[®] device (Medela, Switzerland).

© 2014 The Authors. Published by Elsevier Ltd. This is an open access article under the CC BY-NC-SA license (<http://creativecommons.org/licenses/by-nc-sa/3.0/>).

Case report

A 32-year old female with Acute Promyelocytic Leukaemia (APML), previously treated by autogeneic haematopoietic stem cell transplantation (HSCT), presented with pancytopenia and evidence of relapsed disease. She was started on IV Arsenic and All-trans Retinoic Acid (ATRA) as a bridge to allogeneic HSCT, but became pyrexial and increasingly oxygen-dependent. Serial chest radiographs followed by thoracic Computed Tomography (CT) scanning on Day 28 revealed progressive, extensive ground glass opacification (see Fig. 1(a)). Repeat CT imaging on Day 44 demonstrated additional intrapulmonary mass lesions (see Fig. 1(b)). Galactomannan titres (Aspergillus Antigen Index Value 0.89) and subsequent bronchial lavage and pleural fluid cultures would later confirm IPA secondary to *Aspergillus Flavus*.

The patient's illness was complicated by a left-sided tension pneumothorax on Day 56. This prompted intercostal drain (ICD) insertion (12F, Rocket Medical[®]) and ICU admission. Despite appropriate antifungal and supportive therapies and a second ICD (16F, Rocket Medical[®]) the patient's lung failed to re-expand. Invasive mechanical ventilation was avoided and the patient managed with high-level oxygen supplementation. Digital thoracic drainage units (Thopaz[®], Medela, Switzerland) demonstrated a consistent PAL in excess of 2000 ml/min, likely due to a ruptured fungal cavity in the lingular subsegment, which was demonstrated

on a third CT scan on Day 96 (see Fig. 2). The patient was deemed unsuitable for thoracic surgical intervention due to excessive risk. Since EBVs are not a licensed treatment for PAL in the UK National Health Service, applications for funding and internal clinical governance board approval were submitted on compassionate grounds and approved.

Flexible bronchoscopy was initially attempted in ICU under conscious sedation but was poorly tolerated. General anaesthesia was therefore induced and the trachea intubated with manual IPPV applied prior to bronchoscopy. A single 4.0 mm EBV (Zephyr 4.0[®], Pulmonx Inc. Neuchatel, Switzerland) was deployed into the lingular segmental bronchus after inflation of a balloon catheter at this site resulted in complete cessation of air leak. This effect was carefully verified prior to EBV deployment using live air leak data displayed on the Thopaz[®] unit attached to her 16F axillary drain. This was corroborated by cessation of bubbling through the anterior 12F drain circuit, which was attached to wall suction set at −20 cm H₂O pressure. The patient was extubated within one hour of EBV deployment. The 16F axillary ICD was removed 12 h later having demonstrated no measurable air leak on the Thopaz[®] device since the procedure.

Repeat CT imaging 2 weeks later demonstrated satisfactory positioning of the EBV and significant lung re-expansion (see Fig. 3). The remaining 12F ICD was removed 2 weeks later, following a 48-h period during which no measurable air leak had been detected on Thopaz[®]. The patient expectorated the EBV 3 weeks later without any adverse effect and was eventually discharged home following a 5-month admission. Prolonged anti-fungal therapy and continuing IV Arsenic and ATRA are planned.

* Corresponding author. Tel.: +44 (0)141 232 4026.

E-mail address: Kevin.Blyth@ggc.scot.nhs.uk (K.G. Blyth).

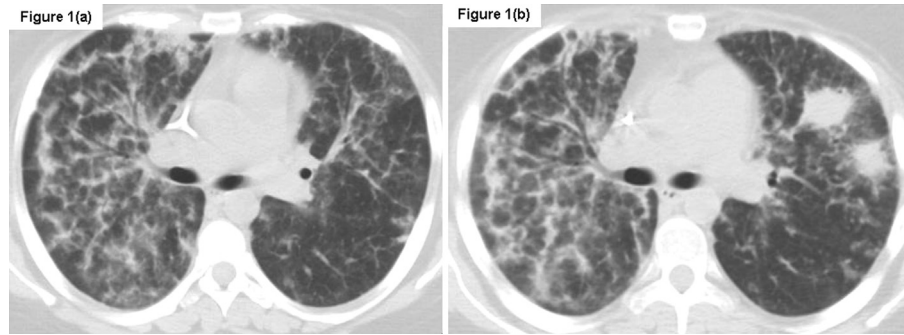


Fig. 1. Axial images from Thoracic Computed Tomography (CT) scans acquired in a 32-year old leukaemic patient with Invasive Pulmonary Aspergillosis (IPA). The selected images, which are from identical slice positions, demonstrate bilateral ground glass opacification on Day 21 ((a)) and new intrapulmonary fungal mass lesions, which had developed by the time of repeat scanning on Day 47 ((b)).

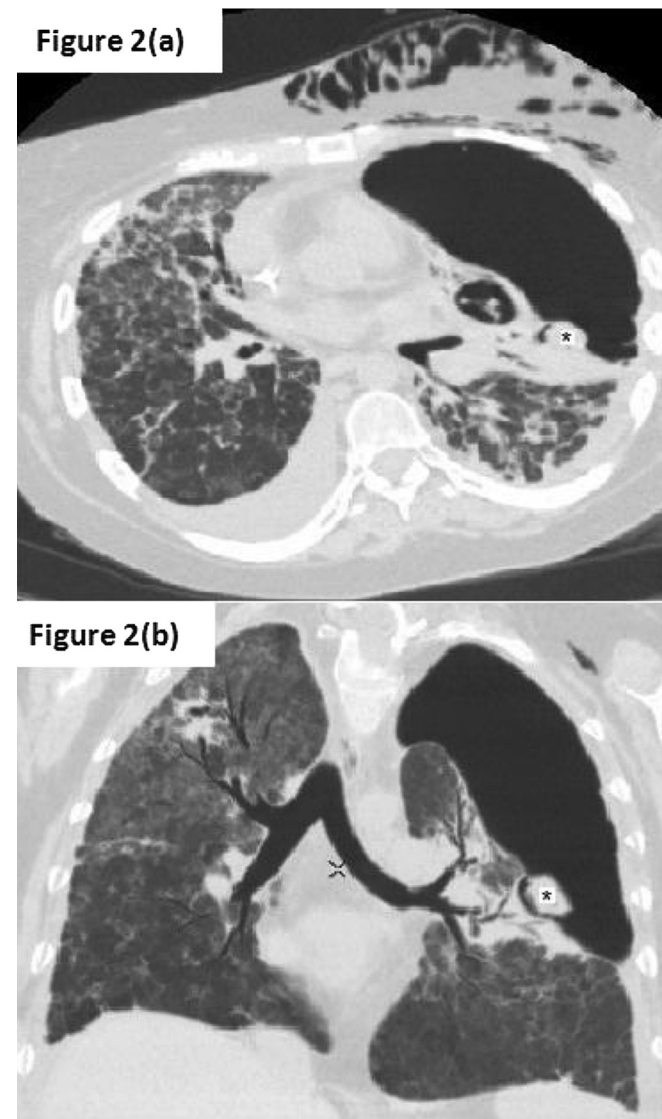


Fig. 2. Selected axial (a) and coronal (b) images from a Thoracic Computed Tomography (CT) scan acquired on Day 96 in a patient with Invasive Pulmonary Aspergillosis (IPA). There is a left-sided tension pneumothorax and subcutaneous emphysema due to a large alveolar-pleural fistula resulting from rupture of a fungal mass lesion (*).

Her most recent bone marrow aspirate demonstrates continued molecular remission and she has been referred for allogeneic HSCT.

Discussion

Persistent air leak (PAL) can be devastating in patients with significant underlying lung disease or other co-morbidities, especially in mechanically-ventilated individuals. In bone marrow transplant recipients particularly, air leaks are an ominous development, with a mortality rate of 75% reported in a previous series, in which death was commonly associated with IPA [1]. In this context, direct air leak attenuation is extremely challenging due to the typically poor physical condition of the patients affected and the high risks associated with surgical management. Non-surgical options include a Medical Pleurodesis, either by talc slurry or autologous blood patch pleurodesis (ABPP). Neither was attempted in this case given the marked failure of lung re-expansion. Talc instillation may also result in severe pain in patients with benign pleural disease and an irrevocable empyema in patients with concomitant lung or pleural infection. ABPP is a painless procedure,

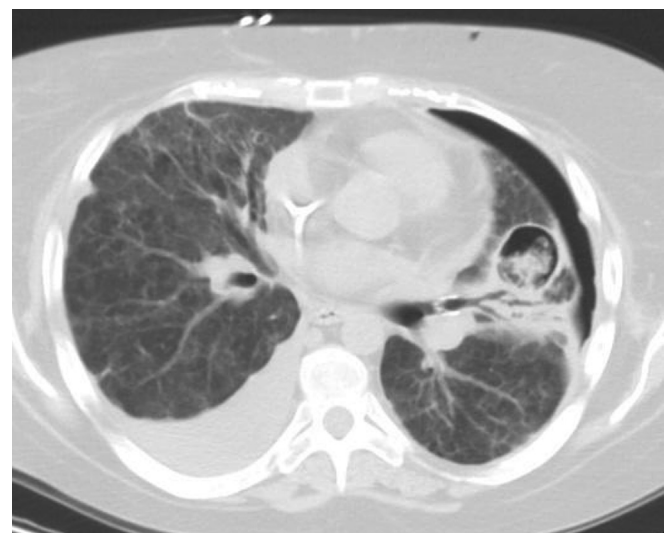

Fig. 3. A single axial image from a Thoracic Computed Tomography (CT) scan acquired on Day 110 in a leukaemic patient with Invasive Pulmonary Aspergillosis (IPA). A 4 mm endobronchial valve (Zephyr[®], Pulmonx Inc. Neuchatel, Switzerland) is demonstrated within the lingular segmental bronchus proximal to an alveolar-pleural fistula caused by rupture of a fungal mass lesion. There has been a significant improvement in the previously demonstrated left-sided pneumothorax.

which in small studies has shown some efficacy in attenuating air leak following lung resection surgery, in spontaneous PTX [2,3] and in mechanically-ventilated patients [4]. We were dissuaded from ABPP by our patient's profound thrombocytopenia, which would have made coagulation and effective 'patch' formation at the site of her air leak unlikely. Since ABPP may also result in drain occlusion by clotted blood and tension PTX, it should also be used with caution in patients with a high-volume PAL.

Given the limitations of these existing, non-surgical options for directly attenuating PAL, management is often limited to continued intercostal drainage and optimization of medical (e.g. infection, nutrition) and ventilator factors where relevant (e.g. limiting tidal volumes, minimizing mean airway pressures and facilitating spontaneous (negative-pressure) breathing). However, these strategies rely on spontaneous healing and closure of the causative broncho- and alveolar-pleural fistula and they are unlikely to be effective in leukaemic patients with IPA, in whom immunosuppressive and toxic oncolytic therapies are often run concurrently and fungal clearance typically requires months of intensive treatment [5]. EBVs offer a non-surgical, minimally-invasive alternative, having been originally developed for endoscopic lung volume reduction in emphysema [6]. Both of the currently available systems (Zephyr® EBV (Pulmonx Inc. Neuchatel, Switzerland)) and Intrabronchial Valve (IBV®, Spiration Inc., Washington, USA) are introduced through the working channel of a flexible bronchoscope and utilise a unidirectional valve to prevent airflow into the diseased area of lung. This results in collapse of distal lung parenchyma and attenuation of any air leak.

In the largest case-series to date, Travaline et al. described complete or partial air leak cessation in 93% ($n = 37/40$) of patients treated with Zephyr® EBVs, including cases of spontaneous, post-operative, traumatic and iatrogenic PTX. Median time from valve insertion to ICD removal was 7.5 days [7]. Gillespie et al. reported use of Respiration IBVs® in 7 patients with PAL related to secondary spontaneous (3/7) and post-operative PTX (4/7); 75% ($n = 6$) had complete air leak cessation after a mean of 4.5 days, with ICD removal after a median of 16 days [8]. There have also been individual case reports and smaller series describing successful use of EBVs to treat PAL complicating bacterial empyema, pneumonia and ARDS [9–12] including a series of 3 mechanically-ventilated ICU patients. In this series, EBV deployment facilitated rapid weaning from ventilation or high-level oxygen supplementation [12], as was possible in this case described here.

Digital thoracic drainage systems, such as the Thopaz® unit (Medela, Switzerland) utilised here allow objective, real-time, quantitative assessment of air leak via an ICD. Live digital air leak data (flow rate measured in ml/min) is displayed on a screen incorporated into the device. Importantly, this data is also recorded continuously, and presented as a graph of the preceding 24 h air

leak data. This allows objective decisions to be made during EBV deployment (regarding correct positioning of the device) and during subsequent management, supplementing and potentially replacing traditional subjective, qualitative assessments based on the presence or absence of bubbling in the ICD bottle.

This brief report illustrates the considerable therapeutic utility of EBVs in this context but also demonstrates the value of objective air leak data in clinical decision-making in this setting, particularly with regard to optimising EBV deployment and the removal of ICDs in patients with life-threatening PTX. EBVs are a minimally-invasive and potentially life-saving rescue therapy, which should be considered in this setting and tested in a future prospective, controlled study.

Funding

No financial support was provided for this case report.

References

- [1] Ramos ER, Jiang Y, Hachem R, Kassis C, Kontoyiannis DP, Raad I. Outcome analysis of invasive aspergillosis in haematologic malignancy and haemopoietic stem cell transplant patients: the role of novel antimold azoles. *Oncologist* 2011;16(7):1049–60.
- [2] Mallen JK, Landis JN, Frankel KM. Autologous 'blood patch' pleurodesis for persistent pulmonary air leak. *Chest* 1993;103:326–7.
- [3] Ando M, Yamamoto M, Kitagawa C, Kumazawa A, Sato M, Shima K, et al. Autologous blood-patch pleurodesis for secondary spontaneous pneumothorax with persistent air leak. *Respir Med* 1999;93:432–4.
- [4] Martinez-Escobar S, Ruiz-Bailen M, Lorente-Acosta MJ, Vicente-Rull JR, Martinez-Coronel JF, Rodriguez-Cuartero A. Pleurodesis using autologous blood: a new concept in management of persistent air leak in acute respiratory distress syndrome. *J Crit Care* 2006;21:209–16.
- [5] Denning DW. Therapeutic outcome in invasive aspergillosis. *Clin Infect Dis* 1996 Sep;23(3):608–15.
- [6] Sciruba FC, Ernst A, Herth FJ, Strange C, Criner GJ, Marquette CH, et al. VENT Study Research Group. A randomized study of endobronchial valves for advanced emphysema. *N Engl J Med* 2010 Sep 23;363(13):1233–44.
- [7] Travaline JM, McKenna RJ, De Giacomo T, Venuta F, Hazelrigg SR, Boomer M, et al. Treatment of persistent pulmonary air leaks using endobronchial valves. *Chest* 2009;135(2):355–60.
- [8] Gillespie CT, Daniel HS, Cerfolio RJ, Nader D, Mulligan MS, Mularski RA, et al. Endobronchial valve treatment for prolonged air leaks of the lung: a case series. *Ann Thorac Surg* 2011;91:270–3.
- [9] Fielding DI, Bashirzadeh F, Deller D, Douglas A, Boots R, Hopkins P. Life-saving closure of a pulmonary cavity by endobronchial valve placement. *Am J Respir Crit Care Med* 2013 May 15;187(10):1145–6.
- [10] Feller-Kopman D, Bechara R, Garland R, Ernst A, Ashiku S. Use of a removable endobronchial valve for the treatment of bronchopleural fistula. *Chest* 2006;130:273–5.
- [11] Toma TP, Min Kon O, Oldfield O, Sanefuji R, Griffiths M, Wells F, et al. Reduction of persistent air leak with endoscopic valve implants. *Thorax* 2007;62:830–3.
- [12] Mahajan AK, Verhoef P, Patel SB, Carr G, Hogarth KD. Intrabronchial valves: a case series describing a minimally invasive approach to bronchopleural fistulas in medical intensive care unit patients. *J Bronchol Interv Pulmonol* 2012 Apr;19(2):137–41.