

## Renal manifestations of tuberous sclerosis among children: an Indian experience and review of the literature

Sophy Korula<sup>1</sup>, Alka Ekbote<sup>2</sup>, Naresh Kumar<sup>1</sup>, Sumita Danda<sup>2</sup>, Indira Agarwal<sup>1</sup> and Swasti Chaturvedi<sup>1</sup>

<sup>1</sup>Department of Paediatrics, Christian Medical College and Hospital, Vellore, Tamil Nadu, India and <sup>2</sup>Department of Medical Genetics, Christian Medical College Hospital, Vellore, Tamil Nadu, India

Correspondence and offprint requests to: S. Korula; E-mail: jsophyhr@yahoo.co.in

### Abstract

**Objective.** The objective of this study was to describe the renal manifestations in children 0–18 years of age diagnosed with tuberous sclerosis complex (TSC) at a tertiary hospital in South India.

**Methods.** Data of children with TSC, who presented to Christian Medical College Vellore Hospital from January 2008 to January 2013, were analysed by a retrospective chart review. The cases were identified from outpatient records and underwent ultrasonography, urine analysis and examination of serum creatinine to recognize renal involvement.

**Results.** Twenty-five children with TSC were identified. Two children did not have imaging studies available and were excluded from the analysis. The age of the included children ranged from 5 days to 15 years with a median age of 8 years. Seventy-four per cent (17/23) were males. Ten of the 23 children had evidence of renal involvement (43.5%). Of the 10 children with renal involvement, 6 had angiomyolipoma (60%), 5 had renal cysts (50%) and 1 had suspected renal cell carcinoma. In two children both angiomyolipoma (AML) and cysts were noted. One child was found to have proteinuria. The rest of the children had no evidence of proteinuria and had normal creatinine clearance.

**Conclusion.** We conclude that all children with TSC should be screened for renal involvement and regular follow-up should be arranged.

**Keywords:** angiomyolipoma; renal cell carcinoma; renal cyst; renal lesions; tuberous sclerosis

### Introduction

Tuberous sclerosis complex (TSC) is an autosomal dominant, multisystem, genetic disorder that affects ~1/6000 to 1/10 000 live births [1, 2]. There are two genes responsible for the development of TSC: TSC1 on chromosome 9q34 and TSC2 on chromosome 16p13.3 that encode for hamartin and tuberin proteins, respectively [3, 4]. Mutations in either gene result in hamartomas affecting the brain, heart, eye, skin, kidney and other organs [1]. Although TSC is inherited in an autosomal dominant manner there is a high rate of spontaneous mutations and in nearly two-thirds of the patients there is no parental history [2]. The gene for autosomal dominant polycystic kidney disease (ADPKD) 1 (ADPKD1) lies adjacent to the TSC2 gene on chromosome 16, and 'contiguous gene deletions' can result in multiple renal cystic lesions, similar to those seen in polycystic kidney disease [5].

The diagnosis of tuberous sclerosis is mainly clinical and is usually complicated by varied phenotypic features (Table 1) [6]. 'Definite TSC' is diagnosed when either two major features or one major and two minor features are present [6].

Renal lesions are observed in 48–80% of those with TSC and may be in the form of angiomyolipomas (AML), cysts

and rarely renal cell carcinoma (RCC) [7]. It has been observed that mutations in TSC2 result in greater severity of renal disease, and a number of studies have analysed the genotype–phenotype correlations [8, 9]. Although TSC-associated manifestations are commonly reported in the West, there is a scarcity of data from India. To the best of our knowledge, renal involvement in TSC has not been systematically studied so far among children from Southeast Asian origin. As renal pathology is the second most common cause of morbidity and mortality in this cohort of children [10], we decided to do a retrospective chart analysis to study the same.

### Materials and methods

The Christian Medical College is a tertiary academic centre in South India and is one of the largest hospitals in the country. Approximately 5000 children are seen in the Paediatric Nephrology outpatient clinic annually. We retrospectively reviewed medical records from January 2008 till January 2013 and identified 25 children with TSC. Cases were defined as children from age group 0 to 18 years with confirmed diagnosis of TSC (based on the clinical

**Table 1.** Diagnostic features of TSC

Major features	Minor features
Facial angiofibroma	Dental enamel pits
Periungual fibroma	Hamartomatous rectal polyps
Hypopigmented macules (>3)	Bone cysts
Shagreen patch	Cerebral white matter migration lines
Multiple retinal nodular hamartomas	Gingival fibromas
Cortical tuber	Non-renal hamartoma
Subependymal nodule	Retinal achromatic patch
SGCT(subependymal giant cell tumour)	Confetti skin lesions
Cardiac rhabdomyomas, single or multiple	Multiple renal cysts
Lymphangiomyomatosis	
Renal angiomyolipoma	

**Table 2.** Demographic profile and imaging findings of patients with renal involvement

S. no	Sex	Age	Renal ultrasound finding
1	M	11 years	Multiple cysts bilateral, largest on right—39 × 30 mm, left—46 × 30 mm
2	F	7 years	Multiple cysts bilateral kidneys suggestive of polycystic kidney disease, left kidney angiomyolipoma 18 × 17 mm
3	M	2 years	Right kidney two small angiomyolipoma in the upper pole
4	M	9 years	Left para-pelvic renal cyst 10 × 10 mm
5	F	5 years	Bilateral multiple angiomyolipoma 6–7 mm
6	M	3 years–8 months	Bilateral cysts 9–10 mm multiple and bilateral single angiomyolipoma 9 × 7, 8 × 6 mm in size
7	M	5 days	Right kidney single angiomyolipoma, 14 × 12 mm
8	M	12 years	Bilateral angiomyolipomas tiny 3 mm
9	F	15 years	One large mildly lobulated left kidney mass: 120 × 83 × 64 mms suggestive of renal cell carcinoma
10	M	10 years	Multiple cysts 3–4 mm in the left kidney

criteria defined by the Tuberous Sclerosis Consensus Conference) [11] who had at least one radiologic kidney imaging done. Demographic details, biochemical and radiologic data were compiled from their case sheets. This study was done after clearance from the institutional ethics review board.

## Results

Twenty-five children were identified. Of these 2 patients did not have any radiologic data, hence data from 23 patients were analysed for the purpose of this study. These included 17 males (74%) and 6 females (26%). Patient's age at the first imaging ranged from 5 days to 15 years with a median of 8 years. The presenting features were varied with seizures being the commonest.

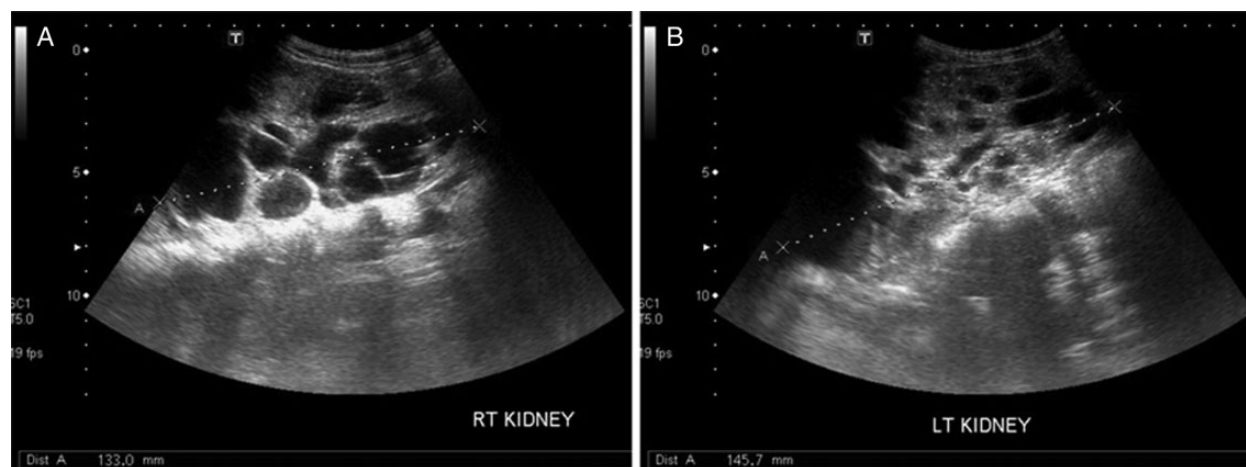
Ten (43.5%) of the 23 patients had evidence of renal involvement on ultrasound (Table 2). Six of the 10 children had AML (60%), 5 had renal cysts (50%) and 1 had suspected left renal cell carcinoma. In two children both AML and cysts were noted. Fifty per cent of AMLs were solitary, whereas 80% of renal cysts were multiple. Fifty per cent of AMLs were detected in children <5 years of age, whereas only 20% of renal cysts occurred in this age group. One child presented with a history of noticeable abdominal

mass since the past few months at 15 years of age (Table 2, Patient 9). She underwent contrast enhanced abdominal CT scan which revealed a large lobulated mass (12 × 8.3 × 6.4 cms) with few small areas of necrosis. She was thus suspected to have renal cell carcinoma and a nephrectomy was planned. She was unfortunately lost to follow-up. Another child had 2+ proteinuria on urine dipstick with an elevated early morning spot urine protein/creatinine ratio of 1.20. Her renal ultrasound revealed bilaterally enlarged kidneys with numerous cysts, thus raising the possibility of tuberous sclerosis-autosomal dominant polycystic kidney disease (TSC-ADPKD) contiguous gene deletion syndrome (Table 2, Patient 2 and Figure 1). Her serum creatinine and blood pressure were normal.

## Discussion

TSC is caused by mutations in either of the causative genes, TSC1 or TSC2 genes. Whereas mutations in TSC1 and TSC2 impact the same organ systems, TSC2 mutations result in a more severe clinical profile [1, 2]. It has been postulated that the TSC1/TSC2 complex regulates the proliferation and differentiation of an early renal precursor cell. Thus, cells that have either of the two mutations retain the ability to differentiate into both epithelial and mesenchymal tumours. This results in varied renal manifestations in TSC with the ability of lesions to contain both epithelial and mesenchymal derivatives. Estimated rates of renal involvement in TSC range from 48 to 80% [7, 10, 12–16]. A comparison of the various studies (Table 3) reveals a slightly lower percentage of renal involvement in our study of 43.5%. A noteworthy point is that our study was restricted to paediatric patients, whereas most of the other studies had both paediatric and adult patients. Since renal lesions in TSC tend to evolve and increase over time it is plausible that the percentage of renal involvement will increase over time in our cohort. In keeping with this hypothesis, the burden of renal lesions in our study was similar to another paediatric study by Castagnetti *et al.* [17] who reported renal involvement in 36.6% of children. Another possibility could be the ethnic differences as this is perhaps the first data from a South-east Asian population and thus needs to be explored further.

The frequency of the specific renal lesions is also highlighted in Table 3. Angiomyolipomas were the commonest in all the studies (Table 3). In our study 60% (6/10) of the lesions were AML. Angiomyolipomas are benign tumours composed of fat, abnormal blood vessels and smooth muscle tissue in variable proportions. Renal AML's are seen in the cortex and occur more commonly in females with TS [14]. In our study, the male: female ratio was 4:2 which was probably because we had more males in the study. At one point assessment, 50% (3/6) of the AML's were present in children <5 years. The youngest child in our cohort with AML was diagnosed at 5 days of age and the average age at diagnosis was 5.0 years in our study. This is much lower than the earlier reported average age at diagnosis of AML in the study by Rakowski *et al.* of 11.0 years and other studies of 9.2 years [10, 14]. This finding is important and thus necessitates an ultrasound screening for all children diagnosed with TSC irrespective of the age. AMLs also tend to evolve and increase in size and number with age [10]. This can be demonstrated with follow-up renal screening. The potential complications of



**Figure 1:** Renal ultrasound of patient 2 showing enlarged right (13.3 cm) and left (14.6 cm) kidneys with multiple cysts in cortex and medulla.

**Table 3.** Renal involvement in tuberous sclerosis: our study and literature review

SN	First author	Reference	Year	Setting	n	Renal involvement	AML	Cysts	RCC
1	Current study	-	2013	Single centre, India	23	10 (43.5%)	6 (60%)	5 (50%)	1 (10%)
2	Castagnetti	[17]	2007	Single centre, Italy	41	15 (36.5%)	11 (73%)	4 (26.6%)	Nil
3	Rakowski	[14]	2006	Single centre, USA	167	96 (57.5%)	82 (85%)	43 (45%)	4 (4%)
4	O' Callaghan	[13]	2004	Population based, South England	124	-	86 (69%)	37 (30%)	1 (0.6%)
5	Casper	[10]	2002	Single centre, USA	59	~80%	47 (80%)	28 (47%)	Nil
6	Ewalt	[7]	1998	Single centre, USA	60	33 (55%)	33 (55%) initially, later 45 (75%)	6 (10%) initially, later 10 (17%)	1 (1.3%)
7	Cook	[12]	1996	Two centres, UK	139	85 (61%)	68 (83%)	45 (53%)	Nil
8	Webb	[16]	1994	Population based, UK	21	10 (50%)	7 (33%)	3 (14%)	-
9	Stillwell	[15]	1987	Single centre, USA	95	51 (54%)	45 (88%)	17 (33%)	-

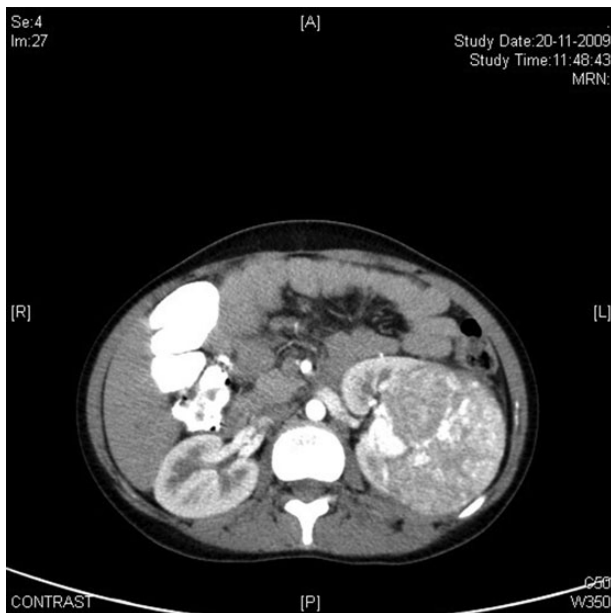
SN, serial number; AML, angiomyolipoma; RCC, renal cell carcinoma.

AML include haemorrhage and mass effect, both of which are commonly seen in lesions >40 mm size [18, 19]. These large AMLs may thus require surgical intervention, emphasizing the need for regular follow-up. The maximum size of AMLs in our study was 18 × 17 mm seen in a 7-year-old girl (Table 2, Patient 2).

The next most common renal manifestation in TSC is isolated cysts, which are seen in 17–35% [7]. In our study 50% (5/10) of the renal lesions were identified to be cysts. The average age at diagnosis of the renal cyst was 8.2 years in our study which is similar to other studies which quote 9–11 years [10, 14]. Sixty per cent (3/5) of the cysts were bilateral in our study. Other studies show that this ranges from 49 to 82% (Table 3). These lesions rarely progress to renal failure in TSC unless associated with ADPKD. The TSC2 -ADPKD1 contiguous gene deletion syndrome is important because renal failure develops at an early age from polycystic kidney disease and these patients have a high risk of renal malignancy, which also develops at an early age [20]. In our series, there was one child who had bilaterally enlarged kidneys with numerous cysts involving both cortex and medulla along with an AML of 18 × 17 mm size in the left kidney. Based on these findings, we suspect her to have 'contiguous gene deletion' syndrome. She was normotensive but had non-nephrotic-range proteinuria and was commenced on angiotensin-converting enzyme inhibitor. Her creatinine clearance is normal and regular follow-up has been arranged.

Renal cell carcinoma was suspected in one child (1/10) in our study. This is much higher than the 1–2% quoted in the literature [7]. This could possibly be due to the smaller cohort of patients in our study (Table 2, Patient 9, Figure 2). Her blood pressure and urine exam was normal and she was planned for surgical intervention, however, she was lost to follow-up. RCC also occurs at an earlier age in TSC as compared to RCC in the general population. The average age of diagnosis of RCC in TSC is 28 years although case reports have even reported RCC in an infant [21, 22]. The usual treatment approach is surgical resection for RCC. Studies have shown an overall 5-year survival rate of 52% for all cases of RCC among children and 70% in the non-metastatic group, although there is no clear data regarding this in children with TSC [23].

Renal disease poses a significant burden on patients with TSC and renal failure was identified as a leading cause of death in TSC in one study [23]. In France, the prevalence of TSC with end-stage renal failure was reported to be 0.7 cases per million and that of end-stage renal failure in TSC to be 1 per 100 [24]. It is more frequent in females (63.1%) and was diagnosed at a mean age of 29 years [24]. Genotype-phenotype studies demonstrate an increased renal morbidity with TSC2 mutations [25]. The mammalian target of rapamycin complex (mTOR) is a downstream target of the hamartin/tuberin complex and implicated in renal lesions in TSC. The use of an mTOR inhibitor such as everolimus may serve as a



**Figure 2:** Abdominal CT scan (contrast) of patient 9 showing a large lobulated renal mass (12 × 8.3 × 6.4 cms) with few small areas of necrosis, suggestive of a renal cell carcinoma.

targeted therapy in the future as demonstrated in a recent trial [26].

Renal lesions in TSC evolve over a period of time and hence periodic renal screening is mandatory [10, 14]. Rakowski *et al.* [14] recommend a baseline renal ultrasound for all children with TSC before 5 years of age and if normal a rescreening after 2–3 years. If the imaging suggests an AML or cyst then yearly ultrasound screening is recommended. If RCC is detected an MRI is useful for diagnosis.

Our study highlights the burden of renal involvement in children with TSC in a tertiary hospital setting in South India. It reveals a slightly lower percentage of renal involvement (43.5%) in our study. However, since renal lesions in TSC evolve and develop over time, we anticipate that this burden will rise on follow-up. The possibility of ethnic differences also needs to be considered and this necessitates reporting of data from South-east Asian children. The presence of one child with probable RCC and another diagnosed at 5 days of age with AML again highlights the need for renal screening and regular follow-up among all patients with TSC. We hope this study will also serve as a platform for further research into the prevalence of burden of renal disease in TSC and genotype–phenotype correlation studies in our population.

## REFERENCES

- Crino PB, Nathanson KL, Henske EP. The tuberous sclerosis complex. *N Engl J Med* 2006; 355: 1345
- Curatolo P, Bombardieri R, Jozwiak S. Tuberous sclerosis. *Lancet* 2008; 372: 657–668
- Slegtenhorst MV, Hoogt RD, Hermans C *et al.* Identification of the tuberous sclerosis gene TSC1 on chromosome 9q34. *Science* 1997; 277: 805–808
- The European Chromosome 16 Tuberous Sclerosis Consortium. Identification and characterization of the tuberous sclerosis gene on chromosome 16. *Cell* 1993; 75: 1305–1315
- Brook-Carter PT, Peral B, Ward CJ *et al.* Deletion of the TSC2 and PKD1 genes associated with severe infantile polycystic kidney disease—a contiguous gene syndrome. *Nat Genet* 1994; 8: 328–332
- Schwartz RA, Fernández G, Kotulska K *et al.* Tuberous sclerosis complex: advances in diagnosis, genetics, and management. *J Am Acad Dermatol* 2007; 57: 189–202
- Ewalt DH, Sheffield E, Sparagana SP *et al.* Renal lesion growth in children with tuberous sclerosis complex. *J Urol* 1998; 160: 141–145
- Au KS, Williams AT, Roach ES *et al.* Genotype/phenotype correlation in 325 individuals referred for a diagnosis of tuberous sclerosis complex in the United States. *Genet Med* 2007; 9: 88–100
- Jones AC, Shyamsundar MM, Thomas MW *et al.* Comprehensive mutation analysis of TSC1 and TSC2—and phenotypic correlations in 150 families with tuberous sclerosis. *Am J Hum Genet* 1999; 64: 1305–1315
- Casper KA, Donnelly LF, Chen B *et al.* Tuberous sclerosis complex: renal imaging findings. *Radiology* 2002; 225: 451–456
- Roach ES, Sparagana SP. Diagnosis of tuberous sclerosis complex. *J Child Neurol* 2004; 19: 643–649
- Cook JA, Oliver K, Mueller RF *et al.* A cross sectional study of renal involvement in tuberous sclerosis. *Med Genet* 1996; 33: 480–484
- O’Callaghan FJ, Noakes MJ, Marty CN *et al.* An epidemiological study of renal pathology in tuberous sclerosis complex. *BJU Int* 2004; 94: 853–857
- Rakowski SK, Winterkorn EB, Paul E *et al.* Renal manifestations of tuberous sclerosis complex: Incidence, prognosis, and predictive factors. *Kidney Int* 2006; 70: 1777–1782
- Stillwell TJ, Gomez MR, Kelalis PP. Renal lesions in tuberous sclerosis. *J Urol* 1987; 138: 477–481
- Webb DW, Kabala J, Osborne JP. A population study of renal disease in patients with tuberous sclerosis. *Br J Urol* 1994; 74: 151–154
- Castagnetti M, Beatrice Vezzù B, Laverda AM *et al.* Urological counseling and followup in pediatric tuberous sclerosis complex. *J Urol* 2007; 178: 2155–2159
- Yamakado K, Tanaka N, Nakagawa T *et al.* Renal angiomyolipoma: relationships between tumor size, aneurysm formation, and rupture. *Radiology* 2002; 225: 78–82
- Bissler JJ, Kingswood JC. Renal Angiomyolipomata. *Kidney Int* 2004; 66: 924–934
- Sampson JR, Maheshwar MM, Aspinwall R *et al.* renal cystic disease in tuberous sclerosis: role of the polycystic kidney disease 1 gene. *Am J Hum Genet* 1997; 61: 843–851
- Breysem L, Nijs E, Proesmans W *et al.* Tuberous sclerosis with cystic renal disease and multifocal renal cell carcinoma in a baby girl. *Pediatr Radiol* 2002; 32: 677–680
- Washecka R, Hanna M. Malignant renal tumors intuberous sclerosis. *Urology* 1991; 37: 340–343
- Shepherd CW, Gomez MR, Lie JT *et al.* Causes of death in patients with tuberous sclerosis. *Mayo Clin Proc* 1991; 66: 792–796
- Schillinger F, Montagnac R. Chronic renal failure and its treatment in tuberous sclerosis. *Nephrol Dial Transplant* 1996; 11: 481–485
- Dabora SL, Jozwiak S, Franz DN *et al.* Mutational analysis in a cohort of 224 tuberous sclerosis patients indicates increased severity of TSC2, compared with TSC1, disease in multiple organs. *Am J Hum Genet* 2001; 68: 64–80
- Bissler JJ, Kingswood JC, Radzikowska E *et al.* Everolimus for angiomyolipoma associated with tuberous sclerosis complex or sporadic lymphangioleiomyomatosis (EXIST-2): a multi-centre, randomised, double-blind, placebo-controlled trial. *Lancet* 2013; 381: 817–824