

OPEN

# Evaluation of an Infant Temporal-Bone Model as Training Tool

\*†Rudolf Probst, \*†Reto Stump, ‡Markus Mocosch, and \*†Christof Rösli

\*Department of Otorhinolaryngology, Head and Neck Surgery, University Hospital Zürich; †University of Zürich, Zürich, Switzerland; and ‡Phacon GmbH, Leipzig, Germany

**Objective:** Evaluation of the face validity of a new artificial model of an infant temporal bone (TB) suitable for surgical training, including cochlear implantation.

**Subject:** Micro-computer-tomography images were obtained from a TB specimen of a 1-year-old normal infant available in an anatomical collection. The TB model was designed and constructed using these images and techniques known from similar models of adult TB.

**Intervention:** Fifteen otology departments in Austria, Germany, and Switzerland rated the infant TB model and compared it with the established adult TB model manufactured commercially by the same company.

**Main Outcome Measure:** The otologists responded to a semi-quantitative questionnaire with a rating scale ranging from 1 (strongly disagree) to 5 (strongly agree). Macroscopic and microscopic anatomic details, drilling experience, and surgical landmarks were rated. The surgical procedures

included mastoidectomy, posterior tympanotomy, cochleostomy, and insertion of a cochlear electrode.

**Results:** Overall ratings were similar (3.9) for both the infant and the adult TB models, with ranges of 3.47 to 4.47 (infant model) and 3.5 to 4.33 (adult model). Ratings of specific anatomical details differed as a function of type of model, but without preference of one model over the other.

**Conclusions:** Infant TB models can be used similarly as adult TB models for surgical training, including cochlear implantation. They may deserve a more important role in surgical training because cadaveric human temporal bones of infants are not available. **Key Words:** Cochlear implant surgery—Mastoidectomy—Pediatric otological surgery—Posterior tympanotomy—Surgical training.

*Otol Neurotol* 39:e448–e452, 2018.

Because human cadaveric temporal bones (TB) may be difficult to obtain in sufficient quantities due to ethical, cultural, regulatory, or financial restrictions, surgical training in otology often includes the use of virtual (1,2) or artificial TB models (3,4). Cadaveric TB of infants or small children are not available and pediatric otological surgery must be based on appropriate artificial and virtual models or on apprenticeship only.

A Cochrane Review (1) on the effect of virtual reality in otorhinolaryngological surgical training concluded that such training could allow development of technical skills, but that better real world outcomes for patients were still an open question. Another recent meta-analysis

of the influence of virtual training on mastoidectomy demonstrated an improvement in trainee performance (2). Virtual training models have not been evaluated explicitly for pediatric temporal bones (5,6), but some manufacturers such as Voxel-man (Hamburg, Germany) allow a patient's computer-tomography (CT) data to be uploaded, including those from infants.

Rose et al. (7) described the 3D-printing fabrication of a patient-specific model for preoperative simulation in an 11-year-old boy based on conventional CT scan data. The accuracy of bony landmarks was reported to be excellent. Longfield et al. (8) described the use of a printed pediatric TB model, also based on conventional CT scan data. No formal evaluation of this model was reported. Even though the use of office-based 3D-printers may become a promising approach for artificial TB models, presently a composite fabrication including different materials is difficult or impossible for office-based 3D printers. Moreover, the process requires specific equipment, knowledge, and time.

An alternative is the use of commercial TB models with the advantage of availability and accessibility (4,9). We have reported the evaluation of a composite artificial model of an adult TB exhibiting accurate material and anatomical similarity (9). The model was based on imaging data obtained by micro-CT of a human TB. We report here the evaluation of an infant TB model

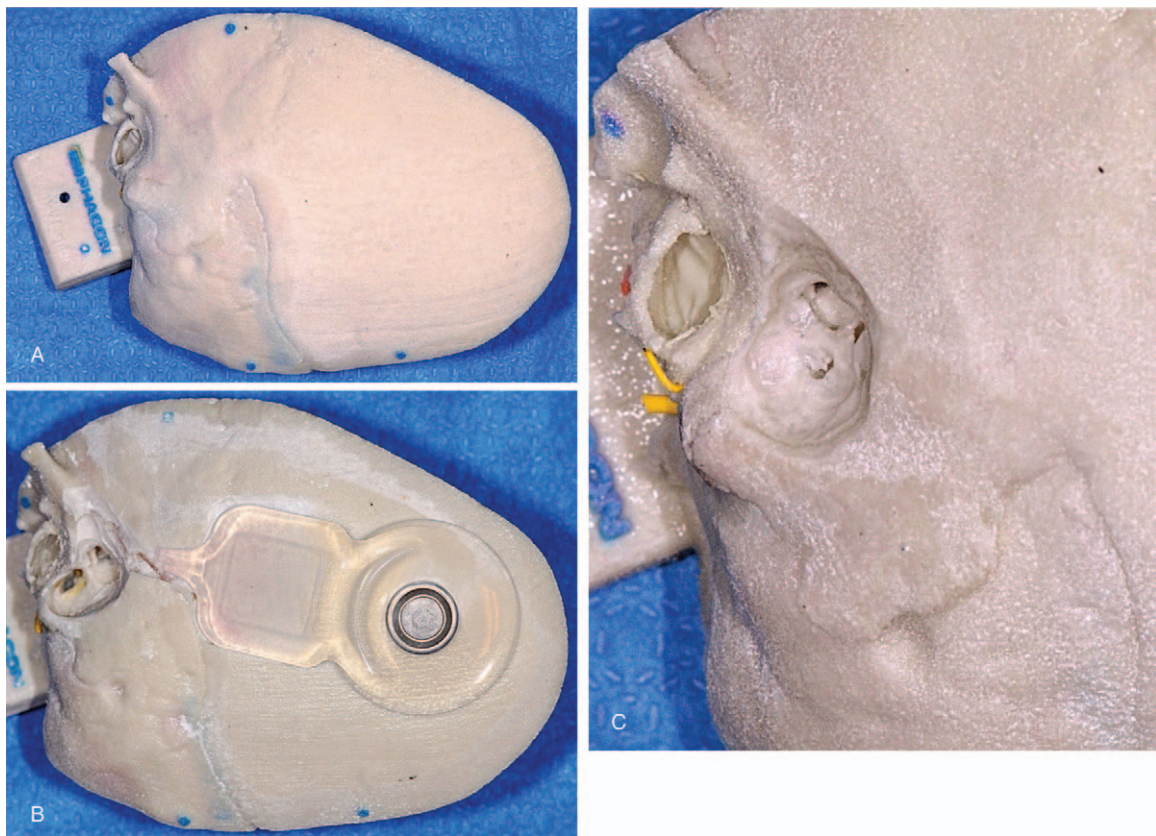
Address correspondence and reprint requests to Rudolf Probst, M.D., Department of Otorhinolaryngology, Head and Neck Surgery, University Hospital Zürich, Frauenklinikstrasse 24, CH-8091 Zürich, Switzerland; E-mail: rudolf.probst@usz.ch

PHACON provided the temporal bone models and transportation costs.

The authors disclose no conflicts of interest.

This is an open access article distributed under the terms of the Creative Commons Attribution-Non Commercial-No Derivatives License 4.0 (CCBY-NC-ND), where it is permissible to download and share the work provided it is properly cited. The work cannot be changed in any way or used commercially without permission from the journal.

DOI: 10.1097/MAO.0000000000001839



**FIG. 1.** Infant temporal bone model “PHACON: Klein - TF-kc.” (A) Intact model, (B) model after opening of the mastoid air cells, and (C) model with a cochlear implant receiver fixed to the squama.

(Fig. 1), also based on micro-CT data of an infant TB, manufactured by the same processes (PHACON, Germany), and providing the same anatomical details as the adult model. The evaluation examined only the face-validity and not the content-validity of the model, i.e., whether practice on the model can improve a novice’s surgical skills.

## METHODS

The infant TB models were manufactured by PHACON (10). The manufacturing process was essentially the same as for adult TB models, described in details by Roosli et al. (9). Briefly, the models are based on data acquired by micro-CT scanning of human cadaveric TBs with a 12- $\mu$ m resolution. The infant TB was scanned from a preserved normal skull of a 1-year-old infant. The fabrication used a printing process with a 3D printer (ZTM510, 4D Concepts, Gross-Gerau, Germany) using a cast powder and a bonding agent providing material properties similar to bone. Structures such as the facial nerve were printed as hollow channels and they were filled with colored wires or polyurethane mixtures. Silicon sheets were used as dura, the tympanic membrane, and the round window.

Experienced surgeons were asked to evaluate both the infant and the adult TB models at the same time. We devised a semi-quantitative questionnaire for the ratings of the models compared with the real experience of the examiner. Ratings included general assessments of the realistic properties of structures and the surgical experience, anatomical landmarks without and with

the operating microscope, and the drilling process to perform a mastoidectomy, a posterior tympanotomy, and a cochleostomy. The questions were answered using a 5-point Likert scale with the categories of 1 (strongly disagree), 2 (disagree), 3 (neither agree nor disagree), 4 (agree), and 5 (strongly agree). Ratings of the adult and infant models were compared.

The questionnaire also gathered information on the clinical experience of the rating surgeon.

## RESULTS

Otorhinolaryngologic departments with a residence-training program in the German-speaking part of Europe (Austria, Germany, Switzerland) were offered the opportunity to participate in evaluation of the infant TB model. Twenty-one departments showed an interest and they received the infant model, together with one adult TB model for comparison, and the questionnaire for evaluation.

Of the 21 departments, 15 (71%) provided evaluations by experienced surgeons. The examiners indicated an average experience of more than 200 mastoidectomies with two surgeons having performed less than 100, and more than 100 posterior tympanotomies with three examiners having performed less than 100. Only one of the participating departments did not provide cochlear implant surgery.

Table 1 shows an overview of the averaged questionnaire ratings. The overall ratings of the two models

**TABLE 1.** Overview of the averaged ratings of the 15 participating departments. Items of visual inspection (VI), drilling experience (DE), and landmarks (LM) were evaluated. Results are shown in 5-point scale, 1 is the lowest rating, 5 the highest

	Adult TB Model	Infant TB Model	Difference
Outer ear canal (VI)	4.27	4.47	-0.20
Tympanic membrane (VI)	4.00	4.13	-0.13
Cortical bone (DE)	4.13	4.43	-0.30
Mastoid cells (DE)	3.93	4.00	-0.07
Sigmoid sinus (LM)	4.07	4.20	-0.13
Diagastric ridge (LM)	3.83	3.77	0.06
Dura (LM)	4.33	4.13	0.20
Antrum (LM)	4.07	4.07	0.00
Semicircular canal (LM)	3.93	3.47	0.47
Incus (LM)	4.07	3.87	0.20
Posterior tympanotomy (DE)	3.53	3.86	-0.32
Facial nerve (LM)	3.93	3.67	0.27
Chorda tympani (LM)	3.73	3.62	0.12
Stapes and oval window (LM)	3.50	3.87	-0.37
Cochleostomy (DE)	3.54	3.83	-0.29
Round window (LM)	3.79	4.27	-0.48
Cochlear lumen (LM)	3.75	3.92	-0.17

were similar without significant differences in the Mann–Whitney  $U$  test. The ratings ranged either from 3–5 to 2–5 with the exceptions of the outer ear canal of the infant model (range, 4–5) and the round window of the adult model (range, 1–5). The average was 3.9 per item for the adult model and 3.96 for the infant model. The mastoid air cells, the antrum, and the digastric ridge were rated similarly for both the adult and infant models. Nine items were rated better in the infant model, and five in the adult model. The items with the lowest averaged ratings were the stapes and the oval window (3.5) in the adult model and the semicircular canal (3.47) in the infant model. The items with the highest averaged ratings were the dura (4.33) in the adult model and the outer ear canal (4.47) in the infant model.

The posterior tympanotomy together with stapes, oval window, cochleostomy, and round window were rated better in the infant TB model. The semicircular canal and the facial nerve were rated better in the adult TB model.

The ratings of the overall surgical experience and appraisal were higher with the adult model (4.1 and 4) than with the infant model (3.8 twice).

## DISCUSSION

We report an independent and multisite evaluation of a newly developed infant TB model that can help to improve training for pediatric otological surgery. In contrast to our previous evaluation of a similarly produced adult model (9), a comparison with the use of cadaveric TB was not possible because human cadaveric TB of infants or children are not available.

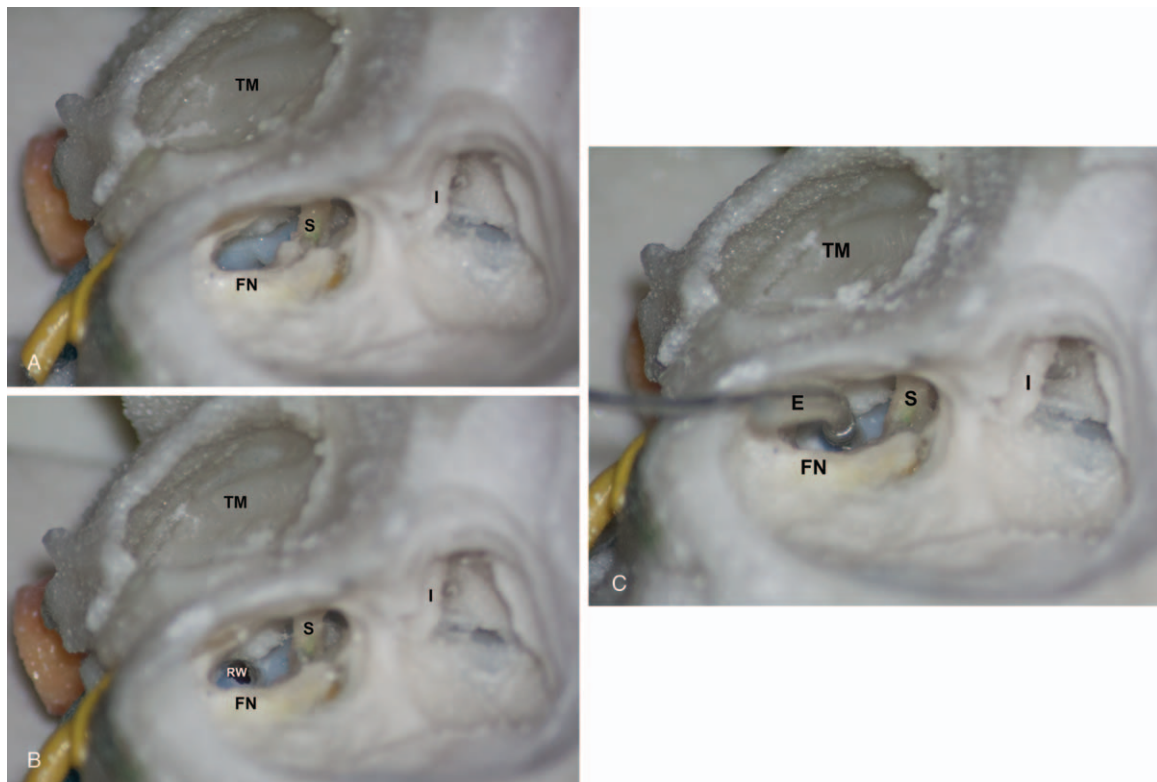
The rating of this new model by experienced surgeons indicated that the infant TB model has overall usefulness for surgical training comparable to the previously evaluated adult model. Some aspects of the infant TB model

were found to be more realistic than in the adult models, but others might not be as adequate. The posterior tympanotomy and the anatomical details (Fig. 2) related to this procedure were rated better in the infant than in the adult model. This may be an effect of having further developed the manufacturing process to pay particular care to these details. However, the more elaborate manufacturing process makes the infant TB model also more expensive than the adult model.

In contrast, the overall surgical experience and appraisal was rated lower in the infant model, possibly related to its clearly smaller dimensions, making the anatomical relations and the manufacturing process less precise. Despite the improved manufacturing process, the smaller bone dimensions may have led to less ideal representations of the semicircular canals and the facial nerve in the infant TB model.

Alternative means for training in infant TB surgery include the use of virtual reality models and office-based 3D printing. There is general agreement that computer-based virtual models (1,2,11) can be helpful, but also that they should not be used in isolation without appropriate models or cadaveric TB. The simulation of haptic feedback does not yet achieve sufficient closeness to reality.

The recent developments of office-based 3D printing offer several unique training options including individual patient-specific models. However, quite a few restrictions are remaining. Resolution of the models is limited by the resolution of clinical imaging and the use of micro-CT data is not possible. Another difficulty is the reproduction of air-containing spaces (12). Even though the present technique succeeded in reproducing reliably larger structures such as the cochlea or air cells, making the models adequate for training adult cortical mastoidectomy (13,14), smaller structures such as the semicircular canals or ossicles are reproduced much less accurate. They may



**FIG. 2.** View of the infant temporal bone model after performing a posterior tympanotomy and cochleostomy. (A) The incus (I), stapes suprastructure (S), tympanic membrane (TM), and facial nerve (FN) are visible, (B) opening of the cochlea anterior–inferior to the round window niche (RW) before, and (C) after insertion of an intra-cochlear electrode (E).

be easily broken when material is removed. Moreover, 3D printing alone generally does not allow easy modeling of relevant soft tissue parts such as the tympanic membrane or the facial nerve. These difficulties may presently limit the printing of pediatric TB models, but 3D printing undergoes dynamic technical development and more options and lesser costs may be expected.

The advantages of commercial artificial models such as described in this report include availability, ease of handling, and standardization allowing uniform specimens for instructional purposes in teaching. Other commercial adult models include the Pettigrew model (AM Pettigrew, Stirling, UK) or the Otobone model (Otobone, Sao Paulo, Brazil), both exhibiting soft tissue parts such as the tympanic membrane, similar to the model described in this report. Infant models are presently not available. Limitations of the PHACON infant TB model include the lack of mobile ossicles, and the obvious lack of intraoperative bleeding as in any other model and in cadaveric TB.

In conclusion, the evaluated infant TB model is similar to the established adult model from the same manufacturer for being helpful in surgical training. Both models are readily and commercially available. Since cadaveric TB of infants or small children are not available, the inclusion of infant TB models into surgical training may be more crucial.

## REFERENCES

1. Pirochchai P, Avery A, Laopaiboon M, et al. Virtual reality training for improving the skills needed for performing surgery of the ear, nose or throat. *Cochrane Database Syst Rev* 2015; CD010198.
2. Lui JT, Hoy MY. Evaluating the effect of virtual reality temporal bone simulation on mastoidectomy performance: a meta-analysis. *Otolaryngol Head Neck Surg* 2017;156:1018–24.
3. Mick PT, Arnoldner C, Mainprize JG, et al. Face validity study of an artificial temporal bone for simulation surgery. *Otol Neurotol* 2013;34:1305–10.
4. Awad Z, Ahmed S, Taghi AS, et al. Feasibility of a synthetic temporal bone for training in mastoidectomy: face, content, and concurrent validity. *Otol Neurotol* 2014;35:1813–8.
5. Chan S, Li P, Lee DH, et al. A virtual surgical environment for rehearsal of tympanomastoidectomy. *Stud Health Technol Inform* 2011;163:112–8.
6. Andersen SA, Caye-Thomasen P, Sorensen MS. Mastoidectomy performance assessment of virtual simulation training using final-product analysis. *Laryngoscope* 2015;125:431–5.
7. Rose AS, Webster CE, Harrysson OL, et al. Pre-operative simulation of pediatric mastoid surgery with 3D-printed temporal bone models. *Int J Pediatr Otorhinolaryngol* 2015;79:740–4.
8. Longfield EA, Brickman TM, Jeyakumar A. 3D printed pediatric temporal bone: a novel training model. *Otol Neurotol* 2015;36:793–5.
9. Roosli C, Sim JH, Mockel H, et al. An artificial temporal bone as a training tool for cochlear implantation. *Otol Neurotol* 2013;34:1048–51.
10. PHACON GmbH, Leipzig, Germany. Available at: <http://www.phacon-leipzig.de/index.php/en/home/80-phacon-english>. Accessed December 1, 2017.

11. Sorensen MS, Mosegaard J, Trier P. The visible ear simulator: a public PC application for GPU-accelerated haptic 3D simulation of ear surgery based on the visible ear data. *Otol Neurotol* 2009; 30:484–7.
12. Takahashi K, Morita Y, Ohshima S, et al. Creating an optimal 3D printed model for temporal bone dissection training. *Ann Otol Rhinol Laryngol* 2017;126:530–6.
13. Mowry SE, Jammal H, Myer Ct, et al. A novel temporal bone simulation model using 3D printing techniques. *Otol Neurotol* 2015;36:1562–5.
14. Bone TM, Mowry SE. Content validity of temporal bone models printed via inexpensive methods and materials. *Otol Neurotol* 2016;37:1183–8.