

An unexpected cause of pericardial effusion

JB Moses, BS,^a Ramon A. Brown, MD,^a Kristen H. Miller, MD,^b and Lawrence L. Creswell, MD,^a Jackson, Miss

We present a case of pericardial effusion due to embolization of a fragment of an inferior vena cava (IVC) filter, with subsequent perforation of the right ventricle. This is a rare and unexpected cause of pericardial effusion. Fracture or embolization of IVC filters is a relatively uncommon complication, but these events may have serious clinical implications. Although IVC filters are often placed with the intent of removal, the device in many patients is never removed. The long-term implications of IVC filter placement must be kept in mind when making decisions about device placement and subsequent removal. (*J Vasc Surg Cases* 2015;1:100-1.)

We report the case of a patient with pericardial effusion due to embolization of a fragment of an inferior vena cava (IVC) filter, with subsequent perforation of the right ventricle. This is a rare and unexpected cause of pericardial effusion. Fracture or embolization of IVC filters is a relatively uncommon complication, but these events may have serious clinical implications. The patient gave consent for publication of her data, including images and information that might reveal her identity.

CASE REPORT

A 68-year-old woman presented with chest pain and shortness of breath. The initial evaluation included a chest radiograph that was unremarkable, an electrocardiogram that showed ST segment elevation in the inferior leads, serum troponin levels that were within normal reference ranges, and an echocardiogram that showed moderate pericardial effusion, without hemodynamic significance. She was treated with oral steroids for presumed pericarditis, of uncertain etiology, with only modest relief.

On review, her medical history included a Whipple procedure for pancreatic cystadenoma approximately 16 months earlier at another institution. The early postoperative course was complicated by deep venous thrombosis in the left lower extremity that was treated by placement of a Meridian retrievable inferior vena cava (IVC) filter (Bard Peripheral Vascular, Tempe, Ariz). This filter was placed without difficulty using right internal jugular venous access. A completion venogram showed normal IVC anatomy, full expansion of the filter, and no caval thrombus.

An abdominal computed tomography (CT) scan 5 months after the IVC filter was placed demonstrated thrombus in the IVC, superior to the IVC filter. Systemic anticoagulation was

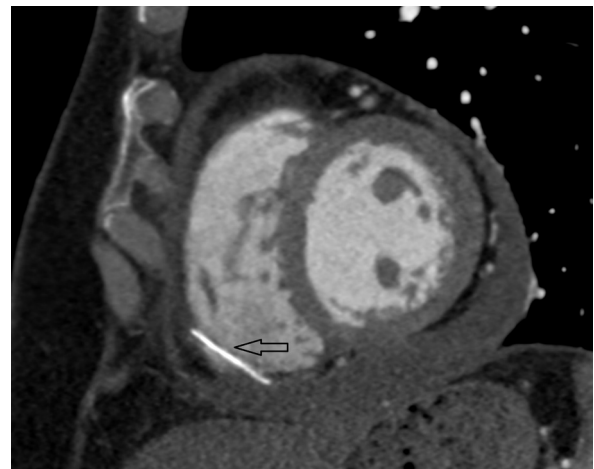


Fig 1. Cardiac computed tomographic angiography (CTA) with electrocardiograph-gating demonstrated an incidental $\sim 2.6\text{-cm} \times 0.2\text{-cm}$ metallic foreign body within the right ventricle apex (arrow), compatible with fractured and embolized inferior vena cava (IVC) filter strut. There is also an associated hemopericardium, which was thought to be due to subacute perforation of the ventricle.

initiated. An attempt to remove the IVC filter, again using right internal jugular venous access, was aborted. A venogram during that procedure demonstrated thrombus along the right caval wall, superior to the IVC filter and confirmed the previous CT findings. The IVC filter itself was not manipulated and was reported to be well positioned. Because of the potential risk of thrombus dislodgement, no further attempt was made to remove the filter. Systemic anticoagulation was continued.

Now, because of persistent chest discomfort, further evaluation included a chest CT that suggested hemopericardium and demonstrated a foreign body—a fragment of the IVC filter—in the right ventricle (Fig 1). On the basis of these findings, we planned an operation in a hybrid operating suite equipped with state-of-the-art biplanar imaging, where conventional sternotomy could be performed for exploration of the heart and pericardium, followed by percutaneous retrieval of the IVC filter and removal of any fragment(s) that could not be retrieved from the heart in an “open” fashion.

At operation, ~ 100 mL of bloody fluid was evacuated from the pericardium. The IVC filter fragment was protruding through

From the Departments of Surgery^a and Radiology,^b University of Mississippi Medical Center.

Author conflict of interest: none.

Reprint requests: Lawrence L. Creswell, MD, Division of Cardiothoracic Surgery, University of Mississippi Medical Center, 2500 N State St, Jackson, MS 39216 (e-mail: lcreswell@umc.edu).

The editors and reviewers of this article have no relevant financial relationships to disclose per the Journal policy that requires reviewers to decline review of any manuscript for which they may have a conflict of interest.

2352-667X

Copyright © 2015 The Authors. Published by Elsevier Inc. on behalf of the Society for Vascular Surgery. This is an open access article under the CC BY-NC-ND license (<http://creativecommons.org/licenses/by-nc-nd/4.0/>).

<http://dx.doi.org/10.1016/j.jvsc.2015.03.005>

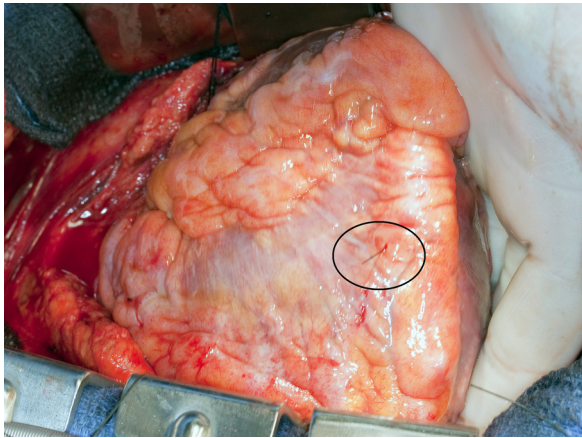


Fig 2. With exposure afforded by a standard sternotomy retractor, and after opening the pericardium, the apex of the heart was manually lifted from the pericardial sac. A small metallic fragment was protruding from the right ventricular free wall (within the circle), somewhat toward the apex. No active bleeding was noted.




Fig 3. The metallic fragment was removed manually from the right ventricle. There was no bleeding, and no suture repair of the ventricle was required.

the free wall of the right ventricle near the apex (Fig 2) and was removed (Fig 3). The remaining filter was removed percutaneously from its original position in the IVC, using right internal jugular venous access. An attempt at using the Recovery Cone (Bard Peripheral Vascular) was not successful because the tip of the filter had become endothelialized and could not be snared. Instead, a combination of Amplatz GooseNeck snare (Covidien, Plymouth, Minn) and Glidewire (Terumo Interventional Systems, Somerset, NJ) were used to pull the filter hook and proximal portion away

from the IVC wall, and a 12F sheath (Cook Medical, Bloomington, Ind) was advanced and used successfully to retrieve the filter.

DISCUSSION

A variety of complications related to IVC filter fracture or embolization, or both, have been reported.¹⁻⁴ The relative frequency of these complications is likely device-specific, but the incidence of strut fracture with embolization may be as high as 21% for some filters.² One report of scanning electron microscopy performed on IVC filters after removal, for the purpose of identifying metal fatigue, found 67% had evidence of microscopic fracture.² Reported sites of embolization have included the lung, liver, heart, pancreas, retroperitoneum, and other locations in the IVC, among others. Symptoms stem from perforation or thrombosis, but some embolization events may remain asymptomatic.

Although an IVC filter may be indicated to prevent thrombus migration to the lungs in patients who have a contraindication to anticoagulation, many patients are lost to follow-up and retrieval rates, even with dedicated tracking programs, may be <60%.³⁻⁶

CONCLUSIONS

With the known incidence of IVC filter fracture and embolization over time, together with missed follow-up and other reasons that prevent device removal, we should be thoughtful about the use of IVC filters as a solution to long-term thrombus and perhaps embolism control.

REFERENCES

1. Pontone G, Andreini D, Bertella E, Annon AD, Pepi M, Montorsi P. Asymptomatic struts fracture and multiple embolization as a late complication of ALN removable vena cava filter implantation. *Eur Heart J* 2013;34:2353.
2. Hull JE, Robertson SW. Bard recovery filter: evaluation and management of vena cava limb perforation, fracture, and migration. *J Vasc Interv Radiol* 2009;20:52-60.
3. Grande WJ, Trerotola SO, Reilly PM, Clark TW, Soulen MC, Patel A, et al. Experience with the recovery filter as a retrievable inferior vena cava filter. *J Vasc Interv Radiol* 2005;16:1189-93.
4. Kalva SP, Athanasoulis CA, Fan C, Curvelo M, Geller SC, Greenfield AJ, et al. "Recovery" vena cava filter: experience in 96 patients. *Cardiovasc Intervent Radiol* 2006;29:559-64.
5. Lynch FC. A method for following patients with retrievable inferior vena cava filters: results and lessons learned from the first 1,100 patients. *J Vasc Interv Radiol* 2011;22:1507-12.
6. Minocha J, Idakoji I, Riaz A, Karp J, Gupta R, Chrisman HB, et al. Improving inferior vena cava filter retrieval rates: impact of a dedicated inferior vena cava filter clinic. *J Vasc Interv Radiol* 2010;21:1847-51.

Submitted Dec 12, 2013; accepted Mar 1, 2015.