

## An unexpected surprise: Delayed gastric outlet obstruction from coin ingestion

Eric Omar Then,<sup>1</sup> Febin John,<sup>2</sup>  
Carmine Catalano,<sup>2</sup>  
Michell Lopez,<sup>1</sup>  
Vinaya Gaduputi<sup>1</sup>

<sup>1</sup>Division of Gastroenterology and Hepatology, SBH Health System, Bronx, New York; <sup>2</sup>Division of Gastroenterology and Hepatology, The Brooklyn Hospital Center, Clinical Affiliate of The Mount Sinai Hospital, Brooklyn, New York, U.S.A

### Abstract

Gastric outlet obstruction (GOO) is characterized by postprandial vomiting due to mechanical obstruction. Rarely it can occur due to ingestion of a foreign body. Most cases of foreign body ingestion are benign, with passage of the ingested object into the stool with no clinical sequelae. We describe a case of an 80-year-old woman with GOO occurring secondary to ingestion of two coins (American quarters). Rarely will such a small object cause a true gastric outlet obstruction. To our knowledge this makes the second such case reported in the medical literature.

### Introduction

Any intrinsic or extrinsic obstruction at the pylorus will result in gastric outlet obstruction (GOO). Its true prevalence has been difficult to estimate given the varied etiologies that may lead to GOO. Rarely does foreign body ingestion cause GOO because most foreign bodies traverse the gastrointestinal tract without causing obstruction. Cases of large bowel obstruction, although rare, have been reported in literature.<sup>1</sup>

### Case Report

An 80-year-old woman with a medical history significant for major depressive disorder, stroke, congestive heart failure, nephrolithiasis with indwelling nephrostomy tube presented to our institution from nursing home for nephrostomy tube replacement. The procedure was complicat-

ed with multiple episodes of vomiting and found to have a foreign body overlying stomach shadow on fluoroscopy (Figure 1). Patient was tolerating oral intake till the day of presentation. Due to concerns for aspiration pneumonia, the patient was transferred to our emergency department. Except for mildly elevated white blood cell count of  $10.8 \times 10^3/\text{UL}$ , rest of the laboratory workup was normal. Physical exam was remarkable for mild tenderness in the left lower quadrant of the abdomen. A recent computed tomography (CT) scan of the abdomen, showed a foreign body of the stomach (Figure 2). The patient was then transferred to the endoscopy suite to undergo esophagogastroduodenoscopy (EGD), which showed two coins (American quarters) obstructing the pylorus with underlying circular mucosal indentation and superficial non-bleeding ulceration. The pylorus was traversed and duodenum intubated after removal of the coins with a Roth net (Figure 3). During her stay in the hospital the patient tolerated oral diet and was safely discharged back to the nursing home.

### Discussion

The etiology of GOO has changed in the 21<sup>st</sup> century. Strictures due to gastric ulcers were the most common cause of GOO, however, since the dawn of H2 blockers and more so since the advent of proton pump inhibitors malignancy has taken its place as the most prevalent etiology.<sup>2</sup> Benign lesions such as Brunner gland adenomas have also been identified as rare etiologies.<sup>3</sup> Pyloric stenosis is a well-established entity that results in GOO in the pediatric population. Rarely will ingestion of a foreign body cause true GOO. Examples of foreign bodies causing GOO reported in the literature include ingestion of a lighter, a bottle cap and a bezoar of accumulated metallic objects.<sup>4-6</sup> GOO has also been reported in cases of cocaine body packing.<sup>7</sup> Only one other case of GOO however, to our knowledge, has occurred secondary to ingestion of a coin.<sup>8</sup>

Certain areas of the gastrointestinal tract become narrower than their adjacent counterparts, and as such are more susceptible to obstruction. In addition to the pylorus, the ingestion of foreign bodies may cause obstruction in other areas of the gastrointestinal tract. These include the upper esophageal sphincter, the lower esophageal sphincter, and the area where aortic arch crosses posteriorly to the mid esophagus.<sup>9</sup> In the lower gastrointestinal tract the ileocecal valve is the most common point of impaction followed by the hepatic and

Correspondence: Eric Omar Then, Division of Gastroenterology and Hepatology, SBH Health System, 4422 Third Ave, Bronx, New York 10457, U.S.A.  
Tel.: 917.544.9015.  
E-mail: ericomarthen27@yahoo.com

Key words: Gastric outlet obstruction; Esophagogastroduodenoscopy; Gastrointestinal tract.

Contributions: EOT, FJ and CC: involved in conception and design; EOT, FJ, CC and MLL: drafted the article; FJ and VG: critically revised the article for important intellectual content; EOT, FJ, CC, MLL and VG: involved in final approval of the article.

Conflict of interest: the authors declare no potential conflict of interest.

Funding: none.

Conference presentation: this case report was presented in the form of an abstract (poster) in the American College of Gastroenterology conference in Philadelphia, Pennsylvania (October 2018).

Received for publication: 28 March 2019.  
Accepted for publication: 3 May 2019.

This work is licensed under a Creative Commons Attribution NonCommercial 4.0 License (CC BY-NC 4.0).

©Copyright E.O. Then et al., 2019  
Licensee PAGEPress, Italy  
Clinics and Practice 2019; 9:1153  
doi:10.4081/cp.2019.1153

splenic flexures.<sup>10</sup> Symptoms of GOO are characterized by epigastric abdominal pain and post-prandial emesis. These symptoms occur secondary to an obstructed pylorus, which impedes forward flow of gastric contents. We postulate that probable manipulation of the patient for the nephrostomy tube replacement might have displaced the coins to the pyloric region causing GOO. Irrespective of location, once foreign body impaction is suspected, prompt evaluation with EGD is essential. EGD has the advantage of being both diagnostic and therapeutic in most cases of GOO.<sup>11</sup> Imaging studies such as X-ray or CT scan are also effective modalities that can be employed.<sup>9</sup> In our case initial evaluation took place with imaging studies, which allowed us to identify a metallic object, followed by prompt EGD, which allowed us to visualize the coin, and subsequently remove it.

Similar to our case, most cases of foreign body ingestion can be successfully treated through endoscopic removal. A

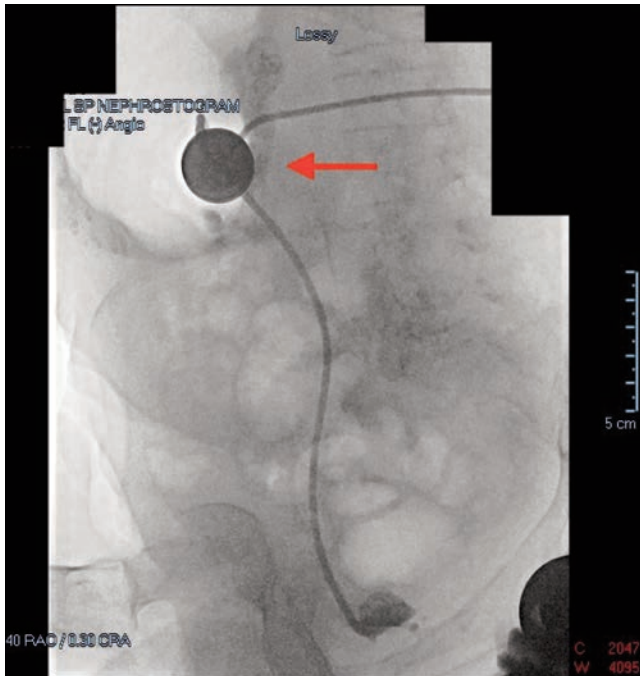


Figure 1. Fluoroscopy demonstrating a foreign body overlying the gastric shadow.

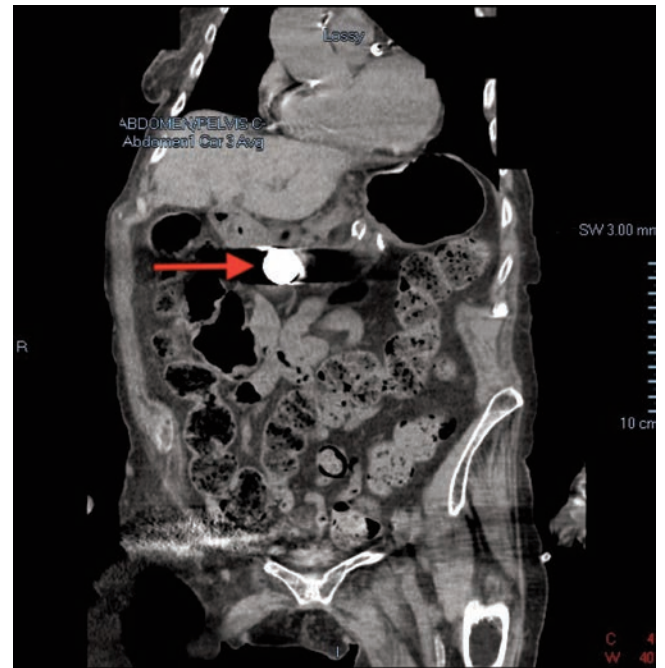


Figure 2. Computed tomography (coronal view) showing a foreign body within the stomach.

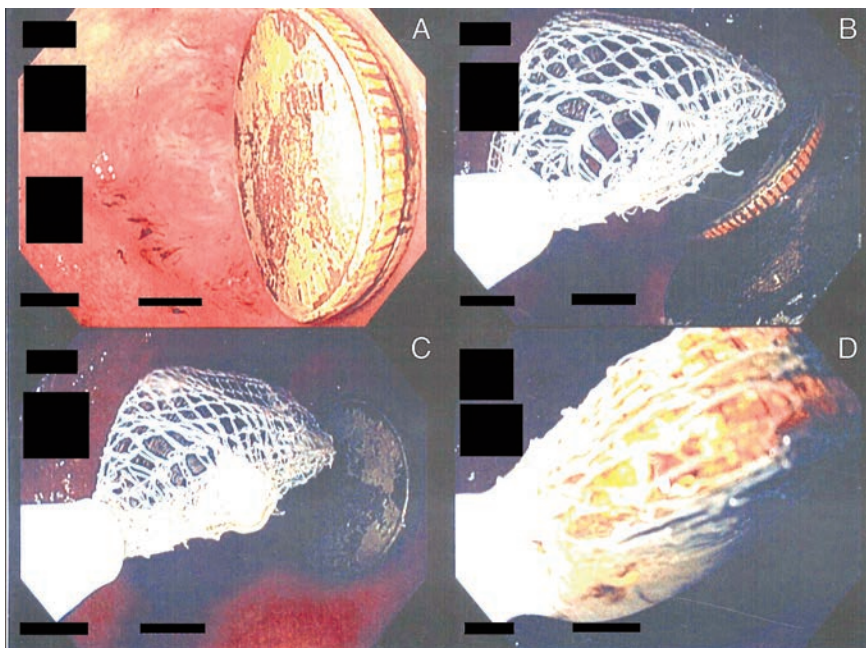


Figure 3. A) Esophagogastroduodenoscopy (EGD) showing two American quarters overlying the pylorus. B-D) EGD demonstrating removal of two American quarters via Roth net.

recent literature review compiled 120 cases of foreign body ingestion that support EGD as the treatment modality of choice in most instances.<sup>12</sup> In their review, 55 cases were treated by EGD, 37 cases required surgical intervention, and 16 cases were expelled spontaneously.

## Conclusions

In conclusion, foreign body ingestion is a rare cause of GOO as most cases traverse the gastrointestinal tract without causing symptoms. Once identified through imaging studies, prompt investigation should take place with EGD. We report a case of foreign body GOO that was successfully treated with endoscopic removal.

## References

1. Rezacova M, Pericleous S. Large bowel obstruction caused by a foreign body. *Surg Case Rep Rev* 2018 [In press].
2. Shone DN, Nikoomanesh P, Smith-Meek MM, Bender JS. Malignancy is the most common cause of gastric outlet obstruction in the era of H2 blockers. *Am J Gastroenterol* 1995;90:1769-70.
3. Balekuduru A, Sheik S, Prakash BS, Vilmann P. Gastric outlet obstruction - A rare cause. *Indian J Gastroenterol*

- 2016;35:150.
4. Aday U, Tardu A, Yagci MA, Yonder H. A rare cause of gastric obstruction: Lighters swallowing. *North Clin Istanb* 2015;2:239-42.
  5. Chang J, Fiatarone J. Education and imaging: gastrointestinal: gastric foreign body causing intermittent gastric outlet obstruction. *J Gastroenterol Hepatol* 2011;26:931.
  6. Chahine E, El Khoury L, Baghdady R, Chouillard E. Recurrent gastric metal bezoar: a rare cause of gastric outlet obstruction. *BMJ Case Rep* 2017;pii:bcr-2017-221928.
  7. Hantson P, Capron A, Maillart JF. Oesophageal and gastric obstruction in a cocaine body packer. *J Forensic Leg Med* 2014;27:62-4.
  8. Roth M, Cohen G. A quarter causing intermittent gastric outlet obstruction. *Gastrointest Endosc* 2012;75:189-90.
  9. Schaefer TJ, Trocinski D. Esophagus, foreign body. *StatPearls Treasure Island, FL: StatPearls Publishing; 2018. Available from: <https://www.ncbi.nlm.nih.gov/books/NBK482131/>.*
  10. Anderson KL, Dean AJ. Foreign bodies in the gastrointestinal tract and anorectal emergencies. *Emerg Med Clin North Am* 2011;29:369-400.
  11. Storm AC, Ryou M. Advances in the endoscopic management of gastric outflow disorders. *Curr Opin Gastroenterol* 2017;33:455-60.
  12. Tallón-Aguilar L, López-Ruiz JA, Marenco-De la Cuadra B, López-Pérez J. [Treatment for ingested foreign bodies]. *Emergencias* 2016;28:354-5.