


Use of Zipper Ratcheting Straps as a Bailout for Postoperative Cerebrospinal Fluid Leaks: Our Experience

Arvind G. Kulkarni, MS(Ortho)¹,
Sandeep Tapashetti, MS(Ortho), DNB(Ortho)¹ ,
and Priyank M. Patel, MS(Ortho)^{2,3,4}

Global Spine Journal
2020, Vol. 10(4) 443-447
© The Author(s) 2019
Article reuse guidelines:
sagepub.com/journals-permissions
DOI: 10.1177/2192568219860463
journals.sagepub.com/home/gsj



Abstract

Study Design: Technical note.

Objectives: Management of postoperative cerebrospinal fluid (CSF) leaks is a challenge. Reexploration increases the morbidity risks. The main objective was to evaluate the outcomes of noninvasive zipper-like system (Zip surgical skin closure system, ZipLine Medical, Inc, Campbell, CA, USA) as a bailout technique for postoperative CSF leaks.

Methods: Retrospective case series. Consecutive patients with postoperative CSF leaks that occurred secondary to spinal surgeries performed between January 2017 and September 2018 were part of the study. All these patients were managed conservatively by reinforcement with zipper ratcheting straps over the sutured surgical wound. Successful clinical outcomes included cessation of CSF leaks and adequate wound healing in the postoperative period and at follow-up.

Results: Ten patients underwent the application of zipper ratcheting straps. The mean follow-up was 6 months (range 6 months to 1 year). In 7 cases, the dural tears were recognized postoperatively and in 3 cases, the tears were noted intraoperatively and repaired and reinforced with fibrin sealants. None of the patients developed wound soakage or subsequent CSF leak from the wound after the application of zipper ratcheting straps.

Conclusions: Zipper ratcheting straps as augmentation to sewing of the wound seem to be a good alternative and bailout in treating patients with postoperative CSF leaks. The ease of its application, the ability in minimizing the complications associated with CSF leaks, and negating the need of surgical reexploration makes it a worthy option.

Keywords

occult dural tears, postoperative CSF leaks, zipper ratcheting straps, conservative management, spine surgery, cerebrospinal fluid leaks, durotomy, laminectomy, wound dehiscence

Introduction

The possible sequelae of unintended durotomy include the formation of a pseudomeningocele, a cerebrospinal fluid cutaneous fistula, arachnoiditis, meningitis, and deterioration in neurological status.¹⁻⁴ A cerebrospinal fluid (CSF) leak also predisposes the patient to poor wound healing and possible wound dehiscence.^{5,6} Incidental tear of the dural sac and CSF leak is generally recognized intraoperatively, but occult tears that present in a delayed manner are not uncommon.⁷ Management of CSF leaks that present postoperatively in spite of a well-attempted closure and reinforcement intraoperatively or the ones secondary to occult tears that go unrecognized intraoperatively still remains a challenge in view of limited options.

The purpose of this article is to present our experience using zipper ratcheting straps (Zip surgical skin closure system, ZipLine Medical, Inc, Campbell, CA, USA) in the

¹ Bombay Hospital and Medical Research Centre, Mumbai, Maharashtra, India

² Lilavati Hospital, Mumbai, Maharashtra, India

³ Jupiter Hospital, Mumbai, Maharashtra, India

⁴ Breach Candy Hospital, Mumbai, Maharashtra, India

Corresponding Author:

Arvind G. Kulkarni, Mumbai Spine Scoliosis and Disc Replacement Centre, Bombay Hospital and Medical Research Centre, Marine Lines, Mumbai 400020, Maharashtra, India.

Email: drarvindspines@gmail.com



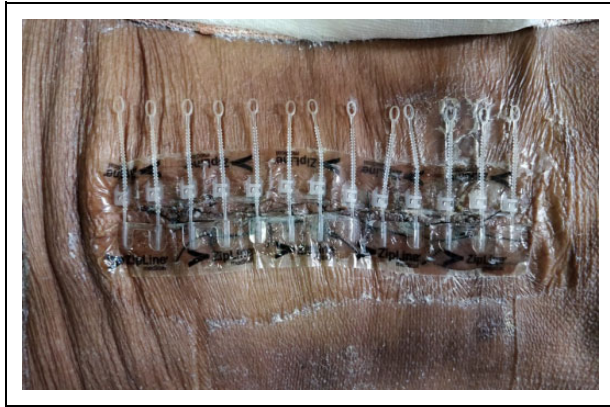

Figure 1. Appearance of the surgical wound after the application and approximation of zip dressing.

management of dural tears that persisted to leak postoperatively in spite of intraoperative recognition and repair as well as occult tears that started leaking in a delayed manner postoperatively.

Materials and Methods

This is a retrospective case series of consecutive patients with occult dural tears and postoperative CSF leaks that occurred secondary to spinal surgeries performed between January 2017 and September 2018 were part of the study. All these patients were managed conservatively by reinforcement with adhesive zipper ratcheting straps (Zip surgical skin closure system) dressing over the sutured surgical wound. Approval from institutional review board was obtained and written informed consent taken from patients for publication of images.

Technique and Protocol

Once the CSF leak is recognized in the postoperative period, the zip ratcheting strap dressing is applied on the primarily sutured surgical wound. It consists of 2 strips composed of a combination of hydrocolloid and acrylic adhesive, with each strip placed on either side of surgical incision (Figure 1). Once the adhesive strips are applied, the surgeon then approximates each side of the incision by pulling on a series of adjustable polyurethane ratcheting skirts that lock into position to maintain tension. As the surgeon proceeds to approximate the incision the effect is similar to closing a zipper. After application the surgical incision remains visible for wound monitoring.

Zipper ratcheting strap dressing was kept for 2 weeks and wound inspection was done on the 7th and 14th day postapplication. Patient was kept on restricted mobility for 1 week. Figure 2 shows completely healed surgical wound after 2 weeks.

Results

Ten patients underwent the application of zipper ratcheting straps. The mean age of patients was 55.10 years (range 15-76 years). Mean duration of surgery was 155 minutes (range

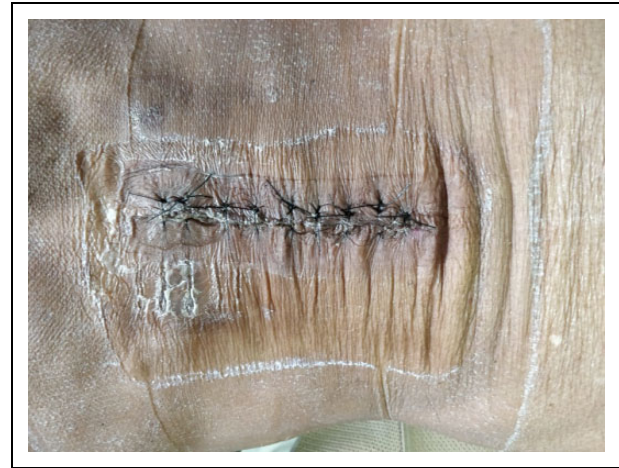

Figure 2. Completely healed surgical wound at the end of 2 weeks.

120-250 minutes), mean blood loss was 110 mL (range 50-500 mL) and mean drain volume was 210 mL (range 100-1100 mL). The mean follow-up was 6 months (range 6 months to 1 year). The distribution of leaks was 8 in primary and 2 in revision cases (Table 1). In 7 cases, the dural tears were recognized postoperatively, in 3 cases the tears were noted intraoperatively and repaired and reinforced with fibrin sealants (Table 1). All these patients were managed by reinforcement with ratcheting straps over the sutured surgical wound. None of our patients developed wound soakage or subsequent discharge from the wound after the application of zip system. MRI images of a patient at 8-month follow-up (Figures 3-5).

Discussion

Incidental durotomy is a relatively common complication of spinal surgeries with a reported incidence ranging from 3% to 17%, with many patients requiring repeat operation/s and extended time off from work.^{3,8-12} Reported risk factors for incurring a durotomy include older age, anatomic variation, thinning of dura due to chronic stenosis, relative inexperience of the surgeon, and revision surgery.^{11,13,14} CSF leaks can cause devastating complications such as CSF-cutaneous fistula, arachnoiditis, meningitis, and deterioration in neurological status with short- and long-term clinical sequelae.¹⁻⁴

Once CSF leak has been noticed intraoperatively, several methods have been used to repair dural tears, such as suturing the defect, application of fibrin glue, muscle and fat grafts, diversion drains, and bed rest.¹⁵⁻¹⁸ Management of persistent CSF leaks or leaks recognized postoperatively is challenging and is associated with increased morbidity and high costs.¹⁹ With the intention of reducing the potential morbidity associated with treatment of a postoperative CSF leak/fistula with reexploration and its attendant risks, other approaches currently in clinical use in the treatment of established CSF leakage include lumbar drain placement, the resuturing of skin, and image-guided placement of dural patches made of various materials (eg, fibrin, fat, or blood).²⁰⁻²²

Table 1. Demographics and Descriptive Characteristics of Study Cohort.

| Patient No. | Age (Years) | Sex | Diagnosis | Surgical Procedure | Tear Noted |
|-------------|-------------|--------|---|--|------------------|
| 1 | 68 | Male | L4-L5, L5-S1 LCS | Micro lumbar decompression | Postoperatively |
| 2 | 65 | Female | L3-L4, L4-L5 LCS with degenerative lumbar scoliosis | Decompression and fusion from L2-L5, L2-L3 PLF, TLIF at L3-L4, L4-L5 | Postoperatively |
| 3 | 48 | Female | L5-S1 lytic spondylolisthesis | L5-S1 TLIF with instrumentation | Postoperatively |
| 4 | 43 | Male | L4-L5 central HNP with stenosis | Microdiscectomy | Postoperatively |
| 5 | 63 | Female | L4-L5 LCS, L5-S1 iatrogenic spondylolisthesis | L4-L5 decompression and PLF, L5-S1 TLIF and fusion from L4-S1 | Postoperatively |
| 6 | 60 | Male | L5-S1 severe LCS | Micro lumbar decompression | Postoperatively |
| 7 | 76 | Male | L4-L5 recurrent HNP with instability with L5-S1 spondylolisthesis | L4-L5 TLIF, L5-S1 PLF and fusion from L4-S1 | Intraoperatively |
| 8 | 16 | Female | L1 hemivertebrae with thoracolumbar scoliosis | Deformity correction and fusion | Intraoperatively |
| 9 | 59 | Male | L4-L5 LCS, L5-S1 spondylolisthesis | L4-L5 decompression and PLF, L5-S1 TLIF, fusion from L4-S1 | Postoperatively |
| 10 | 53 | Male | L3-L4, L4-L5 LCS | Micro lumbar decompression | Intraoperatively |

Abbreviations: LCS, lumbar canal stenosis; HNP, herniated nucleus pulposus; TLIF, transforaminal lumbar interbody fusion; PLF, posterolateral fusion.

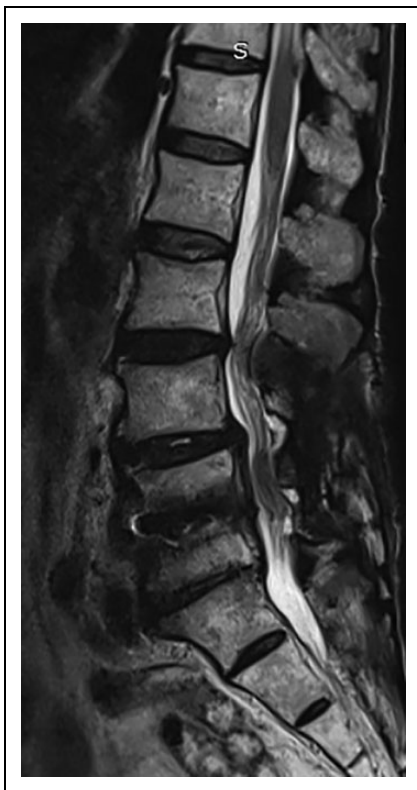

Figure 3. Mid-sagittal magnetic resonance image of patient at 8-month follow-up.

One such attempt in this direction of conservative management of patients with dural tears without neurological compromise is the use of zipper ratcheting straps. This zip dressing has been successfully used for skin closure in patients undergoing cardiac surgeries and knee arthroplasties.^{23,24} Zipper ratcheting strap (Zip surgical skin closure system) is a noninvasive, adjustable, coaptive, tape-based skin closure device (Figure 6). It is a

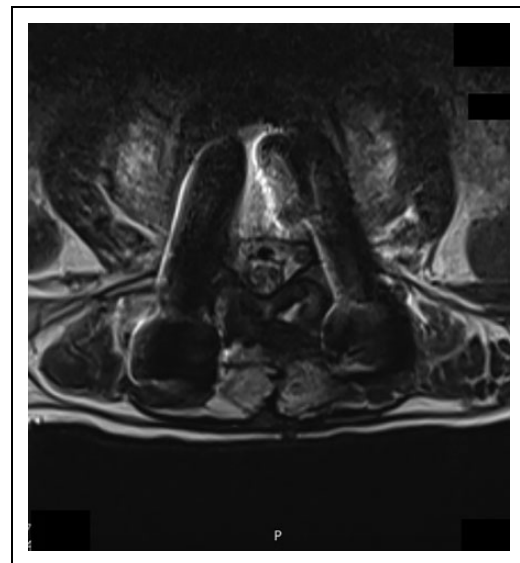

Figure 4. Axial magnetic resonance image of same patient at L4-L5 level.

sterile, hydrocolloid-based skin closure system designed to approximate skin edges and to maintain it during wound healing. The system consists of adjustable ratcheting straps with a force distribution system that maintain consistent tension along the incision edges. The ratcheting straps are adjusted in such a way that the wound is approximated with significant tension and this can be appreciated by overhanging of skin flaps. Another advantage of this device is the ability to adjust its length and tension. The length of the device can be easily adjusted by cutting the device at the appropriate point without the loss of tension. The tension of the device can be adjusted without limit because of the adapting strap-rock system. The tension of the device can be adjusted multiple times by pulling the straps according to the status of wound healing. In cases

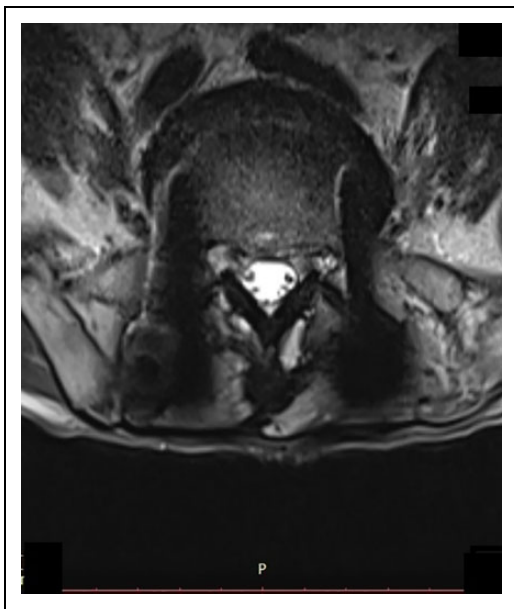


Figure 5. Axial magnetic resonance image of same patient at L5-S1 level.




Figure 6. Photo of the zipper dressing with adhesive strips on either side with adjustable ratcheting straps.

with postoperative leaks, the skin closure is reinforced with augmentation of the zip ratcheting strap system. The tension created across the line of the incision obliterates the dead space and creates a tamponade effect and discourages CSF collection by changing the pressure gradient. In none of the cases that we used the zip dressing did we encounter persistence of CSF leaks from the wound after initial application and appropriate tensioning of the zip surgical skin closure system. The application of the zip adhesive dressing was performed in the out-patient clinic in those situations when the CSF leaks were recognized after the patient was discharged. In situations where the leaks were identified immediately postoperatively during the admission, the adhesive was applied bedside and the patients were discharged in a day or two. The patients were given instructions and warned to revert immediately in case of any leak or headache. Since the procedure of application and removal of dressing could be

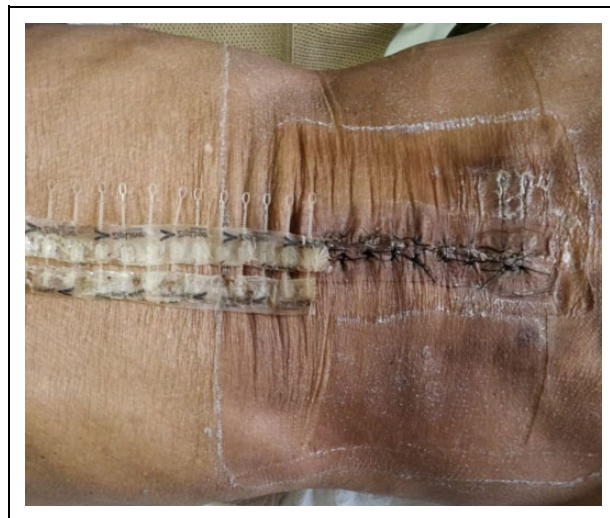

Figure 7. Clinical photograph showing the ease of removal of zip dressing in an outpatient clinic.

done without taking the patient inside the operating rooms, the costs incurred were limited to the expenditures of the adhesive (Figure 7). The zipper adhesive dressing is relatively inexpensive and is charged by length. The authors recommend the usage of zip dressing to bail out of postoperative CSF leaks with the added advantage of simplicity in application and reasonable costs.

Limitations of the Study

Retrospective case series with lack of control group is a major limitation of this study. Postoperative restricted mobility was followed on empirical basis because of lack of previous experience, maybe with more experience we can mobilize the patient early.

Conclusion

Use of zipper ratcheting straps as augmentation to sewing of the wound seems to be a good alternative and bailout in treating patients with postoperative CSF leaks and thus prevent complications like pseudomeningocele, CSF fistula and delayed wound healing. The superiority of this technique in reducing incidental durotomy related complications needs to be further elaborated in multicenter randomized controlled trials.

Authors' Note

The study is approved by institutional review board (approval vide BHIRB9890), Bombay Hospital and Medical Research Centre.


Declaration of Conflicting Interests

The author(s) declared no potential conflicts of interest with respect to the research, authorship, and/or publication of this article.

Funding

The author(s) received no financial support for the research, authorship, and/or publication of this article.

ORCID iD

Sandeep Tapashetti, MS(Ortho), DNB(Ortho)  <https://orcid.org/0000-0003-0705-3319>

References

- Koo J, Adamson R, Wagner FC Jr, Hrdy DB. A new cause of chronic meningitis: infected lumbar pseudomeningocele. *Am J Med.* 1989;86:103-104.
- Verner EF, Musher DM. Spinal epidural abscess. *Med Clin North Am.* 1985;69:375-384.
- Saxler G, Kramer J, Barden B, Kurt A, Pfortner J, Bernsmann K. The long-term clinical sequelae of incidental durotomy in lumbar disc surgery. *Spine (Phila Pa 1976).* 2005;30:2298-2302.
- Deyo RA, Mirza SK, Martin BI, Kreuter W, Goodman DC, Jarvik JG. Trends, major medical complications, and charges associated with surgery for lumbar spinal stenosis in older adults. *JAMA.* 2010;303:1259-1265.
- Bosacco SJ, Gardner MJ, Guille JT. Evaluation and treatment of dural tears in lumbar spine surgery: a review. *Clin Orthop Relat Res.* 2001;(389):238-247.
- Tosun B, Ilbay K, Kim MS, Selek O. Management of persistent cerebrospinal fluid leakage following thoraco-lumbar surgery. *Asian Spine J.* 2012;6:157-162.
- Khazim R, Dannawi Z, Spacey K, et al. Incidence and treatment of delayed symptoms of CSF leak following lumbar spinal surgery. *Eur Spine J.* 2015;24:2069-2076.
- Wang JC, Bohlman HH, Riew KD. Dural tears secondary to operations on the lumbar spine. Management and results after a two-year-minimum follow-up of eighty-eight patients. *J Bone Joint Surg Am.* 1998;80:1728-1732.
- Cammisa FP Jr, Girardi FP, Sangani PK, Parvataneni HK, Cadag S, Sandhu HS. Incidental durotomy in spine surgery. *Spine (Phila Pa 1976).* 2000;25:2663-2667.
- Jones AA, Stambough JL, Balderston RA, Rothman RH, Booth RE Jr. Long-term results of lumbar spine surgery complicated by unintended incidental durotomy. *Spine (Phila Pa 1976).* 1989;14:443-446.
- Khan MH, Rihn J, Steele G, et al. Postoperative management protocol for incidental dural tears during degenerative lumbar spine surgery: a review of 3183 consecutive degenerative lumbar cases. *Spine (Phila Pa 1976).* 2006;31:2609-2613.
- Guerin P, El Fegoun AB, Obeid I, et al. Incidental durotomy during spine surgery: incidence, management and complications. A retrospective review. *Injury.* 2012;43:397-401.
- Sin AH, Caldito G, Smith D, Rashidi M, Willis B, Nanda A. Predictive factors for dural tear and cerebrospinal fluid leakage in patients undergoing lumbar surgery. *J Neurosurg Spine.* 2006; 5:224-227.
- Hughes SA, Ozgur BM, German M, Taylor WR. Prolonged Jackson-Pratt drainage in the management of lumbar cerebrospinal fluid leaks. *Surg Neurol.* 2006;65:410-415.
- Mayfield FH, Kurokawa K. Watertight closure of spinal dura mater. Technical note. *J Neurosurg.* 1975;43:639-640.
- Pomeranz S, Constantini S, Umansky F. The use of fibrin sealant in cerebrospinal fluid leakage. *Neurochirurgia (Stuttg).* 1991;34:166-169.
- Papavero L, Engler N, Kothe R. Incidental durotomy in spine surgery: first aid in ten steps. *Eur Spine J.* 2015;24:2077-2084.
- Tafazal SI, Sell PJ. Incidental durotomy in lumbar spine surgery: incidence and management. *Eur Spine J.* 2005;14:287-290.
- Durand WM, DePasse JM, Kuris EO, Yang J, Daniels AH. Late-presenting dural tear: incidence, risk factors, and associated complications. *Spine J.* 2018;18:2043-2050.
- Black P. Cerebrospinal fluid leaks following spinal surgery: use of fat grafts for prevention and repair. Technical note. *J Neurosurg.* 2002;96(2 suppl):250-252.
- Elbiaadi-Aziz N, Benzon HT, Russell EJ, Mirkovic S. Cerebrospinal fluid leak treated by aspiration and epidural blood patch under computed tomography guidance. *Reg Anesth Pain Med.* 2001;26:363-367.
- Patel MR, Louie W, Rachlin J. Postoperative cerebrospinal fluid leaks of the lumbosacral spine: management with percutaneous fibrin glue. *AJNR Am J Neuroradiol.* 1996;17:495-500.
- Tanaka Y, Miyamoto T, Naito Y, Yoshitake S, Sasahara A, Miyaji K. Randomized study of a new noninvasive skin closure device for use after congenital heart operations. *Ann Thorac Surg.* 2016; 102:1368-1374.
- Carli AV, Spiro S, Barlow BT, Haas SB. Using a non-invasive secure skin closure following total knee arthroplasty leads to fewer wound complications and no patient home care visits compared to surgical staples. *Knee.* 2017;24:1221-1226.