Journal of Rural Medicine

Case report

Slow-growing venous malformation in a 92-year-old man, mimicking axillary lymphadenopathy

Hideo Tsuzuki[1], Hiroe Oishi[2], Atsushi Morishita[1, 3], Chizuko Uemura[4], Mitsuko Iguchi[5], and Tsutomu Shinohara[4, 6]

[1]*Department of General Surgery, Japan Agricultural Cooperatives Kochi Hospital, Japan*
[2]*Department of Clinical Laboratory, Japan Agricultural Cooperatives Kochi Hospital, Japan*
[3]*Department of Thoracic, Endocrine Surgery, and Oncology, Tokushima University Graduate School of Biomedical Sciences, Japan*
[4]*Department of Internal Medicine, Japan Agricultural Cooperatives Kochi Hospital, Japan*
[5]*Laboratory of Diagnostic Pathology, Kochi Medical School Hospital, Kochi University, Japan*
[6]*Department of Community Medicine for Respirology, Graduate School of Biomedical Sciences, Tokushima University, Japan*

Abstract

Objective: Venous malformations (VMs) are low-flow blood reservoir mass lesions with spongy or cystic venous lumens caused by dilation of the venous system vasculature. A VM is a congenital lesion that presents at birth and enlarges during childhood as the host grows. Subcutaneous lesions due to VMs are rarely diagnosed at an advanced age. We report a case of axillary VM in an older patient.

Patient: A 92-year-old man was suspected of having left axillary lymphadenopathy (single nodule, 23 mm long) on chest computed tomography (CT) scan. Seven years earlier, a chest CT scan showed a small, 13 mm nodule in the same area.

Results: On ultrasound elastography, the lesion did not appear hard, however, color Doppler imaging revealed abundant blood flow, suggesting a malignant lesion. Histologically, the lesions were consistent with VM.

Conclusion: VMs should be considered a differential diagnosis for superficial lymphadenopathy, even in older patients.

Key words: venous malformation, cavernous hemangioma, axillary lymphadenopathy, elastography, infantile hemangioma

(J Rural Med 2025; 20(4): 311–313)

Introduction

Venous malformations (VMs), including what used to be called "cavernous hemangioma", are low-flow blood reservoir mass lesions with a spongy or cystic venous lumens caused by dilation of the venous system vasculature. A thrombus or its organization can be observed in these venous lumens. The etiology of VMs relates to vascular endothelial cell hypoplasia or loss of smooth muscle in the vessel wall during embryonic vasculogenesis. VMs vary in size and occur anywhere in the body, most common in the head and neck region. A VM is a congenital lesion that presents at birth and enlarges during childhood as the host grows. Although the first symptoms of deeply seated lesions may occur in adulthood, subcutaneous lesions due to VMs are rarely diagnosed in older adults[1, 2].

Received: January 24, 2025
Accepted: May 2, 2025
Correspondence: Tsutomu Shinohara, Department of Community Medicine for Respirology, Graduate School of Biomedical Sciences, Tokushima University, 3-18-15 Kuramoto-cho, Tokushima-shi, Tokushima 770-8503, Japan
E-mail: t-shinohara@kouseiren.ja-kochi.or.jp

This is an open-access article distributed under the terms of the Creative Commons Attribution Non-Commercial No Derivatives (by-nc-nd) License <http://creativecommons.org/licenses/by-nc-nd/4.0/>.

Case Description

A 92-year-old man with a history of mild diabetes mellitus (DM) and chronic obstructive pulmonary disease was suspected to have left axillary lymphadenopathy (single nodule, 23 mm long) on chest computed tomography (CT) scan performed for close examination of an irregular opacity in the right lung apex (Figure 1A, 1B). The patient was aware of a slow-growing axillary lump for the past several years. Retrospectively, a chest CT scan performed seven

©2025 The Japanese Association of Rural Medicine

years earlier also showed a small, 13 mm nodule in the same area (Figure 1C). On ultrasonography, the lesion had an uneven shape with well-defined margins and low or isoechoic heterogeneous internal echoes accompanied by linear high echoes (Figure 1D). The lesion did not appear hard on elastography (Figure 1E). Color Doppler imaging revealed abundant internal blood flow, suggesting a malignant lesion (Figure 1F). Considering the risk of bleeding from needle

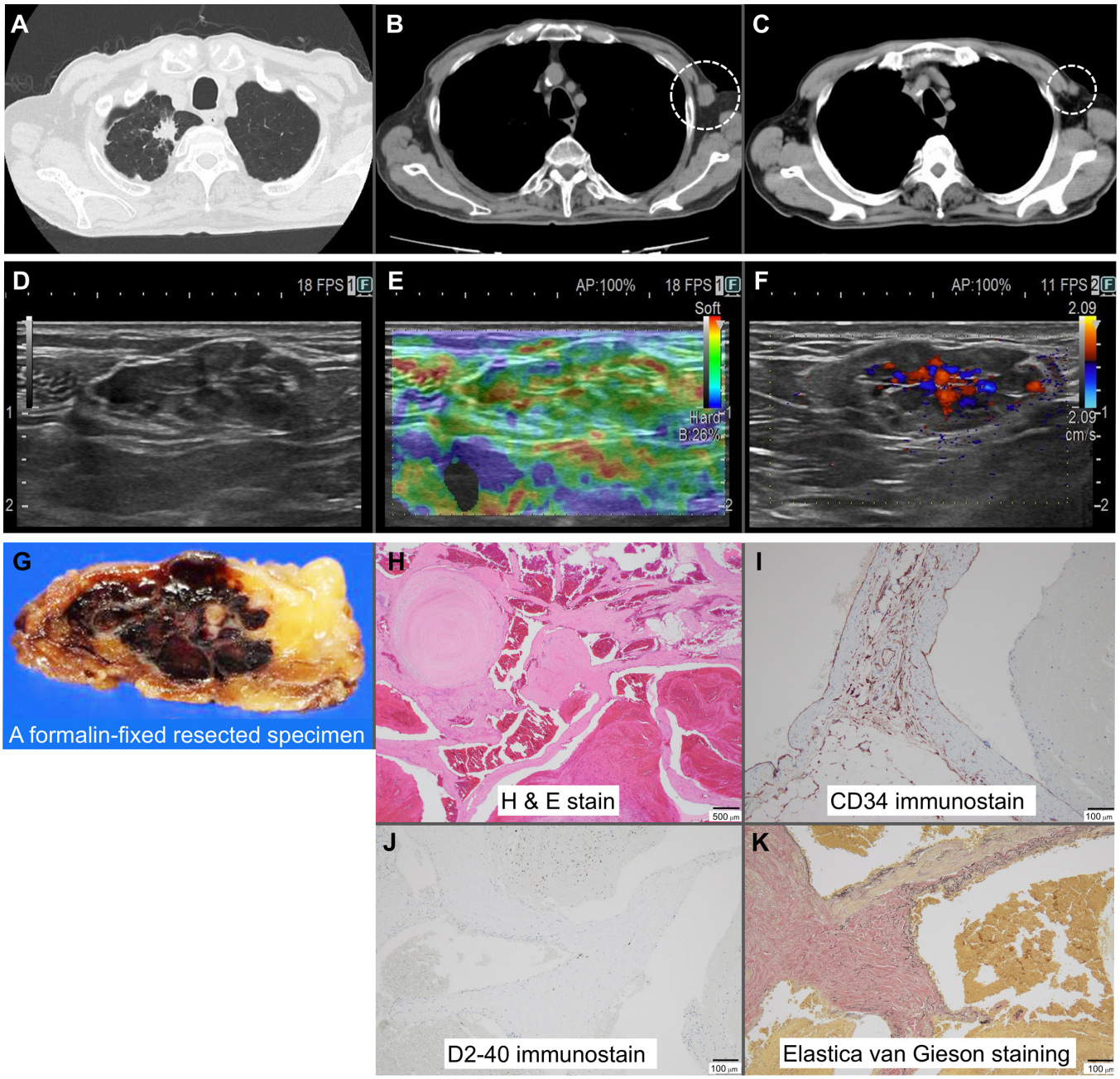

Figure 1 Chest CT images (A and B: at presentation, C: seven years earlier), axillary ultrasound findings (D: B-mode, E: elastography, F: color doppler) and pathological image of resected tissue (G: gross photographs of a formalin-fixed specimen, H: hematoxylin-eosin staining, I: CD34 immunostaining, J: D2-40 immunostaining, K: Elastica van Gieson staining). (A) An irregular opacity in the right lung apex. (B) A left axillary nodule, 23 mm long (circled). (C) A left axillary nodule, 13 mm long (circled). (D) The lesion was an uneven shape with well-defined margins and low or isoechoic heterogeneous internal echoes accompanied by linear high echoes. (E) Hard tissue is visualized in blue, intermediate tissue in green, and soft tissue in red. (F) Abundant internal blood flow. (G) A brown nodule in adipose tissue. (H) Dense aggregation of blood-filled dilated vascular vessels with walls of variable thickness and no endothelial atypia. Organizing thrombi were observed in some vascular lumens. (I) CD34-positive endothelial cells. (J) D2-40 negative endothelial cells. (K) A continuum of well-defined and poorly developed medial elastic fibers.

biopsy, the nodule was excised (Figure 1G). Histologically, the lesion was formed by a dense aggregation of blood-filled dilated vascular vessels with walls of variable thicknesses and did not contain lymphoid tissue. The vascular endothelium was flat without atypia. Immunohistochemically, the lesion was positive for CD34 and negative for D2-40, which is consistent with a blood-vascular origin. Organized thrombi were observed in some vascular lumens (Figure 1H–1J). Elastica van Gieson staining revealed a continuum of well-defined and poorly developed medial elastic fibers (Figure 1K). The final diagnosis was an axillary VM. The pulmonary lesion was accompanied by a small calcification that did not subsequently enlarge and was judged to be an old inflammatory change.

Discussion and Conclusion

The clinical course of VMs diagnosed at an extremely old age remains unclear. Factors that may enlarge VMs in older patients include increased venous pressure due to poor circulation, impaired venous valve function, progressive thrombus formation, and decreased venous elasticity. Additionally, VM may be exacerbated by comorbidities that cause vascular stress, such as DM (as was the case in this patient) or hypertension.

Elastography is a new ultrasound technique based on the understanding that when body tissues are compressed by a probe in the direction of the ultrasound wave, the distance between the tissues and the probe changes according to the stiffness of the tissues. The displacement of the tissues is calculated in relation to their surroundings, and the stiffness is usually visualized using color differences. Elastography has been used to evaluate breast lesions and lymphadenopathy. Ding *et al.* showed by elastography evaluation that VM is softer than deep-type infantile hemangioma, also known as "strawberry hemangioma", which is a vascular tumor caused by capillary endothelial cell proliferation[3]. Furthermore, Teusch *et al.* reported that elastography is useful for evaluating VMs before and after ethanol sclerotherapy[4].

Small axillary lesions are easily overlooked, and there have been reported cases in which large-sized VMs, including those in the axilla, led to repeated pulmonary emboli[5, 6]. The findings of this case report suggest that VMs should be considered a differential diagnosis for superficial lymphadenopathy, even in older patients.

Conflict of interest: The authors declare no competing interests.

Funding information: This case report received no specific grant from any funding agency in the public, commercial, or not-for-profit sectors.

Ethics approval: This study was conducted following the World Medical Association's Declaration of Helsinki. Based on the Japanese ethical guidelines, case reports do not need to be reviewed by the ethics board of our hospital.

Consent for publication: All authors approved the manuscript for publication in the Journal of Rural Medicine.

Patient consent: The patient provided written informed consent for publication of this case report and all accompanying images.

Data availability statement: All data generated or analyzed during this study are included in this article.

Author contributions: HT and TS designed the study, drafted the manuscript, and created the figure. HT, HO, AM, CU, and TS participated in the data collection and interpretation. MI contributed to the pathological assessment. All authors critically revised and approved the final manuscript.

References

1. Dompmartin A, Vikkula M, Boon LM. Venous malformation: update on aetiopathogenesis, diagnosis and management. Phlebology 2010; 25: 224–235. [Medline] [CrossRef]
2. International Society for the Study of Vascular Anomalies. ISSVA classification for vascular anomalies. http://www.issva.org/UserFiles/file/Classifications-2014-Final. pdf. Accessed August 28, 2024.
3. Ding A, Gong X, Li J, *et al*. Role of ultrasound in diagnosis and differential diagnosis of deep infantile hemangioma and venous malformation. J Vasc Surg Venous Lymphat Disord 2019; 7: 715–723. [Medline] [CrossRef]
4. Teusch VI, Piehler AP, Uller W, *et al*. Value of different ultrasound elastography techniques in patients with venous malformations prior to and after sclerotherapy. Clin Hemorheol Microcirc 2017; 66: 347–355. [Medline] [CrossRef]
5. Oduber CE, Gerdes VE, van der Horst CM, *et al*. Vascular malformations as underlying cause of chronic thromboembolism and pulmonary hypertension. J Plast Reconstr Aesthet Surg 2009; 62: 684–689, discussion 689. [Medline] [CrossRef]
6. Sontineni SP, Harper LK, Del Core M. Percutaneous deep vein stenting to prevent recurrent pulmonary thromboembolism from axillary venous malformation. Circulation 2010; 122: 642–643. [Medline] [CrossRef]