



## Prevalence of Untreated Canals and Their Association with Periapical Periodontitis Using Cone-beam Computed Tomography

Rayan Ebrahimi <sup>a</sup> , Samira Khajeh <sup>b</sup> , Hanieh Paik <sup>a</sup> , Masoud Moradi <sup>c</sup> , Mohammad Rastegar Khosravi <sup>d\*</sup>

<sup>a</sup> Dentist, Kurdistan University of Medical Sciences, Sanandaj, Iran; <sup>b</sup> Department of Oral and Maxillofacial Radiology, Faculty of Dentistry, Kurdistan University of Medical Sciences, Sanandaj, Iran; <sup>c</sup> Department of Research and Technology, Kurdistan University of Medical Sciences, Sanandaj, Iran; <sup>d</sup> Department of Endodontics, Faculty of Dentistry, Kurdistan University of Medical Sciences, Sanandaj, Iran

Article Type: Original Article

Received: 11 Jan 2024

Revised: 14 April 2024

Accepted: 10 May 2024

Doi: 10.22037/iej.v19i3.42440

\*Corresponding author:  
Mohammad Rastegar Khosravi, Department of Endodontics, Faculty of Dentistry, Kurdistan University of Medical Sciences, Sanandaj, Iran.

E-mail: mr.khosravi@muk.ac.ir

**Introduction:** Untreated canals represent the primary cause of treatment failure in molars and the second leading cause in other dental groups. This study determined the prevalence of untreated canals and their relationship with periapical periodontitis using cone-beam computed tomography (CBCT) images. **Materials and Methods:** 385 CBCT images with at least one treated canal were selected from the oral and maxillofacial radiology center. The number of roots and canals, presence, and size of periapical pathology, and presence of untreated canals were recorded. The study used descriptive statistics and Chi-square, Fisher's exact, and odds ratio tests to analyze data. **Results:** Of the 2053 teeth examined, 14.9% had at least one untreated canal. Untreated canals in teeth increase the chance of having a periapical lesion, raising the prevalence by 11 times. Of these, 91.8% had both untreated canals and periapical lesions. This was more than teeth without untreated canals (35.8%). Most untreated canals were in maxillary molars (65.3%), and mandibular molars (12.54%). There was a statistically significant relationship ( $P < 0.001$ ) between the number of roots, canals, expansion, destruction, and jaw type with the prevalence of untreated canals. The maxillary first molar (68.66%) and second mesiobuccal (MB2) canal (63.27%) had the highest percentages of untreated canals. **Conclusions:** The MB2 had the highest prevalence of untreated canals. The presence of untreated canals significantly increased the risk of expansion and/or destruction. Therefore, identifying these conditions can also be useful in diagnosing untreated canals. Dentists should assess the anatomy of the tooth and the structure of the root canal to minimize the possibility of an untreated canal. CBCT can assist in this process.

**Keywords:** Cone-beam Computed Tomography; Missed Canal; Periapical Periodontitis

### Introduction

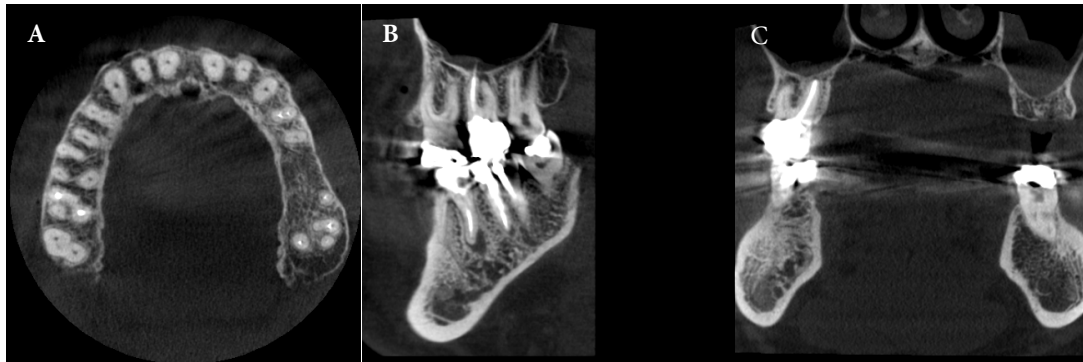
A clear understanding of the root canal anatomy is an essential prerequisite for achieving predictably successful endodontics [1]. The root canal anatomy is the blueprint upon which every clinician relies before initiating treatment [2]. Awareness of the internal anatomy reduces the possibility of missing a canal during treatment. Limited knowledge of root canal morphology and its complexity may result in a clinician missing a canal during root canal treatment [3]. An untreated canal is a major reason for the failure of endodontic treatment [4] and the subsequent endodontic retreatment can involve about 42% of untreated canals [5]. A missed canal can become a reservoir for microorganisms or cause persistent apical periodontitis [6]. Missed canals are the primary

cause of treatment failure in molars and the second leading cause of treatment failure in other dental groups. The signs and symptoms associated with unsuccessful endodontic treatment can range from none to acute apical abscess [7].

Diagnosing missed canals can be challenging because there is no definitive indication that is specifically related to a missed canal [3]. The presence of a missed canal in an endodontically treated tooth can be considered a clinical condition associated with the presence of apical periodontitis [5, 8].

Because periapical status is one indicator of success in endodontic treatment, its evaluation is important when monitoring the outcome of treatments [9]. Apical periodontitis is an inflammatory disease which is caused primarily by bacterial infection of the root canal system [4]. Persistence of apical





**Figure 1.** CBCT image of Tooth #15 with four canals that have not been treated with distobuccal and second mesiobuccal (MB2) canals; A) Axial view; B) Sagittal view; C) Coronal view (note the periapical lesion)

periodontitis can be induced by persistent bacterial infection, inadequate root filling, untreated canals, improper coronal restoration, and procedural errors [3].

The limitations of a two-dimensional radiographic image for displaying a three-dimensional structure are well-documented [10, 11]. Recently, cone-beam computed tomography (CBCT) with a limited field of view (FOV) and microCT images have been introduced to endodontics and their applications are increasing rapidly [11-13]. Accurate and reliable images obtained by CBCT provide higher sensitivity when detecting missed canals and assessing the quality of root canal treatment [14]. A tooth CBCT images always resulted in the identification of a greater number of root canals than conventional digital radiographic images [15]. The aim of the present study was to evaluate the prevalence of missed canals in endodontically treated teeth and their association with apical periodontitis in an Iranian subpopulation utilizing CBCT.

## Materials and Methods

### Sample collection and image qualification

CBCT images from patients who visited an oral and maxillofacial radiology service in Sanandaj, Iran, between December 2020 and March 2023 were retrieved from the database and analyzed. Patients were not exposed to radiation for this study. A total of 466 CBCT images were obtained using the Promax 3D system, specifically a Planmeca Finland 3D 8×8 cm CBCT unit (Helsinki, Finland), operating at 90 kVp, 8 mA, with a voxel size of 0.16 mm.

The inclusion criteria required the presence of at least one treated root canal in each CBCT image and patient age between 18 and 70 years. All tooth types were included. Exclusion criteria comprised low-quality images or those with artifacts, as well as previous endodontic surgery, root fracture, root perforation, or external root resorption that significantly altered root anatomy.

The sample size calculation formula confirmed that 385 CBCT images met the study's inclusion criteria.

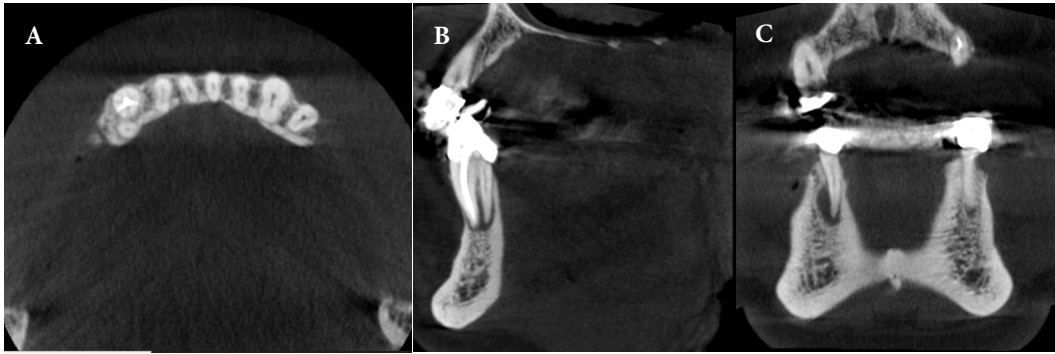
All images were independently examined by an experienced oral and maxillofacial radiologist and an endodontist to identify untreated canals and periapical periodontitis. The images were reviewed on the same monitor under consistent conditions, with the examiners blinded to each other's assessments. Observers could adjust image contrast and brightness, and there was no time restriction for the evaluations.

For each endodontically treated tooth, the following data were recorded: (1) tooth number (and the jaw in which it was located), and the frequency/number of its roots and canals; (2) presence or absence of periapical pathology; (3) dimensions of any periapical lesion; and (4) presence or absence of missed canals. All procedures adhered to international, national, and institutional ethical guidelines. The study received approval from the Ethics Committee at Kurdistan University of Medical Sciences (IR.MUK.REC.1400.030).

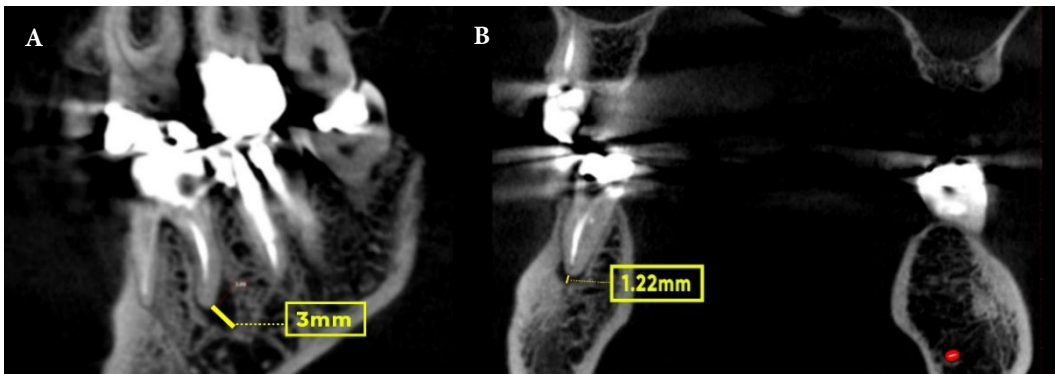
### Analysis of CBCT images

For interpretation, real-time reconstruction was performed using Romexis software (Romexis version 4.6.1; Planmeca, Helsinki, Finland), providing axial, coronal, and sagittal two-dimensional (2D) multi-planar reformatted slices. A tooth was considered endodontically treated if it contained at least one root canal filled with hyperdense material. Untreated (missed) canals were identified as those completely unfilled from the cemento-enamel junction to the apex or canals disrupted from the main canals at any point [12]. Initially, the axial sections of each root were evaluated for untreated canals and periapical lesions, with findings confirmed through analysis of the coronal and sagittal sections, as depicted in Figures 1 and 2.

A periapical lesion was recorded when, in addition to a disrupted lamina dura, a low-density area at least twice the width of the periodontal ligament was present [16]. The dimensions were measured perpendicular to the root surface in both the



**Figure 2.** CBCT image of tooth #27 with two roots with untreated lingual canal; A) Axial view; B) Sagittal view; C) Coronal view



**Figure 3.** CBCT image of the lower first molar tooth with periapical lesion at distal root; A) Sagittal view (The size of the lesion was measured to be 3 mm); B) Coronal view (The size of the lesion was measured to be 1.22 mm)

coronal and sagittal sections to identify the largest periapical lesion (Figure 3) [17]. The size classification of periapical pathology followed the CBCT periapical index (CBCT-PAI) as presented by Estrela *et al.*, and detailed in Table 1 [18]. This index utilizes a 6-point scoring system (0 to 5) with variables E (expansion) and D (destruction), where the score is determined by the largest lesion size. A score of zero indicates a healthy periapical bone structure without lesions.

Additional evaluations were conducted using multiplanar reconstructions in the axial, sagittal, and coronal sections. For multi-rooted teeth, each root was analyzed independently, with

the root having the worst score considered. The software allowed for image quality enhancement through filters and adjustments to brightness and contrast, facilitating a detailed and precise assessment.

#### Data analysis

Data analysis was performed using SPSS software (SPSS version 27; SPSS Inc., Chicago, IL, USA). Descriptive statistical methods were employed for summarizing data, including mean and standard deviation for quantitative variables and prevalence and relative prevalence for qualitative variables. To assess significant correlations within the data, Chi-square, Fisher's exact, and odds ratio tests were utilized. A *P*-value of less than 0.05 was considered statistically significant.

Intra- and interrater reliability tests were conducted to ensure the consistency and reliability of the observations. The Cohen Kappa test was applied to determine intra-rater reliability by analyzing the initial 10 CBCT scans (representing 300 teeth) twice (observations A and B) with a 1-month interval between assessments, and comparing the results. Additionally, interclass correlation coefficients were calculated for these same 300 teeth to determine interrater reliability across both observations A and B.

**Table 1.** Six point scoring system of CBCT-PAI index

Quantitative bone alterations in mineral structures	Score
Intact periapical bone structures	0
0.5 mm ≥ DPR* > 1 mm	1
1 mm ≥ DPR > 2 mm	2
2 mm ≥ DPR > 4 mm	3
4 mm ≥ DPR > 8 mm	4
Diameter of periapical radiolucency > 8 mm	5
Expansion of periapical cortical bone	Score: n+E*
Destruction of periapical cortical bone	Score: n+D*

DPR\*: Diameter of periapical radiolucency; E\*: Expansion; D\*: Destruction

## Results

Most measures demonstrated a high degree of reliability between the first and second replicates with the intraclass correlation coefficient (ICC) values (0.85) and Cohen's Kappa (0.83). Based on the inclusion and exclusion criteria, 385 CBCT radiographs with a total of 2053 teeth from all dental groups [anterior (26.45%), premolar (38.15%), and molar (35.40%)] were examined. Out of the population studied, 54.3% were women and 45.7% were men and the mean age of patients was  $41.95 \pm 12.42$  years. Of the teeth examined, 59.8% were in the maxilla and 40.2% were in the mandibular.

The second maxillary premolar had the highest prevalence (11.45%) in the studied samples and the lowest frequency was for the third maxillary and mandibular molars. Six anterior teeth in the maxilla, third maxillary, and third mandibular molars had no untreated canals.

The first maxillary molar had the most untreated canals (68.66%), followed by the second maxillary molar (61.94%) (Table 2). The second mandibular premolar (0.51%) had the fewest untreated canals, followed by the first maxillary premolar (2.33%). Most of the untreated canals, based on the dental group, were in the maxillary molars (65.3%), followed by the mandibular molars (12.54%), mandibular anterior teeth (8.14%), maxillary premolars (2.86%), and mandibular premolars (2.04%). Among the 2053 examined teeth, 14.9% had untreated canals and 44.1% had periapical lesions.

Of the teeth with untreated canals, 91.8% also had periapical lesions, while only 35.8% of the teeth with no untreated canals had periapical lesions. Therefore, the prevalence of periapical lesions in teeth with untreated canals was 11 times higher than for the teeth with no untreated canals. Among the untreated canals, second mesiobuccal (MB2) canal with 63.27% and mesio-lingual mandibular canals with 6.88% had the highest frequencies. MB2 of the first maxillary molar (62.21%) and MB2 of the second maxillary molar (43.28%) had the highest prevalence among the untreated canals.

The relationships between the number of roots, number of canals, and expansion, destruction, or type of jaw (maxilla or mandible) with the prevalence of untreated canals were statistically significant ( $P < 0.001$ ). A total of 79.7% of untreated canals occurred in the maxilla and only 20.3% occurred in the mandible. It is noteworthy that, for an untreated canal, the rate of expansion, destruction, or both increased significantly.

As shown in Table 3, as the number of roots and the number of canals increased, the number of untreated canals increased as well, such that the addition of a single unit to the number of roots led to a 2.03-fold increase in the number of untreated canals. Furthermore,

the addition of a single unit to the number of canals led to a 6.61-fold increase in the number of untreated canals. No statistically significant relationships ( $P < 0.001$ ) were recorded between age, sex, and lesion size with the prevalence of untreated canals.

## Discussion

Untreated canals are the main cause of treatment failure in molars and the second leading cause of treatment failure in other dental groups [5]. Signs and symptoms associated with unsuccessful endodontic treatment can range from no clinical signs to acute apical abscesses [7]. Diagnosing untreated canals can be challenging because there is no definitive indication that they may be specifically related to the condition of the untreated canal. The presence of an untreated canal in an endodontically treated tooth can be considered a clinical condition associated with the presence of apical periodontitis [5, 8]. Because the periapical status is an indicator of success in endodontic treatment, its evaluation is important to monitor the outcome of treatment.

The current study showed that the prevalence of untreated canals was 14.9% in the study population. Baruwa *et al.* [3] and Costa *et al.* [4] both reported that the prevalence of untreated canals was 12%, which is comparable with our results. However, Mashyakhly *et al.* [16] and Karabucak *et al.* [12] reported higher prevalence values for untreated canals of 18% and 23.04%, respectively. The study by Karabucak *et al.* only examined molars and premolars, which may explain the higher prevalence.

In the current study, the highest prevalence of untreated canals by the dental group was for maxillary molars (65.30%), followed by mandibular molars (12.54%), mandibular anterior teeth (8.14%), maxillary premolars (2.86%) and mandibular premolars (2.04%). The maxillary first molar (68.66%) and second mesiobuccal (MB2) canal (63.27%) had the highest percentages of untreated canals. Consistent with these results, Baruwa *et al.* [3] reported that the highest prevalence of untreated canals, by dental group, in their study was for maxillary molars (59.50% in the first maxillary molar and 40.00% in the second maxillary molar teeth). They also stated that the lowest prevalence of untreated canals was in the maxillary anterior teeth (0.5%) and premolars (2.4%). Moreover, it has been reported that maxillary molars have the highest percentage of root canal treatment failure with the presence of periapical radiolucency due to missed canal [5, 19]. Karabucak *et al.* [20] also reported that maxillary molars showed the highest prevalence of untreated canals (40.1%), of which the first maxillary molar tooth (43.9%) and MB2 canal (65%) had the highest prevalence of untreated canals.

**Table 2.** Distribution of missed canals with or without lesions by location of tooth

Tooth number-the jaw in which it is located	Frequency of the tooth	Frequency of the tooth with lesion	Incidence of missed canal per tooth (%)	Frequency of missed canal with lesion	Frequency of missed canal without lesion
8 Max	2	2	0	0	0
7 Max	134	101	61.94 (83)	78	5
6 Max	217	170	68.66 (149)	134	15
5 Max	235	82	3.40 (8)	8	0
4 Max	214	62	2.33 (5)	5	0
3 Max	150	55	0	0	0
2 Max	139	42	0	0	0
1 Max	140	47	0	0	0
8 Man	8	4	0	0	0
7 Man	153	79	12.41 (19)	18	1
6 Man	213	122	12.67 (27)	23	4
5 Man	194	45	0.5 (1)	1	0
4 Man	140	38	3.57 (5)	5	0
3 Man	62	23	3.22 (2)	2	0
2 Man	30	17	16.66 (5)	5	0
1 Man	22	10	4.54 (1)	1	0
<b>Total</b>	<b>2053</b>	<b>906</b>	<b>14.9 (305)</b>	<b>280</b>	<b>25</b>

Max: Maxilla; Man: Mandible

**Table 3.** Prevalence and distribution of untreated canals in maxilla [n (%)]

Tooth	2nd molar	1st molar	2nd premolar	1st premolar
MB2	58 (43.28)	135 (62.21)	0	0
MB1	6 (4.47)	0	2 (0.85)	0
DB	8 (5.97)	4 (1.84)	0	0
P	0	0	4 (1.70)	3 (1.40)
B	0	0	2 (0.85)	1 (0.47)
P2	0	1 (0.46)	0	0
MB2+MB1	3 (2.24)	3 (1.38)	0	0
MB2+DB	8 (5.97)	3 (1.38)	0	0
MB2+MB1+DB	0	3 (1.38)	0	0
DB+P	0	0	0	1 (0.47)
<b>Total</b>	<b>134 (100)</b>	<b>217 (100)</b>	<b>235 (100)</b>	<b>214 (100)</b>

MB, Mesio Buccal; DB, Distobuccal; P, Palatal; B; Buccal

**Table 4.** Prevalence and distribution of untreated canals in mandible [n (%)]

Tooth	2nd molar	1st molar	2nd premolar	1st premolar	Canine	2nd incisor	1st incisor
Canal							
ML	14 (9.15)	7 (3.29)	0	0	0	0	0
MB	2 (1.30)	6 (2.81)	0	0	0	0	0
DB	0	2 (0.94)	0	0	0	0	0
DL	0	10 (4.70)	0	0	0	0	0
D	1 (0.65)	0	0	0	0	0	0
B	0	0	0	0	0	1 (3.33)	0
L	0	0	1 (0.51)	3 (2.14)	2 (3.22)	4 (13.33)	1 (4.54)
ML+D	1 (0.65)	0	0	0	0	0	0
MB+ML	1 (0.65)	2 (0.94)	0	0	0	0	0
DB+L	0	0	0	2 (1.43)	0	0	0
<b>Total</b>	<b>153 (100)</b>	<b>213 (100)</b>	<b>194 (100)</b>	<b>140 (100)</b>	<b>62 (100)</b>	<b>30 (100)</b>	<b>22 (100)</b>

ML: Mesiolingual; MB: Mesio Buccal; DB: Distobuccal; DL: Distolingual; D: Distal; B: Buccal; L: Lingual



Many other studies have reported results that were relatively similar to ours [4, 5, 7, 16]. Taken together, these studies confirm that the prevalence of untreated canals and their positions were similar in the studied population. These results and their consistency with previous studies also highlight the importance of the role of untreated canals in the development of periapical lesions.

Anatomical studies of the first maxillary molar have shown that the prevalence of MB2 is 30.9% to 96.7% [21, 22]. Mesiobuccal root anatomy can be variable and complex, which may make it difficult for clinicians to identify and treat all canals during the treatment [23, 24]. These findings emphasize that care should be taken when determining the number of maxillary molar canals during treatment/retreatment. Mesiobuccal roots typically have two canals and clinicians must strive to locate the MB2 canal [16, 25].

The reason for missing MB2 canals is likely a lack of skill by the clinicians, inadequate training of dentists, indirect access, morphological complexity [10, 12] (type II (69.1%) and type IV (48.7%) Vertucci's configurations [26]), and uncertainty of the orifices of the canal [11]. Accordingly, determining the most appropriate solutions to addressing such insufficiencies should be taken more seriously.

In the present study, the highest prevalence of untreated canals in the mandible, by the dental group, was related to the mandibular molars (12.54%) (12.67% in the first molar and 12.41% in the second molar). Baruwa *et al.* [3] reported that the first mandibular molar (11.2%) and the second mandibular molar (9.5%) had the highest frequencies of untreated canals in the mandible. Mashyakhly *et al.* [16] reported that the total number of untreated canals in the mandible was for the first molar (25% of all untreated canals) and that the mesiobuccal and mesiolingual (ML) canals were those most often left untreated.

The present study also showed that the mesial root of the second mandibular molar had the highest rate of untreated canals in the mandible at 5.24%. Baruwa *et al.* [3] also reported that the mesial root of the second molar had the highest rate of untreated canals (9.6%) in the mandible. Karabucak *et al.* [20] reported that the mesial root of the second molar had the highest rate of untreated mandibular canals.

In the present study, the ML canal of mandibular molars (25.92% in the first molar and 73.68% in the second molar) had the highest prevalence of the untreated canal (Table 4). This was consistent with the study by Costa *et al.* (29% in the first molar and 62% in the second molar) [4].

These missed canals could be due to reduced visibility and access to the pulp chamber of the second molar, indirect visibility of the orifice of the mesial canals, and anatomical complexities of this root [3, 4, 12]. Accordingly, treatment of these canals requires greater skill and effort. In addition, in the mandibular second molars, the high prevalence of Vertucci type I classifications and the fact that both

mesial canals have a common orifice are other possible explanations for the high rate of untreated canals in this tooth [3].

The current study showed that the overall prevalence of periapical lesions was 44.1%. Importantly, 91.8% of the teeth with untreated canals had periapical lesions, while the prevalence of periapical lesions in teeth without untreated canals was 35.8%. Therefore, the prevalence of periapical lesions in teeth with untreated canals was 11 times higher than for the teeth with no untreated canals. In Karabucak *et al.*'s study, 82.8% of cases, in Costa *et al.*'s study, 98% of cases, in Baruwa *et al.*'s study, 82.6% of cases, and in Do Carmo *et al.*'s study, 45.2% of cases simultaneously have Missing canal and peri-apical lesions, therefore, according to these studies, teeth with untreated canals are 4.38, 6.25, 4.4 and 2.57 times more exposed to peri-apical lesions [3, 5, 12], respectively, which was less than the present study.

Indeed, untreated canals can become a reservoir for microorganisms, which is a main cause of stable periapical periodontitis [27].

The results of the current study show that the number of roots and the number of canals affected the prevalence of untreated canals such that the addition of a single unit to the number of roots led to a 2.03-fold increase in the number of untreated canals. Furthermore, the addition of a single unit to the number of canals led to a 6.61-fold increase in the number of untreated canals. These results also indicate that the presence of untreated canals significantly increased the risk of expansion and/or destruction. Therefore, identifying these conditions (expansion and destruction) can also be useful in diagnosing untreated canals. Comparative studies of CBCT scans and conventional radiographs in the diagnosis of apical periodontitis showed that CBCT could be much more accurate for diagnosing small lesions with minimal destruction levels [18, 28, 29].

Periapical radiography has long been the most common imaging technique for the evaluation of errors in endodontic treatment and periapical lesion [30]. However, the increased use of CBCT has led to comparisons of its performance with conventional radiographs for the diagnosis of endodontic disease [31-33]. CBCT has made it possible to detect periapical radiolucencies before they can be detected on conventional radiographs [28]. Lofthag-Hansen *et al.* [34] showed that the diagnostic power of CBCT was 38% higher than conventional radiographs for detecting the periapical lesions in the roots of teeth suspected of having periapical lesions. Similar findings have been reported in other studies [35].

In the present study, as in Torabinejad *et al.* [36], the modified CBCT-PAI method was used to measure a lesion in the manner recommended by Estrela *et al.* [18] These measurements have been defined based on the largest extent of the lesion. However, this method could not be accurately used with the linear

measurement by CBCT software, and different dimensions could have been recorded each time as the measurements were not performed from a fixed reference point.

Accordingly, a lack of clarity in the definition of Estrela *et al.* [18] made it difficult to obtain reproducible and comparable measurements for longitudinal or cross-sectional studies of periapical radiolucency. Therefore, linear measurements were performed perpendicular to the root surface such that the largest size of the periapical lesion was obtained. In this way, the measurements were reproducible and comparable. The 6-point scoring index provided by Estrela *et al.* [18] continued to be used to classify the lesion dimensions (Table 4). Because it was not clear to what extent radiolucency in CBCT is indicative of disease, clinical signs from patients with untreated canals and periapical lesions should be considered before deciding on retreatment [37]. In the present study, no statistically significant relationship was observed between the size of the lesion and the prevalence of untreated canals. Nevertheless, it is important to know that the size of the lesion can be affected by the time that has passed from root canal treatment and detection of an untreated canal.

The main limitation of this study was its cross-sectional nature. Cross-sectional studies are those in which information is systematically collected from a specific population at a given time to describe the prevalence of a condition and to link it to etiological and pathogenic factors [20]. Because the CBCT scans were evaluated at a specific time, no information was available on the length of time from the initial root canal treatment. It is important to acknowledge that some lesions might have healed, become larger, or formed over time [3, 4]. The study also lacked histological and microbiological studies to confirm the association between an untreated canal and a periapical lesion. Despite these limitations, such studies are easy and inexpensive, can have a large sample size, and are generally less prone to bias than longitudinal studies [38].

## Conclusion

The findings of the current study showed that the MB2 canal had the highest prevalence of untreated canals. An untreated root canal should be considered as an important factor in the development and spread of periapical lesions. Therefore, before starting endodontic treatment, the dentist should be aware of the anatomy of the tooth, the structure of the root canal, and its possible variations to minimize the possibility of an untreated canal. The findings also indicate that CBCT offers a high ability to detect and locate untreated canals. Thus, for suspected cases of untreated canals, it is recommended that CBCT be employed before retreatment.

## Acknowledgements

This study was supported by dental research center of Kurdistan University of Medical Science.

## Conflict of interest

None.

## Funding support

The study was funded by Kurdistan University of Medical Sciences. Grant number is 1804047003.

## Author contributions

Rayan Ebrahimi and Mohammad Rastegar Khosravi designed the study. All images were examined by Mohammad Rastegar Khosravi and Samira Khajeh. Rayan Ebrahimi and Hanieh Paik collected the data. Masoud Moradi conducted the statistical analysis. Rayan Ebrahimi and Mohammad Rastegar Khosravi wrote the first draft of the manuscript and all authors contributed to and have approved the final manuscript.

## References

1. Beyraghshamshir R, Karimian E, Sekandari S. Maxillary Premolars with Three Root Canals: A Case Report. *Iran Endod J.* 2020;15(4):259-62.
2. Albuquerque D, Kottoor J, Hammo M. Endodontic and clinical considerations in the management of variable anatomy in mandibular premolars: a literature review. *Biomed Res Int.* 2014;2014.
3. Baruwaa AO, Martins JN, Meirinhos J, Pereira B, Gouveia J, Quaresma SA, Monroe A, Ginjeira A. The influence of missed canals on the prevalence of periapical lesions in endodontically treated teeth: a cross-sectional study. *J Endod.* 2020;46(1):34-9. e1.
4. Costa F, Pacheco-Yanes J, Siqueira Jr J, Oliveira A, Gazzaneo I, Amorim C, Santos P, Alves F. Association between missed canals and apical periodontitis. *Int Endod J.* 2019;52(4):400-6.
5. do Carmo WD, Verner FS, Aguiar LM, Visconti MA, Ferreira MD, Lacerda MFLS, Junqueira RB. Missed canals in endodontically treated maxillary molars of a Brazilian subpopulation: prevalence and association with periapical lesion using cone-beam computed tomography. *Clin Oral Investig.* 2021;25:2317-23.
6. Alotaibi BB, Khan KI, Javed MQ, Dutta SD, Shaikh SS, Almutairi NM. Relationship between apical periodontitis and missed canals in mesio-buccal roots of maxillary molars: CBCT study. *J Taibah Univ Med Sci.* 2024;19(1):18-27.
7. Huuonen S, Kvist T, Gröndahl K, Molander A. Diagnostic value of computed tomography in re-treatment of root fillings in maxillary molars. *Int Endod J.* 2006;39(10):827-33.
8. Bóveda C, Kishen A. The Role of Modern Technologies for Dentin Preservation in Root Canal Treatment. *Minimally Invasive Approaches in Endodontic Practice.* 2021:1-32.
9. Alharmoodi R, Al-Salehi S. Assessment of the quality of endodontic re-treatment and changes in periapical status on a postgraduate endodontic clinic. *J Dent.* 2020;92:103261.
10. Nascimento EHL, Gaêta-Araujo H, Andrade MFS, Freitas DQ.

- Prevalence of technical errors and periapical lesions in a sample of endodontically treated teeth: a CBCT analysis. *Clin Oral Investig*. 2018;22:2495-503.
11. Naseri M, Safi Y, Akbarzadeh Baghban A, Khayat A, Eftekhar L. Survey of Anatomy and Root Canal Morphology of Maxillary First Molars Regarding Age and Gender in an Iranian Population Using Cone-Beam Computed Tomography. *Iran Endod J*. 2016;11(4):298-303.
  12. Karabucak B, Bunes A, Chehoud C, Kohli MR, Setzer F. Prevalence of apical periodontitis in endodontically treated premolars and molars with untreated canal: a cone-beam computed tomography study. *J Endod*. 2016;42(4):538-41.
  13. Mohammadzadeh Akhlaghi N, Khalilak Z, Vatanpour M, Mohammadi S, Pirmoradi S, Fazlyab M, Safavi K. Root Canal Anatomy and Morphology of Mandibular First Molars in a Selected Iranian Population: An In Vitro Study. *Iran Endod J*. 2017;12(1):87-91.
  14. Falakaloglu S, Belgin CA, Uygun LA, Adigüzel Ö. Assessment of apical periodontitis in relation to quality of root canal fillings and coronal restorations in a Turkish subpopulation: A retrospective cone-beam computed tomography study. *Saudi Endod J*. 2020;10(2):121.
  15. Mohammadi Z, Asgary S, Shalavi S, P VA. A Clinical Update on the Different Methods to Decrease the Occurrence of Missed Root Canals. *Iran Endod J*. 2016;11(3):208-13.
  16. Mashyakhly M, Hadi FA, Alhazmi HA, Alfaifi RA, Alabsi FS, Bajawi H, Alkahtany M, AbuMelha A. Prevalence of missed canals and their association with apical periodontitis in posterior endodontically treated teeth: a CBCT study. *Int J Dent*. 2021;2021.
  17. Torabinejad M, Rice DD, Maktabi O, Oyoyo U, Abramovitch K. Prevalence and size of periapical radiolucencies using cone-beam computed tomography in teeth without apparent intraoral radiographic lesions: a new periapical index with a clinical recommendation. *J Endod*. 2018;44(3):389-94.
  18. Estrela C, Bueno MR, Azevedo BC, Azevedo JR, Pécora JD. A new periapical index based on cone beam computed tomography. *J Endod*. 2008;34(11):1325-31.
  19. Parirokh M, Manochefrifar H, Kakooei S, Nakhaei N, Abbott P. Variables That Affect the Ability to Find the Second Mesio Buccal Root Canals in Maxillary Molars. *Iran Endod J*. 2023;18(4):248-53.
  20. Karabucak B, Bunes A, Chehoud C, Kohli MR, Setzer F. Prevalence of Apical Periodontitis in Endodontically Treated Premolars and Molars with Untreated Canal: A Cone-beam Computed Tomography Study. *Journal of Endodontics*. 2016;42(4):538-41.
  21. Yoshioka T, Kikuchi I, Fukumoto Y, Kobayashi C, Suda H. Detection of the second mesiobuccal canal in mesiobuccal roots of maxillary molar teeth ex vivo. *Int Endod J*. 2005;38(2):124-8.
  22. Coelho de Carvalho MC, Zuolo ML. Orifice Locating with a Microscope. *J Endod*. 2000;26(9):532-4.
  23. Von Arx T. Frequency and type of canal isthmuses in first molars detected by endoscopic inspection during periradicular surgery. *Int Endod J*. 2005;38(3):160-8.
  24. Baldassari-Cruz LA, Lilly JP, Rivera EM. The influence of dental operating microscope in locating the mesiolingual canal orifice. *Oral Surg Oral Med Oral Pathol Oral Radiol Endod*. 2002;93(2):190-4.
  25. Khalighinejad N, Aminoshariae A, Kulild JC, Williams KA, Wang J, Mickel A. The effect of the dental operating microscope on the outcome of nonsurgical root canal treatment: a retrospective case-control study. *J Endod*. 2017;43(5):728-32.
  26. Vertucci FJ. Root canal anatomy of the human permanent teeth. *Oral surgery, oral medicine, oral pathology*. 1984;58(5):589-99.
  27. Molander A, Reit C, Dahlén G, Kvist T. Microbiological status of root-filled teeth with apical periodontitis. *Int Endod J*. 1998;31(1):1-7.
  28. de Paula-Silva FWG, Wu M-K, Leonardo MR, da Silva LAB, Wesslink PR. Accuracy of periapical radiography and cone-beam computed tomography scans in diagnosing apical periodontitis using histopathological findings as a gold standard. *J Endod*. 2009;35(7):1009-12.
  29. Velvart P, Hecker H, Tillinger G. Detection of the apical lesion and the mandibular canal in conventional radiography and computed tomography. *Oral Surg Oral Med Oral Pathol Oral Radiol Endod*. 2001;92(6):682-8.
  30. Ng YL, Mann V, Gulabivala K. A prospective study of the factors affecting outcomes of nonsurgical root canal treatment: part 1: periapical health. *Int Endod J*. 2011;44(7):583-609.
  31. Patel S, Dawood A, Mannocci F, Wilson R, Pitt Ford T. Detection of periapical bone defects in human jaws using cone beam computed tomography and intraoral radiography. *Int Endod J*. 2009;42(6):507-15.
  32. Weissman J, Johnson JD, Anderson M, Hollender L, Huson T, Paranjpe A, Patel S, Cohenca N. Association between the Presence of Apical Periodontitis and Clinical Symptoms in Endodontic Patients Using Cone-beam Computed Tomography and Periapical Radiographs. *J Endod*. 2015;41(11):1824-9.
  33. Venskutonis T, Plotino G, Tocci L, Gambarini G, Maminskas J, Juodzbalys G. Periapical and Endodontic Status Scale Based on Periapical Bone Lesions and Endodontic Treatment Quality Evaluation Using Cone-beam Computed Tomography. *J Endod*. 2015;41(2):190-6.
  34. Lofthag-Hansen S, Huuromonen S, Gröndahl K, Gröndahl H-G. Limited cone-beam CT and intraoral radiography for the diagnosis of periapical pathology. *Oral Surg Oral Med Oral Pathol Oral Radiol Endod*. 2007;103(1):114-9.
  35. Bornstein MM, Lauber R, Sendi P, Von Arx T. Comparison of periapical radiography and limited cone-beam computed tomography in mandibular molars for analysis of anatomical landmarks before apical surgery. *J Endod*. 2011;37(2):151-7.
  36. Torabinejad M, Rice DD, Maktabi O, Oyoyo U, Abramovitch K. Prevalence and Size of Periapical Radiolucencies Using Cone-beam Computed Tomography in Teeth without Apparent Intraoral Radiographic Lesions: A New Periapical Index with a Clinical Recommendation. *Journal of Endodontics*. 2018;44(3):389-94.
  37. Kruse C, Spin-Neto R, Wenzel A, Vaeth M, Kirkevang LL. Impact of cone beam computed tomography on periapical assessment and treatment planning five to eleven years after surgical endodontic retreatment. *Int Endod J*. 2018;51(7):729-37.
  38. Torabinejad M, Kettering JD, McGraw JC, Cummings RR, Dwyer TG, Tobias TS. Factors associated with endodontic interappointment emergencies of teeth with necrotic pulps. *J Endod*. 1988;14(5):261-6.

**Please cite this paper as:** Ebrahimi R, Khajeh S, Paik H, Moradi M, Rastegar Khosravi M. Prevalence of Untreated Canals and Their Association with Periapical Periodontitis Using Cone-beam Computed Tomography. *Iran Endod J*. 2024;19(3): 208-15. *Doi: 10.22037/iej.v19i3.42440*.