

HIV-associated large aggressive extranodal lymphoma of the oral cavity

Departments of Oral and Maxillofacial Surgery and Oral Pathology, Goa Dental College and Hospital, Goa, India

Rahul Dilip Kamat, Vikas Dhupar, Francis Akkara, Anita Dhupar¹

ABSTRACT

Malignant lymphomas form a heterogeneous group of neoplasms of the lymphoid tissue with different clinical courses, depending on the treatment and the prognosis. Human immunodeficiency virus (HIV) infection and acquired immune deficiency syndrome (AIDS) have been associated with an increased risk for the development of lymphoproliferative disorders. The incidence of lymphoma is associated with 60-fold increase in seropositive patients as compared to seronegative patients. The present case describes a diffuse aggressive extranodal lymphoma in a known HIV patient.

Address for correspondence:

Dr. Rahul Dilip Kamat,
Department of Oral and Maxillofacial Surgery, Goa Dental College and Hospital, Bambolim, Goa - 403 202, India.
E-mail: rahul567dk@gmail.com

Key words: Extranodal, human immunodeficiency virus, non-Hodgkin's lymphoma

INTRODUCTION

Human immunodeficiency virus (HIV) infection and acquired immune deficiency syndrome (AIDS) have been associated with an increased risk for the development of lymphoproliferative disorders. Lymphomas represent a heterogeneous group of lymphoproliferative disorders that can originate in B-cells, T-cells, or natural killer cells.

Extranodal lymphoma as a distinct entity was first described by Isaacson and Wright in 1983. Lymphomas can be broadly classified into Hodgkins and non-Hodgkin's lymphoma (NHL) based on their clinical and histopathologic presentation.

The disease may be restricted to lymph nodes or may present itself at extranodal sites. Extranodal lymphomas are most commonly seen involving the gastrointestinal tract followed by head and neck region. Oral cavity as a primary site constitutes only 2% of all extranodal NHL.^[1,2] This is why the diagnosis is

frequently postponed and the treatment improper as was the case in our patient which was being treated as a case of odontogenic infection before being referred to our institute. The present paper aims at alerting clinicians of considering lymphoproliferative malignancy as a potential differential diagnosis especially in those patients not responding to conventional treatment modalities.

CASE REPORT

A 42-year-old female with a known HIV seropositivity for past 6 years reported to our department with a complaint of nonresolving swelling over left side of the face of past 2 months duration. She also gave a history of noticing intraoral growth in the mandibular left posterior region for the past 3 weeks. The swelling was accompanied by progressive decrease in mouth opening, loss of appetite, rapid increase in size of intraoral growth, and significant weight loss of more

This is an open access article distributed under the terms of the Creative Commons Attribution-NonCommercial-ShareAlike 3.0 License, which allows others to remix, tweak, and build upon the work non-commercially, as long as the author is credited and the new creations are licensed under the identical terms.

For reprints contact: reprints@medknow.com

How to cite this article: Kamat RD, Dhupar V, Akkara F, Dhupar A. HIV-associated large aggressive extranodal lymphoma of the oral cavity. Natl J Maxillofac Surg 2016;7:205-8.

Access this article online	
Quick Response Code: 	Website: www.njms.in
	DOI: 10.4103/0975-5950.201371

than 6 kg for the past 2 months. She also complained of fever, night sweats, and easy fatigability. The patient was referred to our institute by a general physician due to nonresolving nature of the swelling. After going through her medical records it came to our notice that patient was diagnosed as HIV positive in the year 2010 and was on art for the same. Her CD4 counts at the time of presentation were 58. On local examination, there was gross facial asymmetry with a single diffuse swelling over left side of the face extending suproinferiorly from the zygomatic arch to about 2 cm below the inferior border of the mandible into the submandibular region. Antero-posteriorly the swelling extended from the angle of the mouth up to the tragus of the ear measuring approximately 8 cm × 5 cm × 3 cm with obliteration of nasolabial fold on the left side. The skin overlying the swelling had a taut and shiny appearance [Figure 1].

On palpation the swelling was firm, tender and nonfluctuant. Lymph node examination revealed single, oval-shaped, mobile node in the left submandibular region.

Intraorally there was single, diffuse large proliferative growth extending from the mandibular incisor region to the retromolar trigone and crossing over to the lingual side up to the premolar region measuring 8 cm × 4 cm × 4 cm in greatest dimension. The overlying mucosa had a corrugated appearance with areas of hyperpigmentation and slough [Figure 2]. Oral hygiene was poor and carious teeth were present in all four quadrants. A computer tomographic scan was taken to see for the extent of bony involvement which revealed erosion of buccal and lingual cortices. It also revealed an expansile lesion involving buccal and submandibular space [Figure 3].

Chest X-ray (postero-anterior view) revealed multiple radiopaque foci which were suggestive of old-treated Koch's [Figure 4].

The swelling was subjected to incisional biopsy under local anesthesia. The hematoxylin-eosin stained section showed diffuse sheets of monotonous lymphocytes homogenous in size and shape with intensely basophilic vacuolated cytoplasm. A large number of abnormal mitotic figures were seen. Dilated blood vessels and areas of extravasated erythrocytes were seen between undifferentiated lymphocytes [Figure 5].

The histopathologic diagnosis was suggestive of NHL.

To identify the subtype of NHL, immunohistochemistry was performed using CD45, CD20, and CD3 markers.

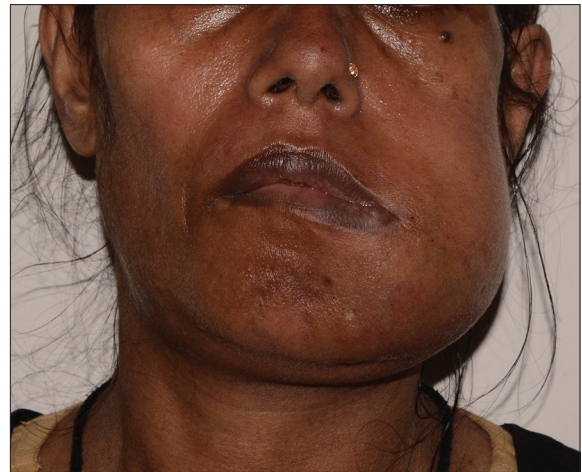

Figure 1: Extent of extraoral swelling

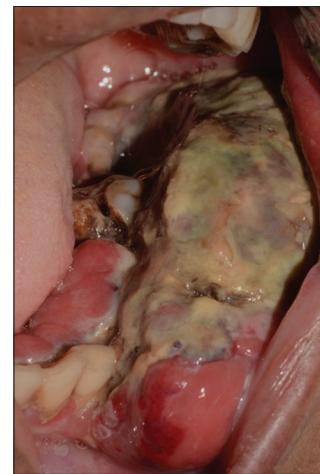


Figure 2: Large diffuse intraoral growth with discoloration of overlying mucosa

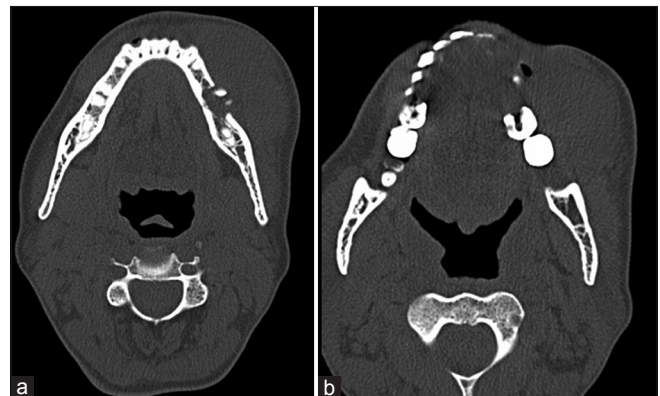

Figure 3: (a) Axial slice showing heterogeneous enhancing mass in the left buccal and Submandibular region. (b) Axial slice showing heterogeneous enhancing mass in the left buccal and submandibular region

The patient upon definitive diagnosis of NHL was started on palliative chemotherapy. Although partial regression of primary tumor was present, unfortunately the patient was lost to follow-up following 6 months after chemotherapy after being discharged from our unit.

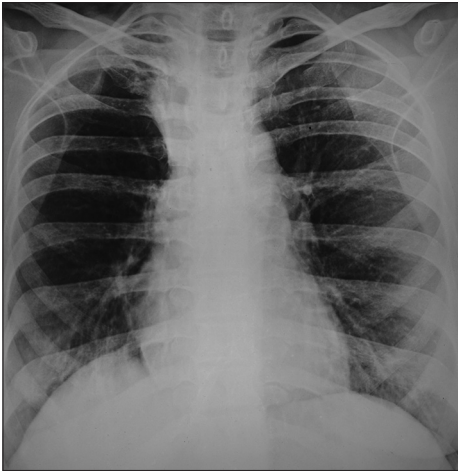

Figure 4: Chest X-ray (posteroanterior view) demonstrating multiple radiopaque foci bilaterally

DISCUSSION

NHL is primarily a disorder of lymph nodes. HIV-associated lymphoproliferative disorders are a heterogeneous group of diseases that arise in the presence of HIV-associated immunosuppression, a state that permits the unchecked proliferation of Epstein-Barr virus and Kaposi sarcoma herpes virus-infected lymphocytes.^[3]

Lymphomas can be classified as Hodgkin's lymphoma (HL) or NHL. HL rarely shows extranodal disease (1% cases) in contrast to NHL (23–30% cases). WHO/REAL classification divided lymphomas into four major types: Indolent lymphomas, aggressive lymphomas, highly aggressive lymphomas, and special group of localized indolent lymphomas. The disease may be restricted to lymph nodes or may present itself at extranodal sites. When limited to extranodal sites, the most common areas of presentation include gastrointestinal tract followed by the head and neck region which is the commonest area affected in the Indian subcontinent.^[4] Oral lesions account for only 2–4% of NHL and often act as diagnostic as well as prognostic indicators of the disease.^[5] Sander *et al.* in 2001 stated that extranodal variants were found to be more aggressive and rapidly growing as compared to their nodal counterparts.^[6] Primary lymphomas occurring in the mandible is rare. A review of 100 patients by Larson *et al.* revealed that extranodal lymphomas of the head and neck had no localization in the mandible. A similar study by Conley *et al.* concluded that there was only one case with oral manifestation. In unison with other researchers, Econopoulos' found that out of the 116 cases of head and neck NHL treated between 1977 and 1997, only nine cases (7.8%) reported with mandible and/or gingival involvement.^[7,8]

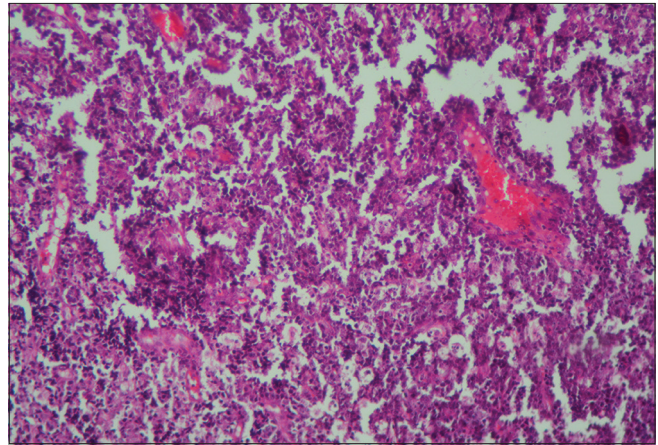


Figure 5: Photomicrograph showing diffuse sheets of lymphocytes interspread with dilated blood vessels and erythrocytes (H and E, ×100)

The male-to-female ratio lies in the range 2:1. The present case is that of a 42-year-old female affecting the mandibular left gingivobuccal complex which accounts for being a rare site for occurrence of this tumor. The rarity of these tumors has often resulted in these tumors being confused with other common pathoses like periapical or periodontal inflammatory processes as was the case in our patient that was being treated as an odontogenic infection before being referred to our institute. Hashimoto in the year 1982 reviewed pathological characteristics of oral NHL and according to his 9 cases and review of literature he concluded that B-cell lymphoma is the most common histotype in oral NHL. However, Teruya-Feldstein *et al.* reported diffuse histiocytic lymphoma as the most common histotype in jaw bones.^[9,10] A brief literature review has been summarized in Table 1.

Many forms of AIDS-NHL are characterized by the presence of recurrent genetic alterations, which may be due, in part, to errors in normal processes that occur in activated B-cells, which involve modification of somatic DNA, such as immunoglobulin gene (Ig), class-switch recombination, and somatic hyper mutation. AIDS is able to produce DNA double-strand breaks, resulting in widespread genome instability, which may contribute to some of the non-Ig-related genetic modifications that are present in AIDS-NHL.^[11]

Chemotherapy forms the basis of treatment in management of lymphoproliferative dyscrasias. Single or multiple agent chemotherapy as well as several bio-immunotherapeutic agents such as alemtuzumab has been used. New cell and lineage markers are constantly being discovered and added to existing list of antibodies. Panel of markers are used for diagnosis of malignant lymphoma versus reactive lymphoid hyperplasia. The T-cell receptor-associated protein β F1 has been found to be expressed in approximately 75% of the cases.^[12]

Table 1: Summary of literature review

Criteria evaluated	Year of publication	Authors	Conclusion
Age	2005	van der Waal <i>et al.</i> ^[14]	Median age 59 years
	2011	Shah <i>et al.</i> ^[15]	Median age 46.2 years
Gender	2005	van der Waal <i>et al.</i>	Male > female
	2011	Shah <i>et al.</i>	Male > female (3:2)
Most common site in oral cavity	2005	van der Waal <i>et al.</i>	Palate and gingiva
	2011	Shah <i>et al.</i>	Gingivobuccal complex
Histologic subtype	2014	Sirsath <i>et al.</i> ^[16]	Tongue
	1982	Teruya-Feldstein <i>et al.</i>	Plasmablastic variety
CHOP regimens	2004	Hashimoto and Kurihara ^[9]	B-cell lymphoma
	1981	Yokobayashi <i>et al.</i> ^[17]	VEMP
	2000	Maheshwari <i>et al.</i> ^[18]	CVP
	2011	Shah <i>et al.</i>	CHOP
	2014	Chennagiri <i>et al.</i>	CHOP + EBRT

EBRT: External beam radiation therapy, CVA: Cerebrovascular accident, VEMP: Vestibular evoked myogenic potentials, CHOP: Chemotherapy

Survival depends on the extent of the disease, presence of HIV disease, histopathology, and Ann Arbor staging. According to Pazoki *et al.*, for extranodal head and neck lymphoma 5-year survival rate is approximately 50%, whereas median survival rate is 10 years.^[13]

Lymphomas are a diagnostic dilemma as most patients present with a nonspecific complaint and radiographs are usually inconclusive. Consequently they are erroneously treated as more common pathoses of infective or inflammatory origin, as was the case in our patient whose complaint was swelling on the left side of the face which was suspected and treated to be an infection of odontogenic origin.

CONCLUSION

NHL of the head and neck region, particularly of the mandible, are rare and may be confused with other neoplasms or periapical or periodontal inflammatory processes. The diagnosis of oral extranodal lymphoma is challenging due to low index of clinical suspicion. Although it may be overzealous to suspect lymphoma in every patient with intraoral growth, selected subgroups of patients like those who are immunocompromised should undergo diagnostic workup to rule out neoplastic basis of the complaint.

Declaration of patient consent

The authors certify that they have obtained all appropriate patient consent forms. In the form the patient(s) has/have given his/her/their consent for his/her/their images and other clinical information to be reported in the journal. The patients understand that their names and initials will not be published and due efforts will be made to conceal their identity, but anonymity cannot be guaranteed.

Financial support and sponsorship

Nil.

Conflicts of interest

There are no conflicts of interest.

REFERENCES

- Larson DL, Robbins KT, Butler JJ. Lymphoma of the head and neck. A diagnostic dilemma. *Am J Surg* 1984;148:433-7.
- Eisenbud L, Sciubba J, Mir R, Sachs SA. Oral presentations in non-Hodgkin's lymphoma: A review of thirty-one cases. Part II. Fourteen cases arising in bone. *Oral Surg Oral Med Oral Pathol* 1984;57:272-80.
- Epeldegui M, Vendrame E, Martínez-Maza O. HIV-associated immune dysfunction and viral infection: Role in the pathogenesis of AIDS-related lymphoma. *Immunol Res* 2010;48:72-83.
- Bagirath PV, Kumar JV, Arvind UD, Shailaja G. Aggressive extranodal peripheral T-cell non-Hodgkin's lymphoma: A rare case report and review. *J Oral Maxillofac Pathol* 2014;18:80-3.
- Neville BW, Damm DD, Allen CM, Bouquot JE. *Oral and Maxillofacial Pathology*. 3rd ed. New York: WB Saunders Elsevier; 2009. p. 595-8.
- Sander CA, Flaig MJ, Jaffe ES. Cutaneous manifestations of lymphoma: A clinical guide based on the WHO classification. *Clin Lymphoma* 2001;2:86-100.
- Conley SF, Staszak C, Clamon GH, Maves MD. Non-Hodgkin's lymphoma of the head and neck: The University of Iowa experience. *Laryngoscope* 1987;97 (3 Pt 1):291-300.
- Economopoulos T, Fountzilas G, Kostourou A, Daniilidis J, Pavlidis N, Andreopoulou H, *et al.* Primary extranodal non-Hodgkin's lymphoma of the head and neck in adults: A clinicopathological comparison between tonsillar and non tonsillar lymphomas. (Hellenic co-Operative Oncology Group). *Anticancer Res* 1998;18:4655-60.
- Hashimoto N, Kurihara K. Pathological characteristics of oral lymphomas. *J Oral Pathol* 1982;11:214-27.
- Teruya-Feldstein J, Chiao E, Filippa DA, Lin O, Comenzo R, Coleman M, *et al.* CD20-negative large-cell lymphoma with plasmablastic features: A clinically heterogeneous spectrum in both HIV-positive and -negative patients. *Ann Oncol* 2004;15:1673-9.
- Eisenbud L, Sciubba J, Mir R, Sachs SA. Oral presentations in non-Hodgkin's lymphoma: A review of thirty-one cases. Part I. Data analysis. *Oral Surg Oral Med Oral Pathol* 1983;56:151-6.
- The International Non-Hodgkin's Lymphoma Prognostic Factors Project. A predictive model for aggressive non-Hodgkin's lymphoma. *N Engl J Med* 1993;329:987-94.
- Pazoki A, Jansisyanont P, Ord RA. Primary non-Hodgkin's lymphoma of the jaws: Report of 4 cases and review of the literature. *J Oral Maxillofac Surg* 2003;61:112-7.
- van der Waal RI, Huijgens PC, van der Valk P, van der Waal I. Characteristics of 40 primary extranodal non-Hodgkin lymphomas of the oral cavity in perspective of the new WHO classification and the International Prognostic Index. *Int J Oral Maxillofac Surg* 2005;34:391-5.
- Shah GH, Panwar SK, Chaturvedi PP, Kane SN. Isolated primary extranodal lymphoma of the oral cavity: A series of 15 cases and review of literature from a tertiary care cancer centre in India. *Indian J Med Paediatr Oncol* 2011;32:76-81.
- Sirsath NT, Lakshmaiah KC, Das U, Lokanatha D, Chennagiri SP, Ramarao C. Primary extranodal non-Hodgkin's lymphoma of oral cavity – A single centre retrospective study. *J Cancer Res Ther* 2014;10:945-50.
- Yokobayashi Y, Nakajima T, Fikushima M, Ishiki T. Non-Hodgkin's lymphoma of the gingiva. A case report. *Int J Oral Surg* 1981;10:359-62.
- Maheshwari GK, Baboo HA, Gopal U, Wadhwa MK. Primary extra-nodal non-Hodgkin's lymphoma of the cheek. *J Postgrad Med* 2000;46:211-2.