

Spiral Cystic Duct: Beware

Ehab Elakkary, MD, Karen Ching, MD, Michael J. Jacobs, MD

ABSTRACT

Laparoscopic cholecystectomy (LC) is currently the most popular operation performed for gallbladder disease. Our objective is to emphasize the superiority of the “critical view technique” over the “infundibular technique” in case of inflammation or aberrant anatomy. We present a case of a 21-year-old female who was taken to the operating room for LC. The critical view technique was performed with anterolateral infundibular retraction, and the infundibulum and body were dissected along the peritoneal reflection on both sides of the gallbladder. The cystic duct and infundibulum were funnel shaped and spiraled from lateral to posteromedial rotation.

Aberrant anatomy is commonly seen during LC. We have routinely espoused the critical view technique or the use of intraoperative cholangiogram and believe that it should be applied to aid in the identification of the cystic duct (CD). We avoid the infundibular technique, because it may be a contributing factor to common bile duct (CBD) injury.

Key Words: Laparoscopic cholecystectomy, Cystic duct, Infundibular technique, Critical view technique, Common bile duct injury.

INTRODUCTION

Knowledge of normal and aberrant anatomy is of extreme importance in bilio-pancreatic surgery. Laparoscopic cholecystectomy (LC) is currently the most popular operation performed for gallbladder disease. Our objective is to emphasize the superiority of the “critical view technique” over the “infundibular technique” in case of inflammation or aberrant anatomy.

Herein, we present a rare case of an anomalous cystic duct (CD), whereby the CD and infundibulum were funnel-shaped and spiraled from a lateral to posteromedial position with relation to the common bile duct (CBD).

CASE REPORT

A 21-year-old, white female presented to the emergency department with acute epigastric and right upper quadrant abdominal pain. The pain was sharp, radiated to the back, and was associated with nausea and emesis. The past medical and surgical histories were negative with the exception of severe obesity. Physical examination revealed a morbidly obese patient with a body mass index (BMI) of 40 kg/m² (weight 240 lbs, height 5'6") with normal vital signs. Pertinent examination findings included epigastric and right upper quadrant tenderness without peritoneal signs.

Laboratory assays included the following: total bilirubin, 3 g/dL; amylase, 2380 g/dL; lipase, 6830 g/dL; WBC, 14.5 K/L. An ultrasound revealed cholelithiasis without gallbladder wall thickening, and the CBD measured 8.9mm in diameter. A delayed computerized tomography scan demonstrated inflammatory changes around the pancreas without signs of hemorrhage, necrosis, or peripancreatic fluid.

The patient was diagnosed with biliary pancreatitis and was kept nothing by mouth (NPO), continually volume-resuscitated, and serially examined. Further evaluations included an endoscopic retrograde cholangiopancreatography (ERCP), which showed a patent biliary system, free bile flow at the ampulla, and normal common, hepatic, and pancreatic ducts (**Figure 1**). The patient was prepared for LC during the same hospital admission.

During laparoscopy, there was suggestion of phlegmonous

Departments of Surgery, North Oakland Medical Centers, Pontiac, Michigan, USA and Wayne State University, Detroit, Michigan, USA (Dr Elakkary).

Department of Surgery Providence Hospital and Medical Centers, Southfield, Michigan, USA (Drs Ching, Jacobs).

Address reprint requests to: Ehab Elakkary, MD, Department of Surgery, North Oakland Medical Centers, 461 W. Huron, Pontiac, MI 48341, USA. Telephone: 248 857 7314. E-mail: ehabakkary@yahoo.com

© 2006 by JLS, *Journal of the Society of Laparoendoscopic Surgeons*. Published by the Society of Laparoendoscopic Surgeons, Inc.

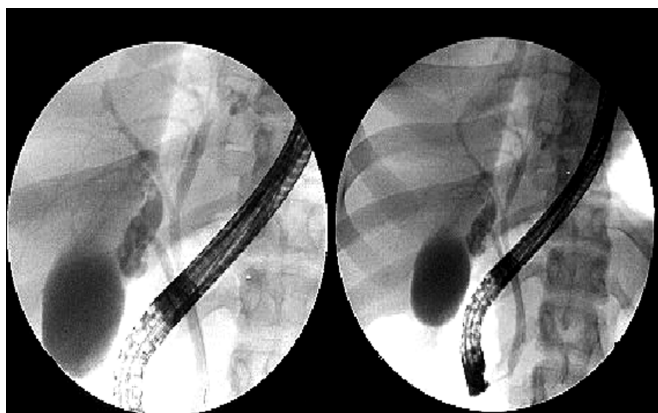


Figure 1. Endoscopic retrograde cholangiopancreatography showing normal-appearing common bile duct, hepatic, and pancreatic ducts.

change in the region of the peripancreatic head. Chronic adhesions were encountered and lysed in the region of the infundibulum. The critical view technique was performed with antero-lateral infundibular retraction, and the infundibulum and body were dissected along the peritoneal reflection on both sides of the gallbladder. The cystic duct and infundibulum were funnel shaped and spiraled from lateral to postero-medial rotation (**Figure 2**). Confirmation and isolation of the cystic artery and duct were performed. The cystic duct/fusiform infundibulum measured averaged 1cm and was confirmed to enter the gallbladder proper. The cystic duct and artery were ligated with clips and an Endo-Loop (Ethicon, Somerville, NJ) suture. The gallbladder was further excised without difficulty. An intraoperative cholangiogram was not performed because the anatomy was well visualized and cautiously dissected during the critical view

technique. The patient was discharged home on the first postoperative day and has remained asymptomatic.

The histopathologic diagnosis was consistent with chronic calculous cholecystitis and cholesterosis.

DISCUSSION

Biliary injury is the most common cause of litigation in gastrointestinal surgery, with 20% of all general surgery claims arising from laparoscopic procedures, 50% of those claims are for injury of the bile duct.¹ Review of the literature revealed a paucity of information regarding anomalous CD anatomy. The normal CD measures 2cm to 4cm in length and 1mm to 5mm in diameter. It contains the spiral valves of Heister and frequently follows a tortuous course. Variations in the CD anatomy are common (18% to 23% of cases).¹ The CD usually joins the CBD at an acute angle; however, it may course parallel to the common hepatic duct (CHD). The union of the CD with the main biliary duct can occur on any side of the main duct or even, for example, the right hepatic duct.² Additionally, a cholecystohepatic duct may enter the gallbladder directly through the gallbladder fossa and should be ligated to avoid biliary fistula³ after identification of the ductal anatomy. A prospective study² was done by the Korean Research Group, whereby an ERCP was performed on 10,243 patients at 10 university hospitals over a 40-month period from March 1997 to June 1999. Variations in the CD anatomy were found in 16.9% of the patients. Low union with the CHD was identified in 9% of patients, while a spiral CD (passing either anterior or posterior to the CHD) was found in 7.9%.² Although LC has been considered the gold standard in the management of gallbladder disease, the in-

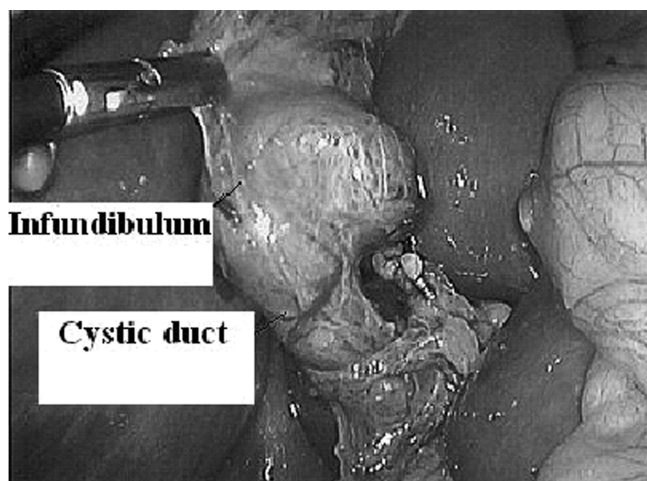
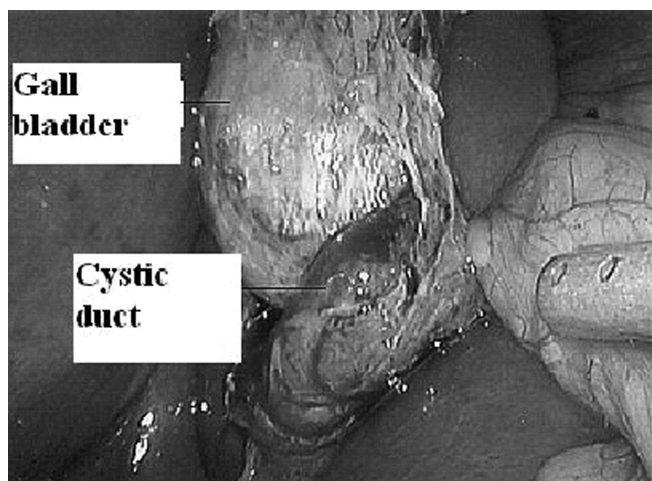


Figure 2. Dissection of the spiral cystic duct.

idence of CBD injury may occur 2 times more frequently in LC than in the conventional open technique.⁴ Even in cases of aberrant CD anatomy, injury to the CBD can be avoided by extensive dissection of the triangle of Calot and utilizing the critical view technique.⁵ Surgeons from the Washington University in Saint Louis, Missouri have attributed biliary injury to lack of experience, inflammation, or aberrant anatomy. Injury was found to occur more often while the infundibular technique rather than the critical view technique is being performed. The critical view technique is performed by extensive dissection of Calot's triangle, rendering the structures free of fat, fibrous, and areolar tissue. The lower end of the gallbladder should also be dissected from the liver bed. At the end of dissection, only 2 structures should enter the gallbladder (cystic duct and artery), and the bottom part of the liver bed should be visible. In this technique, it is not mandatory to dissect the CBD. For proper dissection of the triangle of Calot, it should be done from both the anterior and posterior aspects, maintaining the plane of dissection on the gallbladder.⁶ Furthermore, the performance of an intraoperative cholangiogram may help identify the cystic duct, especially in the case of inflammation.⁷ Authors have shown that the infundibular technique, where the cystic duct is identified as it emanates from the infundibulum of the gallbladder, should be avoided.⁸ Acute inflammation and a false infundibulum could mislead the surgeon into identifying the CBD as the CD.⁸

CONCLUSION

Aberrant anatomy is commonly seen during laparoscopic cholecystectomy.

We have routinely espoused the critical view technique or the use of intraoperative cholangiogram and believe that it

should be applied to aid in the identification of the CD. We avoid the infundibular technique, because it may be a contributing factor to CBD injury.

References:

1. Kern KA. Malpractice litigation involving laparoscopic cholecystectomy. Cost, cause, and consequences. *Arch Surg*. 1997; 132:392–398.
2. Hong-Ja K, Myung-Hwan K, et al. Normal structure, variations and anomalies of the pancreatobiliary ducts of Koreans: a nationwide cooperative prospective study *Gastrointest Endosc*. 55(7):889–896, 2002.
3. Turner MA, Fulcher AS. The cystic duct: normal anatomy and disease processes. *Radiographics*. 2001;21:3–22.
4. Ahrendt SA, Pitt HA. *Sabiston Textbook of Surgery, 17th ed*. St Louis, MO: WB Saunders; 2004;1598.
5. Sari YS, Tunali V, Tomaoglu K, Karagoz B, Guneyi A, Karagoz I. Can bile duct injuries be prevented? "A new technique in laparoscopic cholecystectomy". *BMC Surg*. 2005;17:5–14.
6. Misra M, Schiff J, Rendon G, Rothschild J, Schwaartzberg S. Laparoscopic cholecystectomy after the learning curve: what should we expect? *Surg Endosc*. 2005;19:1278–1281.
7. Strasberg SM, Hertl M, Soper NJ. An analysis of the problem of biliary injury during laparoscopic cholecystectomy. *J Am Coll Surg*. 1995;180(1):101–125.
8. Strasberg SM. Avoidance of biliary injury during laparoscopic cholecystectomy. *J Hepatobiliary Pancreat Surg*. 2002; 9(5):543–547.
9. Strasberg SM, Eagon CJ, Drebin JA. The "hidden cystic duct" syndrome and the infundibular technique for laparoscopic cholecystectomy – the danger of the false infundibulum. *J Am Coll Surg*. 2000;191(6):661–667.