

## Bullous Lung Disease

Corey Goldberg, MD\*  
Kathleen E. Carey, MD†

\* University of Florida College of Medicine, Department of Emergency Medicine,  
Jacksonville, Florida  
† Mayo Clinic, Department of Radiology, Jacksonville, Florida

Supervising Section Editor: Sean Henderson, MD

Submission history: Submitted March 4, 2013; Revision received March 25, 2013; Accepted March 25, 2013

Full text available through open access at [http://escholarship.org/uc/uciem\\_westjem](http://escholarship.org/uc/uciem_westjem)

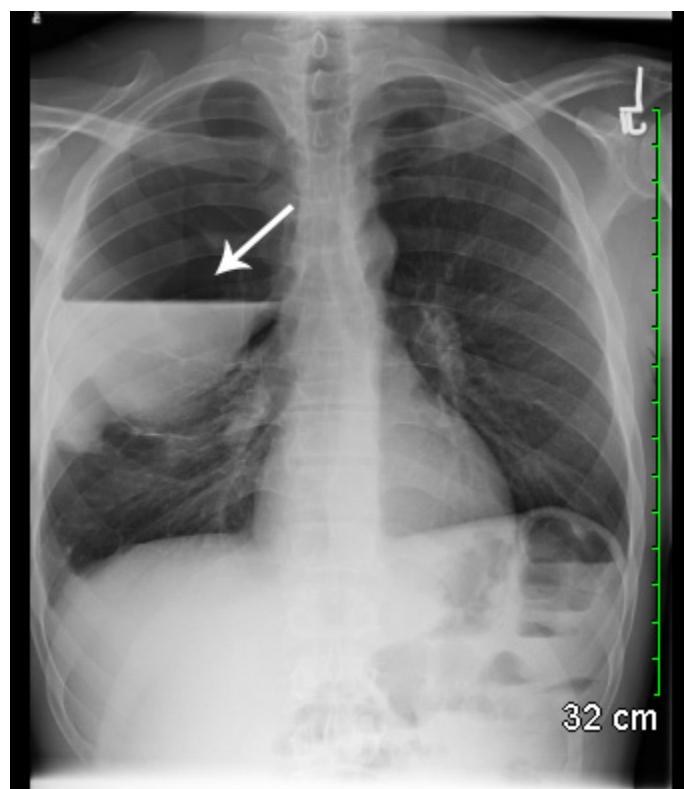
DOI: 10.5811/westjem.2013.3.16276

[West J Emerg Med. 2013;14(5):450–451.]

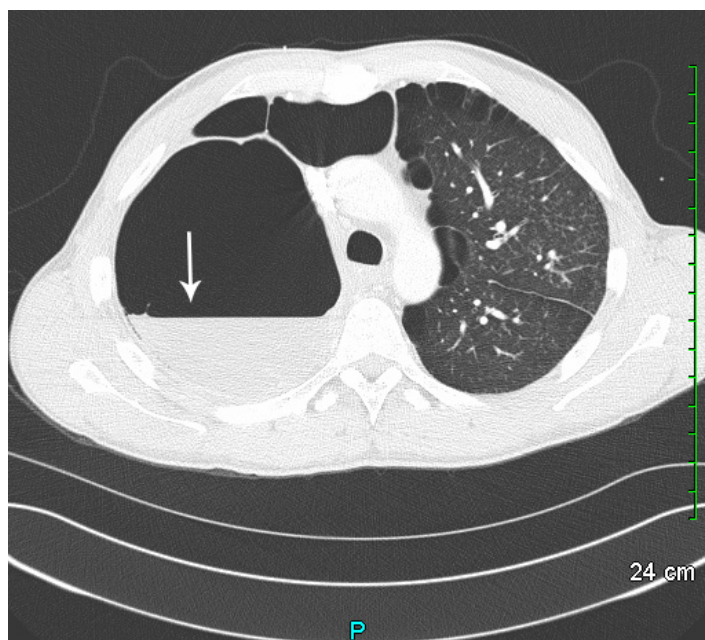
A 34-year-old black man presented to the emergency department with right-sided pleuritic chest pain, productive cough, low grade fever, and dyspnea. He had a history of emphysema, deep vein thrombosis, protein C and S deficiency, and inferior vena cava filter. His physical exam was significant for fever, tachypnea, tachycardia, and decreased breath sounds over the right upper and middle lung fields. We obtained a chest radiograph (Figure 1).

### DIAGNOSIS

Giant emphysematous bulla is defined as air-filled spaces that occupy more than one-third of the hemithorax and develops in a lung destroyed by generalized emphysema.<sup>1</sup> Treatment typically involves surgery, although a variety of



**Figure 1.** Frontal chest radiograph demonstrating a large right upper lung bulla with internal layering of fluid.



**Figure 2.** Coronal chest computed tomography demonstrating extensive bullous disease of the lungs with a prominent bulla in the right upper lobe containing an air fluid level.

procedures have been proposed, including local excision of the bullae, plication, stapler resection, lobectomy, and videothoracoscopy.<sup>2</sup> Surgical therapy is indicated when patients have incapacitating dyspnea or for patients who have complications related to bullous disease, such as infection or pneumothorax.<sup>3</sup> Most patients with bullae have a significant cigarette smoking history, although cocaine smoking, pulmonary sarcoidosis, alpha 1-antitrypsin deficiency, 1-antichymotrypsin deficiency, Marfan's syndrome, Ehlers-Danlos syndrome and inhaled fiberglass exposure have all been implicated.<sup>4</sup> Additionally, marijuana smoking has resulted in extensive emphysematous bullous disease seen in many young patients.<sup>5</sup>

In our patient with an infected, fluid-filled bulla, surgical intervention was indicated and a pulmonary drain was placed into the bulla by computed tomography (CT) guidance. It

should be realized that the initial chest radiograph could wrongly lead the emergency provider to place a chest tube, causing significant complications. A case published by Bourgouin et al<sup>6</sup> reports 2 patients with bullous lung disease wrongly receiving chest tube placement. In patients with severe bullous lung disease CT (Figure 2) will differentiate emphysematous bullae from pneumothorax and save the patient an unnecessary and potentially dangerous procedure.<sup>7</sup> Our patient was further evaluated with pulmonary function testing and eventually underwent video-assisted thorascopic surgery.

---

*Address for Correspondence:* Corey Goldberg, MD, Office of Emergency Medicine, UF College of Medicine-Jacksonville, 1st Floor, Clinical Center, 655 West 8th Street, Jacksonville, FL 32209. Email: Corey.Goldberg@jax.ufl.edu.

---

*Conflicts of Interest:* By the WestJEM article submission agreement, all authors are required to disclose all affiliations, funding sources and financial or management relationships that could be perceived as potential sources of bias. The authors disclosed none.

## REFERENCES

1. Greenberg JA, Singhal S, Kaiser LR. Giant bullous lung disease: evaluation, selection, techniques, and outcomes. *Chest Surg Clin N Am.* 2003;13:631-649.
2. Santini M, Fiorelli A, Vicidomini G, et al. Endobronchial treatment of giant emphysematous bullae with one-way valves: a new approach for surgically unfit patients. *Eur J Cardiothorac Surg.* 2011;40:1425-1431.
3. Vigneswaran WT, Townsend ER, Fountain SW. Surgery for bullous disease of the lung. *Eur J Cardiothorac Surg.* 1992;6:427-430.
4. Wheatley III GH, Estrera AS. "Bullous Lung Disease." CTS NET: The Cardiothoracic Surgery Network. Available at: <http://www.ctsnet.org/sections/clinicalresources/clinicalcases/article-1.html>. Accessed February 16, 2013.
5. Johnson MK, Smith RP, Morrison D, et al. Large lung bullae in marijuana smokers. *Thorax.* 2000;55:340-342.
6. Bourgouin P, Cousineau G, Lemire P, et al. Computed tomography used to exclude pneumothorax in bullous lung disease. *J Can Assoc Radiol.* 1985;36(4):341-342.
7. Philips GD, Trotman-Dickenson B, Hodson ME, et al. Role of CT in the management of pneumothorax in patients with complex cystic lung disease. *Chest.* 1997;112:275-278.