

# Surgical Embolectomy in a 34-Week Pregnant Woman with High Risk Pulmonary Embolism and Haemodynamic Instability

Giulia Maj, Nicola Strobelt<sup>1</sup>, Andrea Audo<sup>2</sup>, Anna Maria Arena, Giovanni Parodi, Vittorio Aguggia<sup>1</sup>, Massimo Serra<sup>2</sup>, Maria Giribaldi, Ermelinda Martuscelli, Fabrizio Racca

Departments of Anesthesia and Intensive Care, <sup>1</sup>Gynecology and Obstetrics and <sup>2</sup>Cardiac Surgery, Azienda Ospedaliera SS, Antonio e Biagio e Cesare Arrigo, Alessandria, Italy

## ABSTRACT

Pulmonary embolism represents the leading cause of maternal mortality in developed countries. The optimal treatment of high-risk pulmonary embolism with cardiovascular instability and at high hemorrhagic risk is still debated but surgical embolectomy represents an effective option. We describe the case of a 35-year-old woman in week 34 of pregnancy who was referred to our hospital because of exertional dyspnea and tachycardia and a few hours later became hypotensive and hypoxic. Pulmonary embolism was detected by performing an angio-computed tomography (CT) scan. After a successful cesarean section, emergent embolectomy was performed without inducing uterine hemorrhage. Both mother and the newborn recovered without postoperative sequelae.

**Keywords:** Embolectomy, pregnancy, pulmonary embolism

**Address for correspondence:** Dr. Giulia Maj, Department of Anesthesia and Intensive Care, Sant'Antonio e Biagio e Cesare Arrigo Hospital, Via Venezia 16, Alessandria - 15121, Italy.

E-mail: giuliamaj81@gmail.com

**Submitted:** 23-Sep-2020 **Revised:** 19-Mar-2021 **Accepted:** 10-May-2021 **Published:** 11-Apr-2022

## INTRODUCTION

Pulmonary embolism (PE) is a common and potentially fatal cardiovascular disorder that must be promptly diagnosed and treated.<sup>[1]</sup> Management of PE in pregnant women is still challenging. We report the case of a pregnant woman with a high-risk PE that occurred in the third trimester.

## CASE HISTORY

A 35-year-old pregnant woman at the 34<sup>th</sup> week of gestation was admitted to the emergency department of our hospital because of worsened dyspnea on exertion starting approximately 20 days before. She had tachycardia

while oxygen saturation and the other cardiovascular parameters were normal. Her previous medical history was not remarkable. Despite surgeon advice to continue monitoring the patient and performing the diagnostic test as transthoracic echocardiography, she refused to be hospitalized. The day after, she was urgently admitted to the Department of Obstetrics due to worsening dyspnea and tachycardia. At admission, oxygen saturation was 97% on room air, blood pressure was 120/70 mmHg, and heart rate was 110 bpm. Among laboratory findings, only leucocytes ( $12.14 \times 1000/\text{mL}$ ), and d-dimer (10.59 mcg/mL) were slightly elevated. The electrocardiogram and transthoracic echocardiogram were normal. Nevertheless,

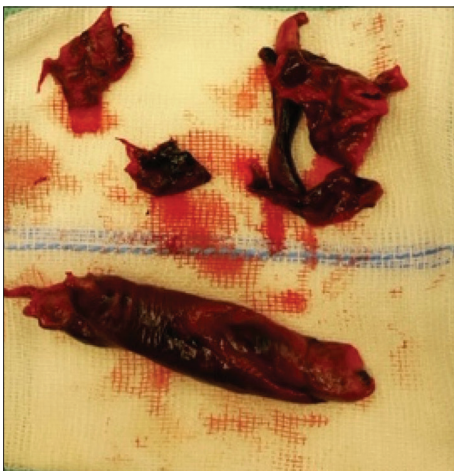This is an open access journal, and articles are distributed under the terms of the Creative Commons Attribution-NonCommercial-ShareAlike 4.0 License, which allows others to remix, tweak, and build upon the work non-commercially, as long as appropriate credit is given and the new creations are licensed under the identical terms.

**For reprints contact:** WKHLRPMedknow\_reprints@wolterskluwer.com

**How to cite this article:** Maj G, Strobelt N, Audo A, Arena AM, Parodi G, Aguggia V, *et al.* Surgical embolectomy in a 34-week pregnant woman with high risk pulmonary embolism and haemodynamic instability. *Ann Card Anaesth* 2022;25:225-8.

Access this article online	
Quick Response Code:	Website: www.annals.in
	DOI: 10.4103/aca.aca_244_20

after 12 h, she developed syncope and her parameters worsened: the oxygen saturation dropped to 71% with a  $\text{PaO}_2$  of 44 mmHg and a  $\text{PCO}_2$  of 26 mmHg on room air. Blood pressure was 80/50 mmHg and the heart rate increased up to 130 bpm. She required high-flow oxygen therapy to reach an oxygen saturation of 93% and fluid load to improve the blood pressure. At this stage, the angio-computed tomography (CT) scan revealed a bilateral massive PE. The thrombus involved and partially occluded both right, left, and even the main pulmonary artery trunk [Figure 1]. Fetal well-being was assessed through cardiotocography and sonographic observation of active fetal movements. On a multidisciplinary consultation, therapeutic options were discussed on the basis of three main issues: Treat massive embolism as soon as possible, deliver her baby to prevent uterine and placental hypoperfusion in case of maternal cardiac failure, risk of maternal cardiac failure after cesarean section because of the expected blood redistribution during the third stage of labor. The patient was transferred to the operating theater. We decided to deliver the neonate with a cesarean section and to prepare at the same time the mother for the surgical embolectomy. After the general anesthesia induction, the sternotomy and the cannulation of the ascending aorta and superior and inferior vena cava were performed. During the thoracic surgery, the fetus was monitored by cardiotocography that detected fetal bradycardia. The cesarean section was thus immediately carried out in order to prevent fetal hypoxia. A healthy neonate (2 kg and APGAR score APGAR score of 8 at 10 min) was delivered. Placental delivery and uterine suturing were uneventful. Immediately after the delivery, transesophageal echocardiography showed a severe right heart dysfunction with a markedly increased right ventricle dilatation and a paradoxical movement of interventricular septum. The cardiopulmonary bypass was then rapidly started through

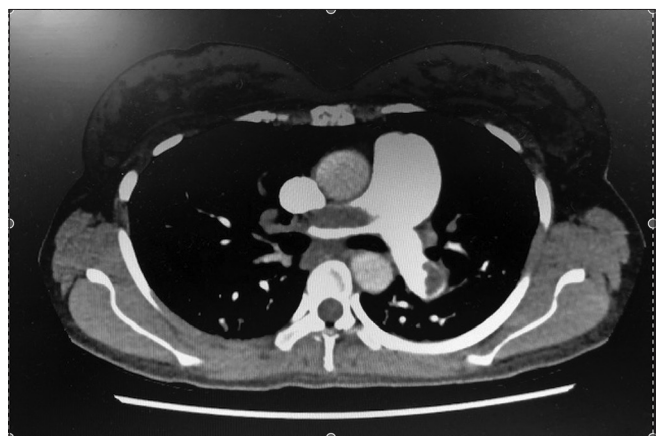


**Figure 1:** Clots removed from the pulmonary artery

the cannulation of the right atrium and the ascending aorta. The embolectomy was performed through a longitudinal pulmonary arteriotomy extending into the left pulmonary artery [Figure 2]. During the cardiopulmonary bypass, the surgeon performed a bimanual uterine compression to prevent uterine atony. The uterine contraction was achieved by administering an intravenous bolus of 100 micrograms of carbetocin (1-desamino-1-mono carba-2-(0-methyl)-tyrosine oxytocin), followed by sulprostone (analog of prostaglandin E2) intravenous infusion at a rate of 250 micrograms/h. The patient was successfully weaned from the cardiopulmonary bypass with dobutamine at a dose of 4 micrograms/kg/min and enoximone at a dose of 5 micrograms/kg/min, started for the persistent right ventricular dysfunction. She was extubated 8 h later. On day 2, we performed a CT scan of the lower body revealing left iliac deep venous thrombosis; inotropes were stopped and she was discharged from the intensive care unit. On day 5, intravenous unfractionated heparin was shifted to enoxaparin 6,000 ui international unit twice a day. The transthoracic echocardiography, performed during the postoperative course, revealed a complete recovery of the right ventricle function (Tricuspid annular plane excursion TAPSE 20 mm, TDI 11 cm/s). After 13 days, she was discharged.

## DISCUSSION

The risk of venous thromboembolism (VTE) is higher in all stages of pregnancy compared to the non-pregnant population, mainly during the third trimester and peripartum period. VTE can manifest as an isolated deep vein thrombosis more often left-sided (usually pelvic and/or at lower extremity level) or as PE that has a wide variety of presenting features, ranging from asymptomatic to sudden death.<sup>[2]</sup>



**Figure 2:** CT scan imaging showing bilateral massive pulmonary embolism

The non-specific PE presentation is magnified during pregnancy due to an overlap between symptoms seen in patients with PE and those associated with the normal physiologic changes of pregnancy, such as dyspnea, tachycardia, and tachypnea.<sup>[3]</sup> Moreover, the negative predictive value of d-dimer in ruling out PE is not useful during pregnancy due to the physiologically increased d-dimer levels. Finally, the diagnosis of PE is partially challenged by the need to limit the use of radiations for CT scan. The acute development of symptoms may favor the clinical suspicion for PE rather than pregnancy-related symptoms.

Although our patient was still hemodynamically stable at the beginning of her evaluation, showing only exertional dyspnea, tachycardia, and increased levels of d-dimer, she had a syncope a few hours later and became hypotensive and hypoxic. The angio-TC was immediately performed.<sup>[4]</sup> This test can be safely performed because it falls below the minimum radiation dose of 50 mSv (50,000  $\mu$ Gy) that could harm the fetus.<sup>[5]</sup>

In patients with PE who are hemodynamically unstable, more aggressive therapies rather than only anticoagulation are suggested including the following: (1) systemic thrombolytic therapy, (2) catheter-directed thrombolytic therapy, (3) catheter-based embolectomy, and (4) surgical embolectomy.<sup>[4]</sup>

Systemic thrombolysis is considered the treatment of choice for high-risk patients but it represents a debatable approach during pregnancy due to high hemorrhage risk for both the mother and the fetus. While catheter-directed thrombolytic might decrease such a high hemorrhagic risk, its use is still only anecdotal for pregnant patients.<sup>[3]</sup>

Surgical or catheter-based embolectomy is appropriate for those in whom thrombolysis is either contraindicated or unsuccessful. However, catheter-based embolectomy, such as thrombus fragmentation combined with thrombus aspiration and catheter-directed thrombolysis, is most commonly utilized in patients with moderate/intermediate-risk PE. Moreover, although rare, catheter fragmentation can increase pulmonary vascular pressures likely via embolization of larger fragments into the distal branches of the pulmonary vascular bed.<sup>[6,7]</sup>

Surgical embolectomy is also still an approach under study in pregnant women given the lack of solid literature supporting its use. Saeed G, *et al.* reported the largest series ( $n = 13$  patients) of massive PE during pregnancy treated with surgical embolectomy. Maternal and fetal

mortality was 15.4 and 23%, respectively. Surgical embolectomy has been historically considered as a rescue approach for patients in whom thrombolysis failed.<sup>[8]</sup> However, this approach is now also indicated as a possible first-line treatment for massive PE in patients with a high risk of bleeding or with thrombus-in-transit due to the reduced mortality rates recently reported.<sup>[9]</sup>

In our case, reducing the risk of peri-procedural bleeding was the key, given the high probability of significant blood loss during and after delivery. Moreover, it was a massive PE. Thus, we decided to perform straight surgical embolectomy instead of other techniques for the severe and refractory hemodynamic instability.

The woman was at the 34<sup>th</sup> week of pregnancy and the infant was considered at a good stage of its physiological maturity. In this setting, the delivery can be considered the first intervention to do but attention should be paid on the hemodynamic impact of the delivery itself. Indeed, following delivery, there is an immediate rise in venous return due to relief of the inferior vena cava obstruction and contraction of the uterus, which empties blood into the systemic circulation. The sudden increase on venous return may worsen the right ventricle dilatation leading to a volume overload on top of its pressure overload due to the PE, as happened in our case. For this reason, cardiopulmonary bypass cannulas should be secured before the delivery in order to start cardiopulmonary bypass as soon as the neonate is delivered.

Finally, our successful case supports the need for an aggressive and multidisciplinary approach in case of massive PE during pregnancy. This can be obtained by the implementation of a pulmonary embolism response team (PERT) to allow prompt coordination among different stakeholders.<sup>[10]</sup>

#### **Declaration of patient consent**

The authors certify that they have obtained all appropriate patient consent forms. In the form the patient(s) has/have given his/her/their consent for his/her/their images and other clinical information to be reported in the journal. The patients understand that their names and initials will not be published and due efforts will be made to conceal their identity, but anonymity cannot be guaranteed.

#### **Financial support and sponsorship**

Nil.

#### **Conflicts of interest**

There are no conflicts of interest.

## REFERENCES

1. Say L, Chou D, Gemmil A, Tuncalp O, Moller AB, Daniels J, *et al.* Global causes of maternal death: A WHO systematic analysis. *Lancet Glob Health* 2014;2:323-33.
2. Marik PE, Plante LA. Venous thromboembolic disease and pregnancy. *N Engl J Med* 2008;359:2025-33.
3. Krishnamurthy P, Martin CB, Kay HH, Diesner J, Friday RO, Weber CA, *et al.* Catheter-directed thrombolysis for thromboembolic disease during pregnancy: A viable option. *J Matern Fetal Med* 1999;8:24-7.
4. Konstantinides SV, Meyer G, Becattini C, Bueno H, Geersing GJ, Harjola VP, *et al.* 2019 ESC guidelines for the diagnosis and management of acute pulmonary embolism developed in collaboration with the European respiratory society (ERS): The task force for the diagnosis and management of acute pulmonary embolism of the European society of cardiology (ESC). *Eur Respir J* 2019;54:1901647.
5. Marik PE, Plante LA. Venous thromboembolic disease and pregnancy. *N Engl J Med* 2008;359:2025-33.
6. Nakazawa K, Tajima H, Murata S, Kumita SI, Yamamoto T, Tanaka K. Catheter fragmentation of acute massive pulmonary thromboembolism: Distal embolisation and pulmonary arterial pressure elevation. *Br J Radiol* 2008;81:848-54.
7. Saeed G, Möller M, Neuzner J, Gradaus R, Stein W, Langebrake U, *et al.* Emergent surgical pulmonary embolectomy in a pregnant woman: Case report and literature review. *Tex Heart Inst J* 2014;41:188-94.
8. Kumar N, Janjigian Y, Schwartz DR. Paradoxical worsening of shock after the use of a percutaneous mechanical thrombectomy device in a postpartum patient with a massive pulmonary embolism. *Chest* 2007;132:677-9.
9. te Raa GD, Ribbert LS, Snijder RJ, Biesma DH. Treatment options in massive pulmonary embolism during pregnancy; a case-report and review of literature. *Thromb Res* 2009;124:1-5.
10. Mahar JH, Haddadin I, Sadana D, Gadre A, Evans N, Hornacek D, *et al.* A Pulmonary embolism response team (PERT) approach: Initial experience from the Cleveland clinic. *J Thromb Thrombolysis* 2018;46:186-92.