



The Brazilian Journal of INFECTIOUS DISEASES

www.elsevier.com/locate/bjid



Clinical image

The halo sign of Q fever pneumonia



Yi Zhang, Guo-Qing Zang, Zheng-Hao Tang, Yong-Sheng Yu*

Department of Infectious Diseases, Shanghai Jiao Tong University Affiliated Sixth People's Hospital, Shanghai, PR China

ARTICLE INFO

Article history:

Received 13 October 2014

Accepted 16 November 2014

Available online 17 December 2014

A previously healthy 29-year-old male in intimate contact with dogs presented with a five-day history of high fever, chills, headache, myalgia and nonproductive cough. He also complained of sharp right-sided chest pain worse on deep inspiration. On physical examination, the patient was febrile, tachypneic and tachycardic. Inspiratory rales were heard over the right lower lung zone. Laboratory data showed a white blood cell (WBC) count of $6.6 \times 10^9/L$ with a left shift. Inflammatory markers were mildly elevated with erythrocyte sedimentation rate (ESR) 37 mm/h and C-reactive protein (CRP) 32 mg/L. A computed tomography (CT) scan of the chest revealed a 3 cm \times 3 cm, well-defined and round mass surrounded by a halo of ground-glass attenuation, namely the halo sign, in the posterior basal segment of the right inferior lobe (Fig. 1). Serologic test was positive for *Coxiella burnetii* (*C. burnetii*) by indirect immunofluorescence assay (IFA). Empirical treatment was initiated with azithromycin (0.5 g daily), which was changed to doxycycline (100 mg twice a day) for 14 days. A follow-up CT scan performed four weeks later showed total resolution of the lesions. At six-month follow-up, the patient was asymptomatic with no radiological evidence of a relapse.

Pneumonia is one of the cardinal manifestations of Q fever, which caused by *C. burnetii* infection.¹ Q fever is probably the most common cause of round pneumonia in adults.² The halo sign refers to a zone of ground-glass attenuation surrounding the circumference of a pulmonary nodule or mass on

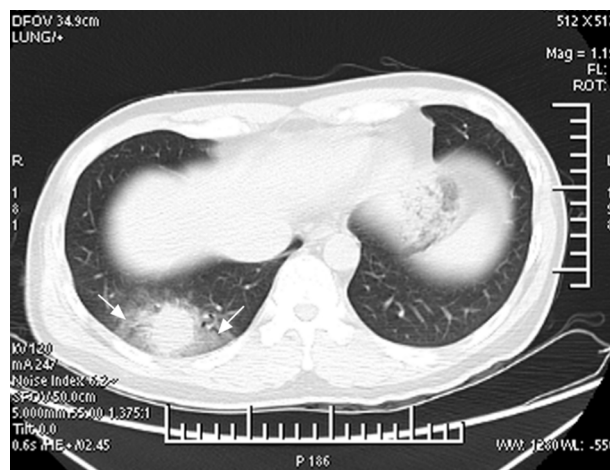


Fig. 1 – Computed tomography (CT) scan of the chest showing a 3 cm \times 3 cm, well-demarcated and spherical mass in the posterior basal segment of the right inferior lobe surrounded by a wide zone of ground-glass opacities (arrows), the halo sign.

CT images.^{3,4} It has been attributed to hemorrhagic lesions mainly caused by an infectious process.¹ *C. burnetii* infection can exceptionally manifest with a halo sign, which is caused by the infiltration of inflammatory cells and exudates into the

* Corresponding author at: Department of Infectious Diseases, Shanghai Jiao Tong University Affiliated Sixth People's Hospital, 600 Yishan Road, Shanghai 200233, PR China.

E-mail address: yuyongsheng@medmail.com.cn (Y.-S. Yu).

<http://dx.doi.org/10.1016/j.bjid.2014.11.001>

1413-8670/© 2015 Published by Elsevier Editora Ltda.

lung.⁴ Importantly, the halo sign is a useful diagnostic clue and may be good evidence of Q fever pneumonia.

Conflicts of interest

The authors declare no conflicts of interest.

Acknowledgement

This work was partly supported by the Medical Education Research Project of Shanghai Jiao Tong University School of Medicine (No. YB130910).

REFERENCES

1. Voloudaki AE, Kofteridis DP, Tritou IN, Gourtsoyiannis NC, Tselentis YJ, Gikas AI. Q fever pneumonia: CT findings. *Radiology*. 2000;215:880–3.
2. Antón E. A frequent error in etiology of round pneumonia. *Chest*. 2004;125:1592–3.
3. Pinto PS. The CT halo sign. *Radiology*. 2004;230:109–10.
4. Parrón M, Torres I, Pardo M, Morales C, Navarro M, Martínez-Schmizcraft M. The halo sign in computed tomography images: differential diagnosis and correlation with pathology findings. *Arch Bronconeumol*. 2008;44:386–92.