



# Ultrasonography of Malignant Clear Cell Hidradenoma: A Case Report

악성 한선종의 초음파 소견: 증례 보고

Taehyuk Ham, MD<sup>1</sup> , Sang-jin Cheon, MD<sup>2</sup> ,  
 Mee Sook Roh, MD<sup>3</sup> , Dong-ho Ha, MD<sup>1\*</sup> 

Departments of <sup>1</sup>Radiology, <sup>3</sup>Patholgy, Dong-A University Hospital, Busan, Korea

<sup>2</sup>Department of Dermatology, Yangsan Pusan National University Hospital, Yangsan, Korea

Clear cell hidradenoma is a tumor that originates from a sweat gland and typically involves the dermis and subcutaneous tissue. Malignant clear cell hidradenoma is very rare, and surgical excision is usually performed without imaging. There are few reports of the ultrasonographic findings of malignant clear cell hidradenomas. Herein, we present the ultrasonographic characteristics of a malignant clear cell hidradenoma.

**Index terms** Acrospiroma; Clear-Cell Hidradenoma; Echography; Ultrasound

## INTRODUCTION

Clear cell hidradenoma is a rare tumor that originates from a sweat gland and is usually benign. Ultrasonographically, clear cell hidradenomas present as well-defined cystic masses with mural nodules or as well-defined solid tumors. Hypervascularity is also frequently observed via Doppler examination (1). There are few reports of the sonographic characteristics of malignant clear cell hidradenomas owing to their rarity and because they are commonly removed without imaging. Herein, we present a case of a malignant clear cell hidradenoma in the left arm of a 48-year-old woman. She had a mass excised 2 years prior, which had recurred 1 year later.

## CASE REPORT

A 48-year-old woman presented with a solitary soft nodule in her left arm. Two years prior, she had noticed a nodule at the same location, which had been excised without pathological confirmation and with no reported complications. She had no remarkable medical or family history. A year after the first excision, the lesion recurred. The recur-

Received May 29, 2018  
 Revised October 28, 2018  
 Accepted September 2, 2019

\*Corresponding author

Dong-ho Ha, MD  
 Department of Radiology,  
 Dong-A University Hospital,  
 26 Daesingongwon-ro, Seo-gu,  
 Busan 49201, Korea.


Tel 82-51-240-5360

Fax 82-51-240-3561

E-mail [hdhdoc@damc.or.kr](mailto:hdhdoc@damc.or.kr)


This is an Open Access article distributed under the terms of the Creative Commons Attribution Non-Commercial License (<https://creativecommons.org/licenses/by-nc/4.0>) which permits unrestricted non-commercial use, distribution, and reproduction in any medium, provided the original work is properly cited.

### ORCID iDs

Taehyuk Ham 

<https://>

[orcid.org/0000-0002-3432-2177](https://orcid.org/0000-0002-3432-2177)

Sang-jin Cheon 


<https://>

[orcid.org/0000-0002-6099-4460](https://orcid.org/0000-0002-6099-4460)

Mee Sook Roh 

<https://>

[orcid.org/0000-0002-5676-5569](https://orcid.org/0000-0002-5676-5569)

Dong-ho Ha 

<https://>

[orcid.org/0000-0002-5645-9211](https://orcid.org/0000-0002-5645-9211)

ring lesion gradually grew and exhibited bloody discharge, but no inflammatory symptoms such as tenderness were noted. The lesion was approximately  $1.0 \times 1.2$  cm in size, flesh-colored, round-shaped with a small erythematous ulcer, and exhibited a small amount of discharge at the apex (Fig. 1A).

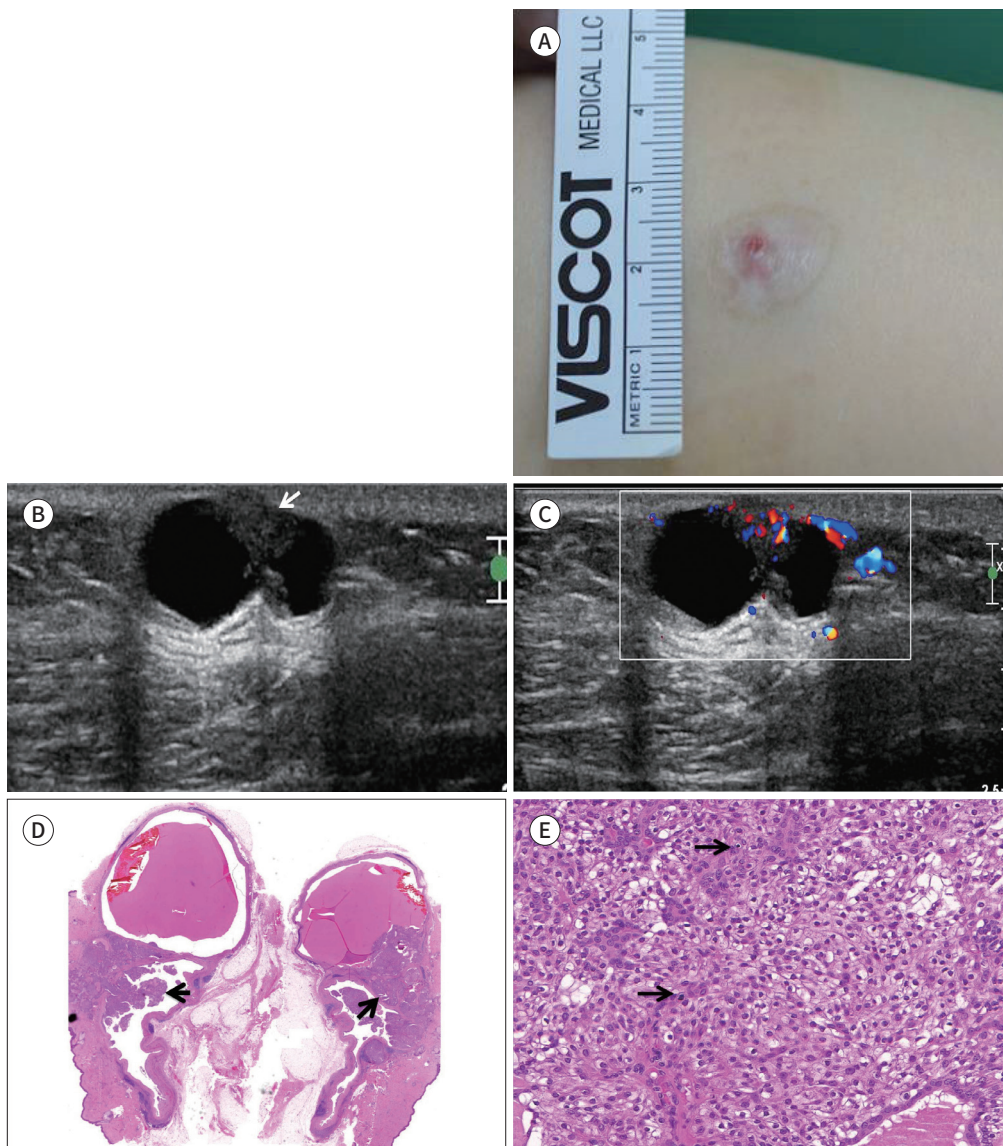
Radiographs of the left arm revealed no remarkable findings such as calcification or mass density in the soft tissue or bone. Ultrasonography (iU22 unit; Philips Medical Systems, Bothell, WA, USA) revealed a well-defined,  $1.8 \times 0.8$  cm-sized lobulated lesion in the dermis and subcutaneous tissue. The lesion had cystic portions, which exhibited posterior acoustic enhancement (Fig. 1B). A solid region with increased vascularity was noted in the superficial and central areas of the lesion (Fig. 1C). No hyperechogenicity indicating calcification was observed.

Given that this was a recurrent mass and ultrasonography revealed a solid portion with increased vascularity, an excisional biopsy was performed. The biopsy specimen comprised a section of skin measuring  $1.7 \times 1.0 \times 1.0$  cm. Microscopically, two discrete cystic structures within the dermis and subcutaneous tissue were observed. Adjacent to the cystic structures, cell proliferation with an infiltrative growth pattern was noted (Fig. 1D). Some cells exhibited clear cytoplasm with evidence of mitosis. Mitotic activity was apparent in approximately 2 cells in every 10 high-power microscopy fields (Fig. 1E). These findings were compatible with a malignant sweat gland tumor, specifically a malignant clear cell hidradenoma. For definitive treatment, Mohs micrographic surgery was performed 2 months later. There was no residual tumor, and all resection margins were free.

## DISCUSSION

Malignant clear cell hidradenoma is a very rare tumor; to date, just over 100 cases have been reported (2). There are three types of sweat glands—eccrine, apocrine, and mixed type—and clear cell hidradenomas originate from eccrine glands (1, 3). Clear cell hidradenoma is known by many names, including nodular hidradenoma, solid-cystic hidradenoma, poroid hidradenoma, and acrospiroma. Furthermore, various terms have been used to refer to malignant clear cell hidradenoma, including malignant clear cell hidradenoma, hidradenocarcinoma, clear cell papillary carcinoma, malignant clear cell acrospiroma, malignant eccrine acrospiroma, primary mucoepidermoid carcinoma of the skin, nodular hidradenocarcinoma, clear cell eccrine carcinoma, and mucoepidermoid hidradenocarcinoma (2). The typical histological locations of clear cell hidradenoma are the dermal and superficial subcutaneous fat layers. The lesion is usually a single, slow-growing, well-marginated, round, mobile, cutaneous nodule, with a diameter ranging from 0.5 to 3.0 cm (2, 4). Clear cell hidradenomas can be malignant. Nazarian et al. (5) recently reported a number of specific histological features of malignant clear cell hidradenomas as follows: infiltrative growth pattern, deep extension, necrosis, nuclear pleomorphism, and  $\geq 4$  mitoses per 10 high-power microscopy fields. Notwithstanding the small number of reported cases and limited follow-up information available, an aggressive clinical course characterized by repeated local recurrences and systemic metastasis has been documented (5). Due to the low incidence of these tumors, the reported characteristic radiological features of hidradenomas are based on only a few cases (1).

**Fig. 1.** A 48-year-old woman presented with malignant clear cell hidradenoma in her left arm.  
**A.** A 1.0 × 1.2-cm flesh-colored, round lesion with a small erythematous ulcer on the left upper arm.  
**B.** Ultrasonography shows a 1.8 × 0.8 cm well-circumscribed, lobulated, cystic lesion in the dermis and subcutaneous tissue. A solid portion (arrow) is noted in the central and superficial areas.  
**C.** The solid portion exhibits increased vascularity in a color Doppler examination.  
**D.** Microscopically, two discrete cystic structures are noted, and cell proliferation and an infiltrative growth pattern (arrows) are apparent adjacent to these cysts (H&E stain, × 20).  
**E.** Some of the cells exhibited clear cytoplasm and mitosis (arrows) (H&E stain, × 100).  
 H&E = hematoxylin and eosin



Cho et al. (6) suggested that ultrasonographically, benign hidradenomas typically present as well-defined cystic masses with mural nodules, or as well-defined solid tumors with hypoechogenicity. A mural nodule in a cystic lesion is also frequently highly vascularized as determined via Doppler examination. The echogenicity of the cystic portion may be complex due to a hemorrhagic component. In addition, calcifications have been reported in some cases (6).

Reier et al. (7) reported the MRI appearance of a clear cell hidradenoma as a solitary or multilocular cystic mass with a solid mural nodule. Fluid-fluid level and hemorrhaging have also been observed (7). The differential diagnosis of benign and malignant clear cell hidradenoma is difficult without distant metastasis or aggressive local invasion (8). Thus, failure to diagnose such cases may result in an aggressive clinical course.

The sonographic characteristics of malignant clear cell hidradenomas have rarely been reported. Ha et al. (9) demonstrated, using ultrasonography, that a malignant clear cell carcinoma is a well-defined cystic lesion with heterogeneous echogenicity in the subcutaneous fat layer. Color Doppler imaging revealed that the solid component did not exhibit increased vascularity, and the cystic component was purely anechoic, suggesting hemorrhage. The present case appeared as a lobulated lesion with larger cystic components and smaller solid components in the dermis and subcutaneous tissue. The solid components exhibited increased vascularity. Thus, both cases showed complex cystic and solid components. Furthermore, the present case exhibited increased vascularity, a typical feature of clear cell hidradenoma.

No distinct ultrasonographic findings differentiating benign and malignant clear cell hidradenomas have been identified. Therefore, more cases are required to establish typical imaging findings that could be employed in the differential diagnosis of clear cell hidradenoma.

#### Author Contributions

Conceptualization, H.D., H.T.; formal analysis, R.M.S., C.S.; visualization, R.M.S., C.S.; writing—original draft, H.T., C.S.; and writing—review & editing, H.D.

#### Conflicts of Interest

The authors have no potential conflicts of interest to disclose.

#### REFERENCES

1. Jin W, Kim GY, Lew BL, Yang DM, Kim HC, Ryu JK, et al. Sonographic findings of an eccrine spiradenoma: case report and literature review. *J Ultrasound Med* 2008;27:813-818
2. LeBoit PE, Burg G, Weedon D, Sarasin A. *Pathology and genetics of skin tumours*. Lyon: IARC press 2006
3. Grampurohit VU, Dinesh U, Rao R. Nodular hidradenoma of male breast: cytohistological correlation. *J Cytol* 2011;28:235-237
4. Mullaney PJ, Becker E, Graham B, Ghazarian D, Riddell RH, Salonen DC. Benign hidradenoma: magnetic resonance and ultrasound features of two cases. *Skeletal Radiol* 2007;36:1185-1190
5. Nazarian RM, Kapur P, Rakheja D, Piris A, Duncan LM, Mihm MC Jr, et al. Atypical and malignant hidradenomas: a histological and immunohistochemical study. *Mod Pathol* 2009;22:600-610
6. Cho KE, Son EJ, Kim JA, Youk JH, Kim EK, Kwak JY, et al. Clear cell hidradenoma of the axilla: a case report with literature review. *Korean J Radiol* 2010;11:490-492
7. Reier AR, Farooki S, Ashman CJ, Miles L. MR imaging appearance of plantar eccrine acrospiroma (sweat gland tumor). *AJR Am J Roentgenol* 2002;179:1079-1080
8. Hernández-Pérez E, Cestoni-Parducci R. Nodular hidradenoma and hidradenocarcinoma. A 10-year review. *J Am Acad Dermatol* 1985;12:15-20
9. Ha J, Chung HW, Song JS. Clear cell hidradenoma and hidradenocarcinoma arising from benign hidradenoma: imaging findings of ultrasonography and CT. *J Korean Soc Radiol* 2019;80:768-772

## 악성 한선종의 초음파 소견: 증례 보고

함태혁<sup>1</sup> · 천상진<sup>2</sup> · 노미숙<sup>3</sup> · 하동호<sup>1\*</sup>

한선종은 땀샘에서 기원하는 종양으로 전형적으로 진피 및 피하층에 위치한다. 악성 한선종은 매우 드물다. 그리고, 보통 영상 검사 없이 수술적 절제 치료를 시행한다. 악성 한선종의 초음파 소견도 매우 드물게 보고되어 있다. 저자들은 악성 한선종의 초음파 소견을 보고하고자 한다.

동아대학교병원 <sup>1</sup>영상의학과, <sup>3</sup>병리과,  
<sup>2</sup>양산부산대학교병원 피부과