

First successful prevention of cardiopulmonary resuscitation during high-risk percutaneous coronary intervention by use of a pulsatile left ventricular assist device: baptism of fire of the iVAC2L device: a case report

Alexander Samol*, Stefanie Schmidt, Melanie Zeise, and Marcus Wiemer

Department of Cardiology and Critical Care Medicine, Johannes Wesling University Hospital, Ruhr University Bochum, Hans-Nolte-Str. 1, 32429 Minden, Germany

Received 8 October 2017; accepted 2 January 2018; online publish-ahead-of-print 24 January 2018

Introduction

Efforts in percutaneous coronary intervention (PCI) lead to interventional treatment of complex stenoses as an alternative to coronary bypass surgery. Nevertheless, complications during PCI can occur with sudden need for circulatory support. Circulatory support devices are helpful tools during high-risk PCI to generate additional output or maintain sufficient circulation in critical situations.

Case description

We report the case of the first successful prevention of cardiopulmonary resuscitation by use of transfemoral pulsatile ventricular assist device with up to 2l additional cardiac output during a high-risk PCI in an 80-year old man with complex stenosis and a history of ventricular fibrillation during prior coronary angiography.

Discussion

The device managed to maintain an adequate circulation during massive vasospasm and bradycardia. The iVAC2L seems to be a useful tool in high-risk PCI. Its general effect on haemodynamics and patients' outcome has to be evaluated in larger multi-centre studies.

Keywords

High-risk PCI • Circulatory support • Left ventricular assist device • Cardiopulmonary resuscitation • Case report

Learning points

- Complications during percutaneous coronary intervention (PCI) can occur with sudden need for circulatory support.
- Circulatory support devices are a helpful tool during high-risk PCI to generate additional output or maintain sufficient circulation in critical situations.
- The iVAC2L is a transfemoral pulsatile ventricular assist device with up to 2l additional cardiac output during a high-risk PCI that may be useful to maintain an adequate circulation during haemodynamic critical situations.

Introduction

The number of percutaneous coronary intervention (PCI) as a therapeutic alternative to coronary artery bypass grafting (CABG) in patients with complex coronary stenosis is increasing. Current guidelines recommend PCI in such patients with high level of evidence.¹ Nevertheless, occurrence of complication during high-risk PCI may lead to the need for extra corporal circulation or emergency switch to CABG. To protect patients' circulation and especially coronary perfusion during or after PCI procedures, several devices have been evaluated.

The use of intra-aortic balloon pump (IABP) is technically feasible for the interventional cardiologist, but current guidelines do not

* Corresponding author. Tel: +49 571 79053102, Fax +49 571 790293100, Email: alexander.samol@muehlenkreiskliniken.de. This case report was reviewed by Joseph Moutiris and Gianluigi Savarese.

© The Author(s) 2018. Published by Oxford University Press on behalf of the European Society of Cardiology.

This is an Open Access article distributed under the terms of the Creative Commons Attribution Non-Commercial License (<http://creativecommons.org/licenses/by-nc/4.0/>), which permits non-commercial re-use, distribution, and reproduction in any medium, provided the original work is properly cited. For commercial re-use, please contact journals.permissions@oup.com

recommend its general use anymore.² Intra-aortic balloon pump use in cardiogenic shock failed to reduce 30 day mortality,³ but several studies assumed a potential benefit in high-risk PCI.⁴⁻⁶

The use of alternative full support circulatory assist devices guarantees an adequate circulation at the expense of a complex setting including technicians during PCI, which is often only available in tertiary care centre, and show higher rates of adverse events compared to IABP.^{7,8} Extra-corporal life support (ECLS) devices are able to maintain a sufficient cardiac output (CO), but the effects for the heart are not only positive. They increase afterload and do not allow unloading of the left ventricle.

The implantation of a TandemHeart device (Cardiac Assist, Pittsburgh, PA, USA) is compared to ECLS less complex, but it requires at least an interventional cardiologist that is familiar with the trans-septal puncture manoeuvre, and it has more bleeding and ischaemic complications compared to IABP because of the larger insertion cannulae.⁹

An alternative is the Impella device which may reduce major adverse events after high-risk PCI compared to IABP.¹⁰

Pulsatile devices like the iVAC3L system (PulseCath BV, Amsterdam, The Netherlands) enable LV unloading and generate an additional CO up to 3 L/minute, but again the insertion requires surgical support for preparation of the right subclavian artery access.¹¹

The iVAC2L device (PulseCath BV, Amsterdam, The Netherlands) is able to generate an additional CO up to 2 L/minute.¹²

Its safety and feasibility has been reported very recently.¹³ It is inserted via a trans-femoral access with placement of the 17 Fr, 100 cm long single lumen catheter in the left ventricular outflow tract via the aortic valve.¹² During systole blood is aspirated from the left ventricle and in diastole it is directed back in the aortic arch.¹² The pulsatile function is steered by electrocardiogram (ECG) or aortic pressure; in contrast to the Impella 2.5 system (ABIOMED, Danvers, MA, USA) it generates a pulsatile flow, and it is driven and compatible with conventional IABP consoles, which are still available in many hospitals.^{9,12}

Timeline

Day Event

1	Diagnosis of severe coronary artery disease and occurrence of ventricular fibrillation (VF) during coronary angiography
2	Exclusion of relevant peripheral artery disease by computed tomography
5	High-risk percutaneous coronary intervention under use of the iVAC2L device, occurrence of massive vasospasm, bradycardia and ST elevation
6	Departure from intensive care unit in stable condition
7	Departure from hospital

Case report

We report on the case of an 80-year-old male former smoker admitted to our hospital with typical angina. The patient described a first

occurrence of symptoms after a pulmonary infection a couple of month ago associated with palpitations. Sick sinus syndrome was assumed due to symptoms of irregular tachycardia in combination with presyncope. Physical examination did not reveal any abnormalities of pulse, cardiac murmurs, or rale. Recurrent Holter ECG examinations did not detect any arrhythmias. The patient was treated with aspirin 100 mg/day, atenolol 25 mg/day, candesartan 8 mg/day, and hydrochlorothiazide 12.5 mg/day. Biomarkers of myocardial necrosis were not elevated; troponin T 9.6 pg/mL (cut off ≤ 14 pg/mL) and Creatine Kinase 85 U/L (cut off < 170 U/L). Coronary angiography revealed a relevant ostial stenosis of left circumflex artery (LCX) and haemodynamic relevant stenosis of an almost intermediate proceeding obtuse marginal artery (OM) (Figure 1). During invasive diagnostics, a massive vasospasm of the right coronary artery (RCA) occurred which led to ventricular fibrillation. The patient was successfully defibrillated with 360J. Coronary angiography was stopped and, despite of a normal left ventricular ejection fraction of 63%, high-risk PCI under circulatory support was planned for the next week. Treatment with atenolol was stopped. Relevant peripheral artery disease was excluded by computed tomography of the aortic bifurcation.

After the patient gave written informed consent, we placed a 6 Fr radial access on the right side. We decided to use the iVAC2L device for haemodynamic support during PCI and placed two ProGlide closure devices in the right femoral artery and inserted a SoloPath re-collapsible 13.5 Fr access system and inflated it to 19 Fr. A 5 Fr pigtail catheter was inserted over the aortic valve, and a stiff wire was placed in the left ventricle. Via stiff wire, the 100 cm, 17 Fr single lumen bidirectional flow catheter was placed in the left outflow tract with the catheter tip in the left ventricle and the bidirectional valve in the ascending aorta (Figure 2). The device was connected to

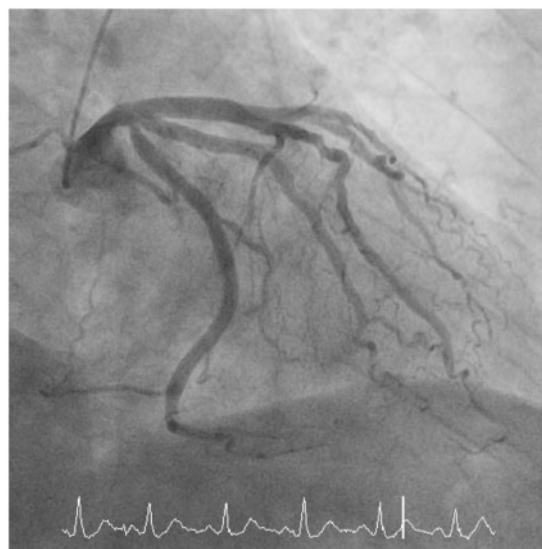


Figure 1 Coronary angiography before intervention: Relevant ostial stenosis of left circumflex artery and haemodynamic relevant stenosis of an almost intermediate proceeding obtuse marginal artery.

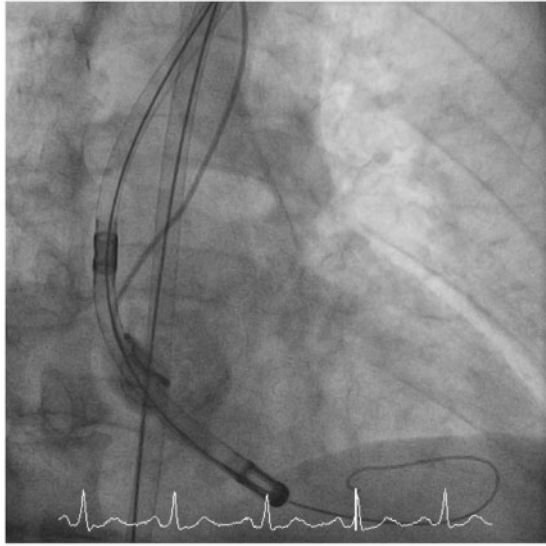


Figure 2 A stiffwire is placed in the left ventricle and the iVAC2L device is placed over the aortic valve.

our IABP console (Maquet Cardiovascular, Wayne, NJ, USA) and ECG-triggered pulsatile assist was started. Pressure curves in aortic position showed the typical notches in diastolic phase assuming correct device function. After a couple of minutes with correct device function, we placed a 6 Fr EBU 3.75 guidance catheter via right radial access; coronary wires were placed in left anterior descending artery (LAD), LCX, and OM. Suddenly, again a massive vasospasm of LAD and OM with temporary total occlusion of LAD and OM and slow flow in LCX occurred leading to bradycardia (35 b.p.m.), ST elevation, and decrease of blood pressure (*Figure 3*). The iVAC2L device worked well, no cardiopulmonary resuscitation (CPR) or inotropic agents were necessary. We were able to stabilize the patient with atropine i.v. and later nitrate bolus i.v. After 2 minutes vasospasm, ST elevations disappeared completely and the patient was again in stable haemodynamic condition. PCI with insertion of an ostial LCX drug-eluting stent and insertion of one drug-eluting balloon into the OM was performed with excellent primary results (*Figure 4*). The whole procedure was performed in a spontaneous breathing patient with only local anaesthesia in the radial and femoral access areas. Measurements of mean blood pressure showed an increase of 10 mmHg under 1:1 mechanical support. After PCI, the device catheter was removed from the aorta. The right femoral access sheath was collapsed and removed and the access was closed with the two ProGlide devices. We observed the patient on our intensive care unit until the next day, no complications in the region of artery accesses occurred. The patient left our hospital 2 days after PCI in good clinical condition.

Because of the assumed arrhythmia, 2 months later the patient underwent invasive electrophysiological examination in our hospital without any abnormal findings. At this point, the patient was free of any angina or cardiac symptoms.

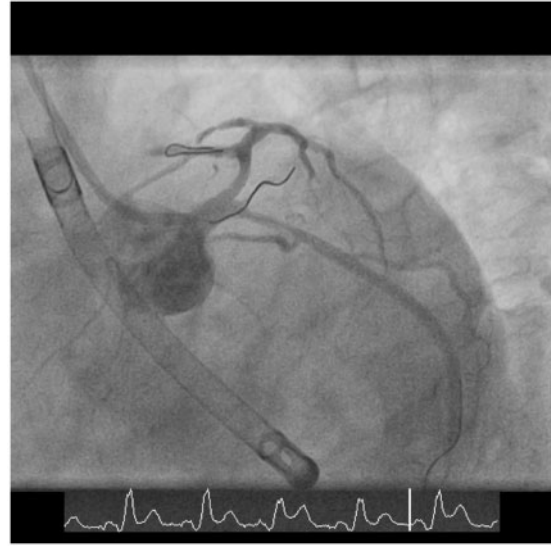

Figure 3 Occurrence of a massive vasospasm of left anterior descending artery and obtuse marginal artery, with temporary occlusion of left anterior descending artery and obtuse marginal artery and slow flow in left circumflex artery, ST elevation in electrocardiogram and bradycardia.

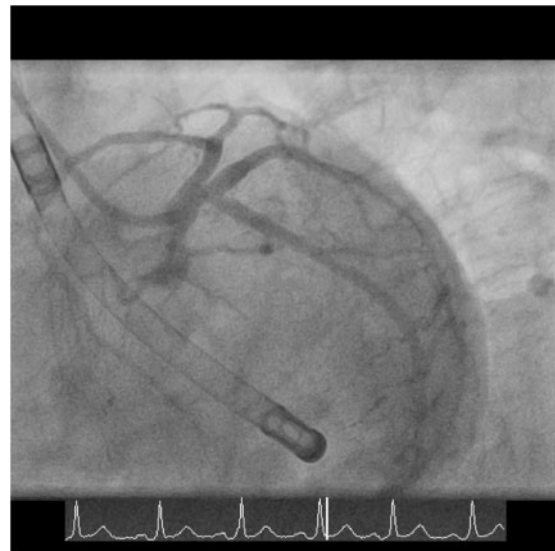


Figure 4 Angiographic results after intervention of the ostial left circumflex artery and the obtuse marginal artery.

Discussion

High-risk PCI is becoming an alternative to CABG.¹ The majority of surgical procedures are performed under extra-corporal circulation to guarantee sufficient blood flow. To enable sufficient CO and

coronary blood flow, especially during complex PCI settings, several devices have been developed.¹⁴ A few years ago the IABP was widely used and assumed to increase coronary perfusion and to generate an additional CO up to 0.5 L/minute. In randomized controlled trials, it failed to show lower mortality rates or circulatory benefit in cardiogenic shock settings³ and no additional positive effects were shown in a prophylactic implantation setting compare to stand-by use.⁴

As described above, the routinely use of IABP is not recommended anymore.² Left ventricular assist device or extra-corporal membrane oxygenation support during high-risk PCI is not well investigated and the implantation of the devices and the maintenance of the support are complex.¹⁴ Recently, we have reported the first use of the iVAC2L by interventional cardiologists during high-risk PCI in Germany¹⁵ and its safety and feasibility was shown in a single-centre study.¹³ Actually, we are able to report the first successful prevention of CPR during high-risk PCI. Thus, we cannot only assume a safe, feasible, and easy use of the iVAC2L device in combination with the 13 Fr sheet and the ProGlide device during PCI but also a positive haemodynamic benefit of the device.

The iVAC2L device may be a useful and efficient alternative to the IABP system and an alternative to the Impella 2.5. Its pulsatile flow and the larger lumen may provide a more sufficient left ventricular unloading and a lower haemolysis. It is easy use in combination with a standard IABP console that should be still available in most catheter labs.

On the other hand, the access sheath is significantly larger. Its additional CO is not comparable to a conventional ECMO system or the TandemHeart, but the implantation of the device is less complex without the need for cardiac technicians or additional trans-septal puncture manoeuvre.⁹

Thus, the circulatory support and patients' benefit of the iVAC2L device needs to be investigated in large multi-centre studies.

Consent: The author/s confirm that written consent for submission and publication of this case report including image(s) and associated text has been obtained from the patient in line with COPE guidance.

Conflict of interest: none declared.

References

1. Windecker S, Kolh P, Alfonso F, Collet JP, Cremer J, Falk V, Filippatos G, Hamm C, Head SJ, Jüni P, Kappetein AP, Kastrati A, Knuuti J, Landmesser U, Laufer G, Neumann FJ, Richter DJ, Schauerte P, Sousa Uva M, Stefanini GG, Taggart DP, Torracca L, Valgimigli M, Wijns W, Witkowski A. 2014 ESC/EACTS Guidelines on myocardial revascularization: the Task Force on Myocardial Revascularization of the European Society of Cardiology (ESC) and the European Association for Cardio-Thoracic Surgery (EACTS) Developed with the special contribution of the European Association of Percutaneous Cardiovascular Interventions (EAPCI). *Eur Heart J* 2014;**35**:2541–2619.
2. Ibanez B, James S, Agewall S, Antunes MJ, Bucciarelli-Ducci C, Bueno H, Caforio ALP, Crea F, Goudevenos JA, Halvorsen S, Hindricks G, Kastrati A, Lenzen MJ, Prescott E, Roffi M, Valgimigli M, Vahrenhorst C, Vranckx P, Widimski P; ESC Scientific Document Group. 2017 ESC Guidelines for the management of acute myocardial infarction in patients presenting with ST-segment elevation: the Task Force for the management of acute myocardial infarction in patients presenting with ST-segment elevation of the European Society of Cardiology (ESC). *Eur Heart J* 2017;**39**:119–177.
3. Thiele H, Zeymer U, Neumann F-J, Ferenc M, Olbrich H-G, Hausleiter J, de Waha A, Richardt G, Hennersdorf M, Empen K, Fuernau G, Desch S, Eitel I, Hambrecht R, Lauer B, Böhm M, Ebelt H, Schneider S, Werdan K, Schuler G. Intra-aortic balloon pump in cardiogenic shock. Intra-aortic balloon counterpulsation in acute myocardial infarction complicated by cardiogenic shock (IABP-SHOCK II): final 12 month results of a randomised, open-label trial. *Lancet* 2013;**382**:1638–1645.
4. Perera D, Stables R, Clayton T, De Silva K, Lumley M, Clack L, Thomas M, Redwood S. Long-term mortality data from the balloon pump-assisted coronary intervention study (BCIS-1): a randomized, controlled trial of elective coronary counterpulsation during high-risk percutaneous coronary intervention. *Circulation* 2013;**127**:207–212.
5. Mishra S, Chu WW, Torguson R, Wolfram R, Deible R, Suddath WO, Pichard AD, Satler LF, Kent KM, Waksman R. Role of prophylactic intra-aortic balloon pump in high-risk patients undergoing percutaneous coronary intervention. *Am J Cardiol* 2006;**98**:608–612.
6. Briguori C, Sarais C, Pagnotta P, Airolfo F, Liistro F, Sgura F, Spanos V, Carlino M, Montorfano M, Di Mario C, Colombo A. Elective versus provisional intra-aortic balloon pumping in high-risk percutaneous transluminal coronary angioplasty. *Am Heart J* 2003;**145**:700–707.
7. Thiele H, Sick P, Boudriot E, Diederich K-W, Hambrecht R, Niebauer J, Schuler G. Randomized comparison of intra-aortic balloon support with a percutaneous left ventricular assist device in patients with revascularized acute myocardial infarction complicated by cardiogenic shock. *Eur Heart J* 2005;**26**:1276–1283.
8. Seyfarth M, Sibbing D, Bauer I, Fröhlich G, Bott-Flügel L, Byrne R, Dirschinger J, Kastrati A, Schömig A. A randomized clinical trial to evaluate the safety and efficacy of a percutaneous left ventricular assist device versus intra-aortic balloon pumping for treatment of cardiogenic shock caused by myocardial infarction. *J Am Coll Cardiol* 2008;**52**:1584–1588.
9. Ergle K, Parto P, Krim SR. Percutaneous ventricular assist devices: a novel approach in the management of patients with acute cardiogenic shock. *Ochsner J* 2016;**16**:243–249.
10. O'Neill WW, Kleiman NS, Moses J, Henriques JP, Dixon S, Massaro J, Palacios I, Maini B, Mulukutla S, Dzavik V, Popma J, Douglas PS, Ohman M. A prospective, randomized clinical trial of hemodynamic support with Impella 2.5 versus intra-aortic balloon pump in patients undergoing high-risk percutaneous coronary intervention: the PROTECT II study. *Circulation* 2012;**126**:1717–1727.
11. Amico A, Brigiani MS, Vallabini A, Ferrante B, Marzovillo A, Loizzi D, Carbone C. PulseCath, a new short-term ventricular assist device: our experience in off-pump coronary artery bypass graft surgery. *J Cardiovasc Med (Hagerstown)* 2008;**9**:423–426.
12. Van Mieghem NM, Daemen J, Lenzen MJ, Zandstra R, Malkin O, van Geuns RJ. The PulseCath iVAC 2L left ventricular assist device: conversion to a percutaneous transfemoral approach. *EuroIntervention* 2015;**11**:835–839.
13. den Uil C, Daemen J, Lenzen M, Maugenes A-M, Joziassse L, van Geuns R, Van Mieghem N. Pulsatile iVAC 2L circulatory support in high-risk percutaneous coronary intervention. *EuroIntervention* 2017;**12**:1689–1696.
14. Jones HA, Kalisetti DR, Gaba M, McCormick DJ, Goldberg S. Left ventricular assist for high-risk percutaneous coronary intervention. *J Invasive Cardiol* 2012;**24**:544–550.
15. Samol A, Schmidt S, Zeise M, Durrwald S, Wiemer M. First high-risk percutaneous coronary intervention under use of the iVAC2L system in Germany. *Future Cardiol* 2017;**13**:117–123.