

## Ewing's sarcoma: an uncommon breast tumor

Sawsen Meddeb,<sup>1,2</sup>

Mohamed Salah Rhim,<sup>1</sup> Mouna Kouira,<sup>1</sup>

Sarra Mestiri,<sup>3</sup> Mohamed Bibi,<sup>1</sup>

Mohamed Tahar Yacoubi<sup>3</sup>

<sup>1</sup>Department of Gynecology and Obstetrics, Farhat Hached University Hospital; <sup>2</sup>Research Laboratory in Quality of Maternal Health Care in Tunisia; <sup>3</sup>Department of Pathology, Farhat Hached University Hospital, Sousse, Tunisia

### Abstract

Ewing's sarcoma/primitive neuroectodermal tumors (EWS/PNET) are rare malignant and aggressive tumors, usually seen in the trunk and lower limbs of children and young adults. They are uncommon in the breast. We report a case of a 43-year-old woman who developed a painless breast mass. An initial core needle biopsy concluded to a fibrocystic dystrophy contrasting with a rapidly growing mass; thus a large lumpectomy was done. Diagnosis of primary PNET of the breast was established, based on both histopathological examination and immunohistochemical findings. Surgical margins were positive, therefore, left modified radical mastectomy with axillary lymph nodes dissection was performed. The patient was given 6 cycles of adjuvant chemotherapy containing cyclophosphamide, adriamycin and vincristine. Twenty months later, she is in life without recurrence or metastasis. EWS/PNET may impose a diagnostic challenge. Indeed, mammography and ultrasonography features are non specific. The histopathological pattern is variable depending on the degree of neuroectodermal differentiation. Immuno-phenotyping is necessary and genetic study is the only confirmatory tool of diagnosis showing a characteristic cytogenetic anomaly; t (11; 22) translocation.

### Introduction

Ewing's sarcoma/primitive neuroectodermal tumors (EWS/PNET) represent a group of rare malignant tumors, probably arising from migrating embryonic cells of the neural crest and showing variable neuroectodermal differentiation. They usually arise in soft tissues or bone; commonly in children and adolescents.<sup>1</sup>

They are extremely rare in adults, but have been reported on the chest wall and other body parts. Breast location remains exceptional. We report here a new case primarily developed in the breast.

### Case Report

A 43-year-old woman para 2, with no family history of breast cancer presented with a rapidly enlarging mass in the left breast discovered one month previously. Physical examination revealed a hard, painless mass, measuring approximately 3 cm in diameter, located at the upper outer quadrant of the left breast. The remaining quadrants, the right breast and both axillary areas were clinically normal.

Mammography and ultrasonography revealed a superficial well defined oval mass with a soft tissue density and a hypoechoic center. An initial diagnosis of fibroadenoma was suspected and core needle biopsy concluded to a fibrocystic dystrophy. One month later, the patient complaint that the mass progressively grew to the size of 13 cm in diameter with inflammation of the overlying skin and a left axillary lymphadenopathy. Ultrasonographic examination revealed a 10 cm mass scattered with multiple fluid areas (Figure 1).

The patient underwent a large lumpectomy. A necrotic and slightly friable tumor measuring 9.7 cm was seen at the cut section. Histopathological examination showed a relatively well-circumscribed tumor, composed by sheets and lobules of malignant cells within distinct borders, amphophilic or eosinophilic cytoplasm sometimes vacuolated (Figure 2A) Nuclei are atypical either round open or hyperchromatic. Nucleoli were often seen. Mitoses were frequent, with sometimes abnormal figures (Figure 2B). Focal necrotic areas were identified. The stroma was loose with a prominent capillary network. The tumor had pushing margins and did not infiltrate the adjacent mammary parenchyma. No *in situ* carcinoma component was identified. Histochemical periodic acid-Schiff stain showed a granular cytoplasm without mucin. The morphological feature advocated the diagnosis of poorly differentiated carcinoma or neuroendocrine carcinoma or lymphoma or EWS/PNET. Extensive sampling was performed ruling out metaplastic carcinoma.

Immunohistochemical staining showed that tumor cells were positive for vimentin (V9, DAKO A/S, Glostrup, Denmark, 1/100), neuroendocrine markers such as neuron specific enolase (NSE) (H14, DAKO, 1/100), synaptophysin (Sy 38, DAKO, 1/20), CD99 (12E7, DAKO, 1/50) and Fl-1 (Rb-Poly, Springbio Ltd.,

Correspondence: Sawsen Meddeb, Department of Gynecology and Obstetrics, Farhat Hached University Hospital, Ibn Jazzar Street, 4000 Sousse, Tunisia.

Tel.: +216.98367637 - Fax: +216.73102503.

E-mail: meddeb.sawsen@yahoo.fr

Key words: primitive neuroectodermal tumor, Ewing's sarcoma, breast.

Contributions: SMI, conception, design, and acquisition of data; MSR, analysis and interpretation of data, article drafting; MK, SM2, article drafting; MB, manuscript critical revising; MTY, final approval.

Conflict of interests: the authors declare no potential conflict of interests.

Received for publication: 22 May 2014.

Revision received: 29 July 2014.

Accepted for publication: 4 August 2014.

This work is licensed under a Creative Commons Attribution NonCommercial 3.0 License (CC BY-NC 3.0).

©Copyright S. Meddeb et al., 2014

Licensee PAGEPress, Italy

Clinics and Practice 2014; 4:659

doi:10.4081/cp.2014.659

Portsmouth, UK, 1/50) (Figure 2C, D). They were negative for cytokeratin (AE1/AE3, Novocastra - Leica Biosystems GmbH, Nussloch, Germany, 1/50) and hormonal receptors (PgR 636, 1D5, DAKO, 1/40). Leucocyte common antigen (LCA) (M07001, DAKO, 1/100) was negative, excluding the diagnosis of lymphoma. None of the staining shown carcinoma in origin. This morphological and immunohistochemical findings were consistent with EWS/PNET. However, cytogenetic study in order to look for a characteristic translocation t (11; 22) was not performed because a genetic platform is not available in our institution. Surgical margins were positive, therefore, left modified radical mastectomy with axillary lymph nodes dissection was performed. Histopathological examination of the tumoral chamber didn't found any residual tumoral tissue. Thirteen lymph nodes were identified. Their architecture is conserved without any suspected infiltration by tumoral cells. Computed tomographic (CT) scan of the chest, abdomen and pelvis ruled out any extra mammary origin of the tumor such as bone, soft tissue or other organs. The patient was given 6 cycles of adjuvant chemotherapy containing cyclophosphamide, adriamycin and vincristine. She has been on regular follow up and after 20 months of surgery remains free of disease.

## Discussion

Carcinomas are the majority of malignancies involving the breast; sarcomas represent less than 1% of breast malignancies.<sup>2</sup> EWS/PNET of the breast is extremely rare, with several of primary tumors previously reported in the literature.<sup>3</sup>

EWS and PNET form a single group of bone and soft-tissue tumors [Ewing's sarcoma family of tumors (EFT)] with typical undifferentiated Ewing's sarcoma at one end of the spectrum and PNET with clear evidence of neural differentiation at the other.<sup>4</sup> This group of tumors is characterized by the presence of the typical translocation t (11; 22) (q24; q12), the EWS-FLI1 chimere transcript at the molecular biology and the expression of CD99 antigen (MIC2) at immunohistochemistry.<sup>5</sup>

Several studies of adult EWS/PNET from the Royal Marsden, the Memorial Sloan-Kettering and the Dana-Faber Cancer Centers have reported a median age of 24-27 years.<sup>6</sup> Our case revealed the age was slightly older which was at the age of 43. It has been suggested that, despite common genetic traits, EWS/PNET in a relatively advanced age group might arise from different precursor cells or appear at different developmental stages than typical EFT of adolescents and young adults. It is also possible that additional genetic changes that are critical for tumor progression or that influence patients' prognoses are different between typical EFT and those at unusual locations in adults.<sup>4</sup>

In relation to breast presentation of EWS/PNET, the most common is unilateral palpable mass in the breast, with a median dimension of 5 cm.<sup>6</sup> In the present case tumor's size was initially of 3 cm, than rapidly enlarged to reach 12 cm. Majid *et al.* reported one case of bilateral primary neuroectodermal tumor of the breast.<sup>7</sup>

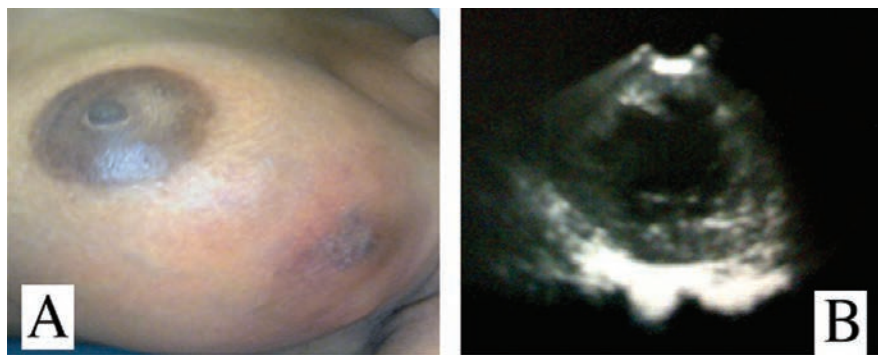
Mammography and ultrasonography features of EWS/PNET are non specific. They can vary from a hypoechoic mass with posterior enhancement to a heterogeneous mass with a necrotic area.<sup>8</sup> Maxwell *et al.* described sonographic findings of primary EWS/PNET of the breast as a superficial, circumscribed, hypoechoic mass with posterior acoustic enhancement and an apparent hypoechoic tract extending to the skin.<sup>9</sup> These lesions were misdiagnosed as an epidermal inclusion cyst and considered therefore as benign. In the present case, sonographic findings were different, displaying a well defined oval lump with a soft tissue density and a hypoechoic center. CT scan and magnetic resonance imaging (MRI) features of EWS/PNET are also non specific, usually showing a large, non calcified and heterogeneous soft tissue mass with cystic or necrotic areas on CT. On MRI, signal intensity

is similar to muscle on T1-weighted images and heterogeneously high on T2-weighted images, with variable gadolinium enhancement.<sup>10</sup>

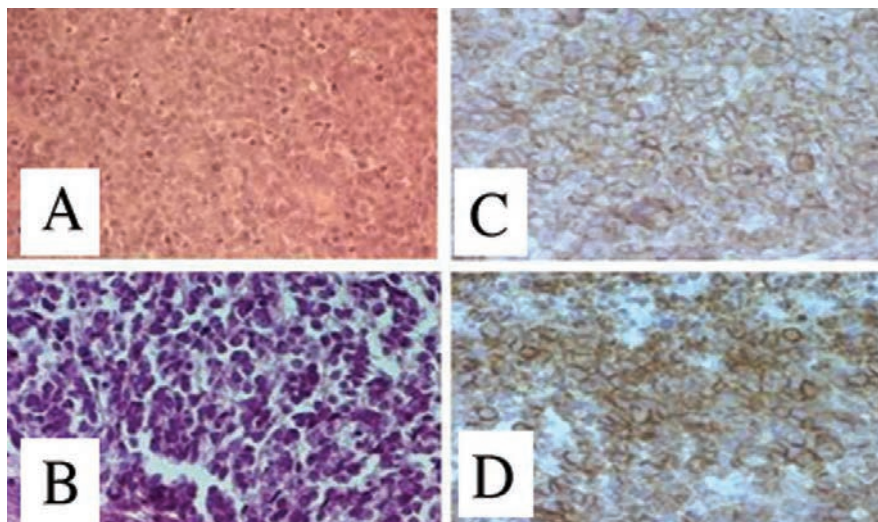
The histopathological pattern of EFT is variable depending on the degree of neuroectodermal differentiation. The tumor is arranged in sheets, lobules or trabeculae. Pseudo-rosettes can be seen. Cells vary from small, round cells with round nuclei, fine chromatin, scant cytoplasm and indistinct cell borders to larger cells with irregular nuclear contours. Mitotic activity is high. Necrosis may be present.<sup>11</sup> Primary EWS/PNET of the breast might be misdiagnosed as a small cell carcinoma, medullary carcinoma, poorly differentiated ductal or lobular carcinoma or ductal carcinoma with neuroendocrine differentiation owing to its morpholo-

gy and immunohistochemical characteristics. The possibility of a distant metastasis should also be raised.<sup>5</sup> Metaplastic carcinoma with neuroectodermal differentiation should be considered, so extensive sampling and immunohistochemical investigation are compulsory to do.<sup>12,13</sup>

Immuno-phenotyping is necessary to confirm the diagnosis of EWS/PNET, showing positivity of tumoral cells for vimentin, Fli-1 and CD99 (Mic-2).<sup>5</sup> CD99 is a cell surface glycoprotein involved in cell adhesion. It shows a membranous staining and seems playing a crucial role in the diagnosis of EWS/PNET.<sup>11</sup> It was initially thought to be highly specific for EWS/PNET, but it is now recognized that, although its sensitivity ranges from 84% to 100% in EWS/PNET, its specificity is limited.<sup>11</sup>



**Figure 1.** Goss and ultrasonographic features of the tumor. A) Large breast lump with inflammatory overlying skin. B) Breast masse tissular density scattered by fluid areas.



**Figure 2.** Histological and immunohistochemical features of the tumor. A) Hematoxylin and eosin (HE) x200: malignant proliferation of large cells with indistinct borders, pleomorphic and atypical nuclei, displaying high mitotic activity. B) HE x400: large to mild sized tumoral cells with hyperchromatic round nuclei and vacuolated cytoplasm. C and D) Immunohistochemistry x400: intense and diffuse immunostaining of tumor cells with CD99 and Fli-1 antibodies.

and may also be expressed in metaplastic carcinoma of the breast, neuroendocrine carcinoma, lymphoma and rhabdomyosarcoma.<sup>11</sup> EWS/PNET that are only immunoreactive to CD99, albeit rare, have been reported in the literature.<sup>5</sup> Reactivity for vimentin, NSE, CD57 and S100 may suggest diagnosis but are not pathognomonic. Cytokeratin is usually negative.<sup>5</sup>

Thus, histological and immunohistochemical examination is contributive to propose the diagnosis of PNET in most cases. However; genotypic analysis, by DNA- and RNA-based polymerase chain reaction, Southern blotting, and fluorescent *in situ* hybridization are the only confirmatory tools.<sup>4</sup>

Owing to these recent improvements in diagnostic ability, we now realize that EWS/PNET develops in diverse and previously unexpected locations and we should be able to detect more cases of EWS/PNET of the breast, some of which might have been diagnosed previously as small cell carcinomas or carcinomas with neuroendocrine differentiation.

EWS/PNET is an aggressive tumor with a high incidence of local recurrence and distant metastasis. A combination of multiple treatment modalities, including surgery, chemotherapy and radiation therapy, is indicated for these patients.<sup>6</sup> Systemic chemotherapy improves the 5-year survival rate in localized forms of PNET from 10% up to 65% which is primarily due to the elimination of micrometastases.<sup>14</sup> Although the optimum combination chemotherapy has not yet been established, a regimen containing vincristine, adriamycin, cyclophosphamide and actinomycin D, was the standard first-line treatment for patients with localized disease.<sup>14</sup> In patients with unresectable or metastatic disease, palliative chemotherapy may be useful.<sup>14</sup> The role

of radiation therapy in the treatment of PNET is unclear. However, it can be combined with surgery, in order to control local disease.<sup>8</sup>

## Conclusions

EWS/PNET are rare tumors developed in the breast, their diagnosis need immunohistochemical and genetic investigations. These ancillary techniques are necessary in order to rule out other types of malignant tumor owing poor prognosis and different way of management.

## References

1. Dehner LP. Primitive neuroectodermal tumor and Ewing's sarcoma. *Am J Surg Pathol* 1993;17:1-13.
2. Pollard SG, Marks PV, Temple LN, Thompson HH. Breast sarcoma. A clinicopathologic review of 25 cases. *Cancer* 1990;66:941-4.
3. Vindal A, Kakar AK. Primary primitive neuroectodermal tumor of the breast. *J Clin Oncol* 2010;28:e453-5.
4. Tamura G, Sasou S, Kudoh S, et al. Primitive neuroectodermal tumor of the breast: Immunohistochemistry and fluorescence *in situ* hybridization. *Pathol Int* 2007;57:509-12.
5. Folpe AL, Goldblum JR, Rubin BP, et al. Morphologic and immune phenotypic diversity in Ewing family tumors: a study of 66 genetically confirmed cases. *Am J Surg Pathol* 2005;29:1025-33.
6. Chuthapisith S, Prasert W, Warnnissorn M, et al. Ewing's sarcoma and primitive neuroectodermal tumour (ES/PNET) presenting as a breast mass. *Oncol Lett* 2012;4:67-70.
7. Majid N, Amrani M, Ghissassi I, et al. Bilateral Ewing sarcoma/primitive neuroectodermal tumor of the breast: a very rare entity and review of the literature. *Case Rep Oncol Med* 2013;2013:964568.
8. Da Silva BB, Lopes-Costa PV, Pires CG, et al. Primitive neuroectodermal tumor of the breast. *Eur J Obstet Gynecol Reprod Biol* 2008;137:248-9.
9. Maxwell RW, Ghate SV, Bentley RC, Soo MS. Primary primitive neuroectodermal tumor of the breast. *J Ultrasound Med* 2006;25:1331-3.
10. Winer-Muram HT, Kauffman WM, Gronemeyer SA, Jennings SG. Primitive neuroectodermal tumors of the chest wall (Askin tumors): CT and MR findings. *AJR Am J Roentgenol* 1993;161:265-8.
11. Milanezi F, Pereira EM, Ferreira FV, et al. CD99/MIC-2 surface protein expression in breast carcinomas. *Histopathology* 2001;39:578-83.
12. Tot T, Badani DE, La Parra JJ, Bergkvist L. Metaplastic carcinoma of the breast with neuroectodermal stromal component. *Pathol Res Int* 2011;2011:191274.
13. AbdullGaffar B, Ghazi E, Mohamed E, Hamza D. Breast metaplastic carcinoma with unusual small cell component. *Breast Dis* 2012;34:19-24.
14. Paulussen M, Ahrens S, Dunst J, et al. Localized Ewing tumor of bone: final results of the cooperative Ewing's sarcoma study CESS 86. *J Clin Oncol* 2001;19:1818-29.