



## Myometrial cysts: A case series

Lucy J. Green, Tervinder Sokhi, Moji Balogun, Raji Ganesan\*

Departments of Cellular Pathology and Radiology, Birmingham Women's and Children's NHS Foundation Trust, Mindelsohn Way, Birmingham, B15 2TG, UK



### ARTICLE INFO

#### Article history:

Received 25 September 2019

Received in revised form 9 October 2019

Accepted 11 October 2019

#### Keywords:

Myometrial  
Cyst  
Adenomyosis  
Hysterectomy  
Myomectomy  
MRI

### ABSTRACT

Cysts in the uterine wall are rare. They are detected by imaging or at pathological examination after myomectomy or hysterectomy. They encompass a range of underlying aetiologies. This is the first case series of myometrial cysts with a description of clinical, imaging and pathology findings.

Crown Copyright © 2019 Published by Elsevier B.V. This is an open access article under the CC BY-NC-ND license (<http://creativecommons.org/licenses/by-nc-nd/4.0/>).

### 1. Introduction

Myometrial cysts are rare and consequently little information on them has been reported in the literature. There have been handfuls of case reports focusing on specific diagnostic entities, namely cystic adenomyosis [1–3], but there is no case series encompassing the range of pathology encountered. We describe a series of 11 myometrial cysts detected either on imaging or at macroscopic assessment of surgical resection specimens at Birmingham Women's Hospital.

### 2. Methods

Both the laboratory information system and the picture archiving and communication system (PACS) radiology databases were searched. Within the laboratory information system and PACS, a text search for “myometrial cyst” in gynaecological specimens was performed for the period 2000–18. The radiology and histopathology reports were examined to confirm a myometrial cyst and to record the given histopathological diagnosis. Clinical details were obtained from the patients' clinical records for clinicopathological correlation.

### 3. Results

Eight cases were identified from the histopathology database and three from the PACS, resulting in a total of 11 cases (Figs. 1–4).

#### 3.1. Case 1

A 39-year-old woman presented with post-coital bleeding, intermenstrual bleeding and pelvic pain. MRI showed a cystic myometrial lesion separate from the endometrial cavity, measuring 14 cm. She had a total hysterectomy and bilateral salpingo-oophorectomy, which showed a multiloculated myometrial cyst measuring 50 mm, separate from the endometrial cavity. Histology demonstrated a multi-septated cyst with a flattened lining and focal identifiable adenomyosis in the wall. Focal adenomyosis was also seen within the adjacent myometrium. The final diagnosis was cystic adenomyosis or cystic change within an adenomyoma.

#### 3.2. Case 2

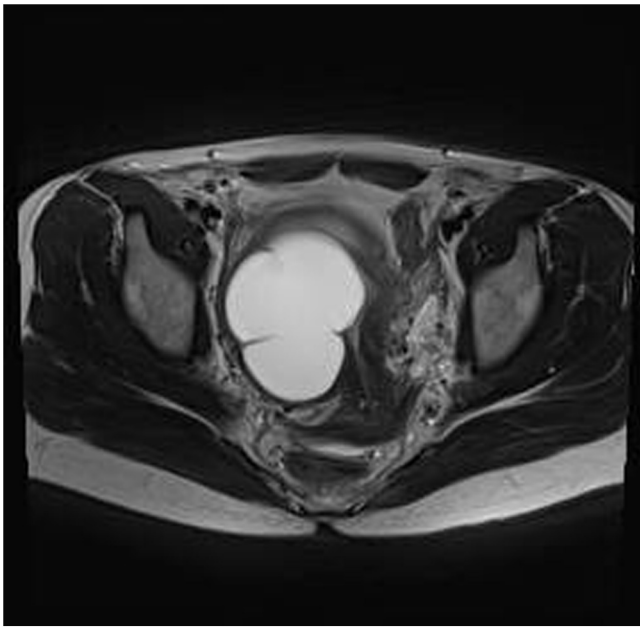
A 54-year-old woman with fibroids presented with pain and abnormal bleeding. MRI suggested a myometrial cyst. A total hysterectomy was performed, which revealed multiple subserosal fibroids. The largest of which had a multicystic cut surface. On histology, the cystic spaces were lined by simple endometrial-type epithelium surrounded by a peripheral rim of condensed smooth muscle cells. A descriptive report was issued with a differential diagnosis of a uterus-like mass or cystic adenomyosis.

#### 3.3. Case 3

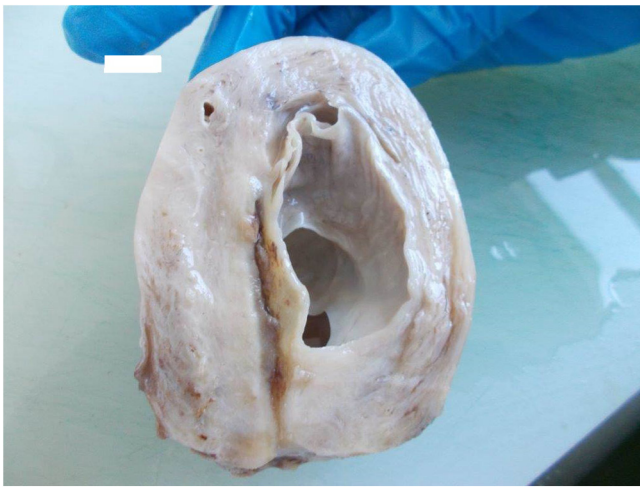A 36-year-old immunocompromised woman presented with persistent severe dyskaryosis on cervical cytology. A total hysterectomy revealed incidental cystic areas within the fundal myometrium. Histology demonstrated a loculated myometrial cyst lined by flattened cuboidal cells measuring 20 mm in maximum

\* Corresponding author.

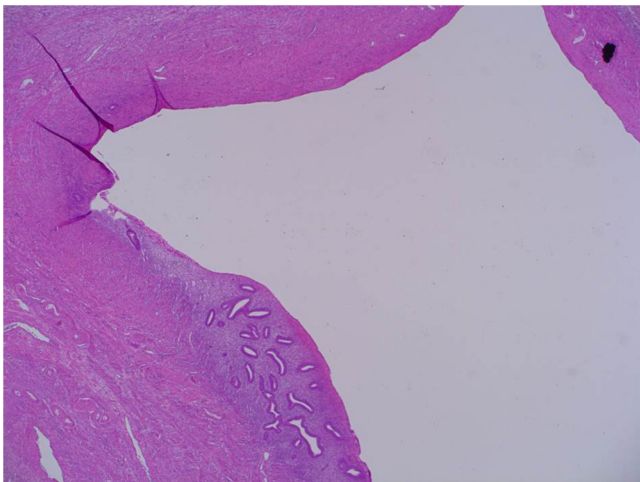
E-mail addresses: [Lucy.green8@nhs.net](mailto:Lucy.green8@nhs.net) (L.J. Green), [Tervinder.sokhi@nhs.net](mailto:Tervinder.sokhi@nhs.net) (T. Sokhi), [Moji.Balogun@nhs.net](mailto:Moji.Balogun@nhs.net) (M. Balogun), [r.ganesan@nhs.net](mailto:r.ganesan@nhs.net) (R. Ganesan).



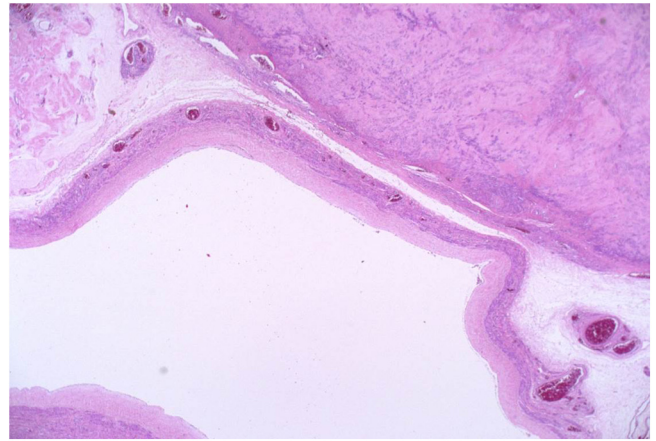
**Fig. 1.** CT scan showing multiloculated myometrial cyst distinct from the endometrial cavity.



**Fig. 2.** Macroscopic view of hysterectomy specimen showing multiloculated myometrial cyst distinct from the endometrial cavity.



**Fig. 3.** High-power view showing the endometrial-type glands and stroma diagnostic of adenomyosis.



**Fig. 4.** Cystic leiomyoma showing a cystic space with an attenuated lining surrounded by benign smooth muscle.

dimension. The cyst was separated from the serosa by a narrow rim of fibrous tissue. There was no adenomyosis, this was diagnosed as a mesothelial inclusion cyst.

#### 3.4. Case 4

A 59-year-old post-menopausal woman with known fibroids presented with renal angle discomfort and was found to have a 22-week-size multi-loculated pelvic mass. The CT appearance was of a thick-walled myometrial cyst attached to the fundus of the uterus. It had thick internal septa and solid soft-tissue areas with foci of calcification. She had a total hysterectomy and bilateral salpingo-oophorectomy. A cystic myometrial mass was identified measuring 50 mm. Microscopy showed a cystic space with an attenuated lining surrounded by smooth muscle showing marked hyalinisation. The diagnosis was leiomyoma with cystic change.

#### 3.5. Case 5

A 35-year-old nulliparous woman presented with heavy menstrual bleeding and pelvic pain. An ultrasound scan demonstrated a complex cystic area on the posterior aspect of the uterus, measuring 4.6 cm. Laparoscopic assessment identified the lesion as a possible fibroid which was subsequently excised. Histology revealed a cyst wall lined by flattened cells. The differential diagnosis was of a simple congenital cyst and a mesothelial cyst. Three years later the patient presented with abdominal pain and an ultrasound scan showed a septated cystic area within the posterior myometrial wall measuring 2.4 cm. She underwent a subtotal hysterectomy and the cystic myometrial lesion was confirmed as an adenomatoid tumour.

#### 3.6. Case 6

A 34-year-old nulliparous woman with a history of endometriosis presented with ongoing pelvic pain resistant to medical management. MRI demonstrated a 4 mm haemorrhagic myometrial cyst. No other features of adenomyosis were identified. There was no histological confirmation because the patient became pregnant.

#### 3.7. Case 7

A 35-year-old primiparous woman with a history of stage 4 endometriosis presented with pelvic pain. MRI showed myometrial cystic lesions and evidence of adenomyosis. The lesions were

presumed to be adenomyotic cysts. There was no histological confirmation and she was undergoing fertility treatment at the time of writing this series. Repeat ultrasound scans identified the myometrial cysts, the largest of which measured 19 mm.

### 3.8. Case 8

A 45-year-old woman presented with chronic pelvic pain and heavy menstrual bleeding after failed medical management of her fibroids. MRI, performed to assess suitability for embolization, revealed several fibroids, the largest of which measured 59 mm. In addition there were features of adenomyosis with widening of the junctional zone, endometrial clefts and myometrial cysts. Focally there was transmural involvement with indentation into the endometrial cavity. This was felt to possibly represent an adenomyoma. At the time of writing this series, the patient was on a waiting list for embolisation and so there is no histological confirmation.

### 3.9. Case 9

A 28-year-old nulliparous woman with a history of endometriosis presented with ongoing pelvic pain. She underwent laparoscopic excision of endometriosis, adhesiolysis and appendectomy. A small cyst was removed from the uterus, which was not detected by MRI. MRI did, however, show evidence of diffuse adenomyosis. Histology revealed a 7 mm cyst with smooth muscle in the wall, lined focally by cubo-columnar cells. Given the background diffuse adenomyosis, this was regarded as cystic adenomyosis.

### 3.10. Case 10

A 52-year-old woman had a hysterectomy for prolapse where an incidental finding of a 10 mm cystic area was noted in the myometrium macroscopically. Histology revealed a cystic focus of adenomyosis.

**Table 1**

Case series diagnoses.

Diagnoses	Frequency
Cystic adenomyosis/adenomyoma	7
Simple mesothelial inclusion cyst/Adenomatoid tumour	2
Leiomyoma with cystic degeneration	1
Imaging only	1

### 3.11. Case 11

A 45-year-old woman presented with menorrhagia and underwent a hysterectomy after failed endometrial ablation. An incidental finding of a 20 mm myometrial cyst containing chocolate-coloured fluid was noted. Histology confirmed cystic adenomyosis.

In summary, the women were aged between 28 and 59 years (mean age 42 years). Most patients presented with chronic pelvic pain (n = 7/11) and/or abnormal vaginal bleeding (n = 5/11). A third had a history of endometriosis. There was a wide range of diagnoses (Table 1), with the most common being cystic adenomyosis or adenomyoma (n = 7/11).

## 4. Discussion

This is the first series, albeit small, of myometrial cysts detected radiologically and pathologically, correlated with histological findings. The commonest causes were cystic adenomyosis, mesothelial cysts and cystic change within leiomyoma. In this small series, adenomyotic cysts were noted in women aged 28, 34, 35, 39, 45, 52 and 54 years. This differs from the literature [1–3], in which endometrial lined myometrial cysts were predominantly seen in adolescents and young women.

The two cases with cysts located at the fundus and close to the serosa were initially diagnosed as mesothelial cysts. One was subsequently confirmed as cystic adenomatoid tumour at hysterectomy. While mesothelial cysts, per se, have not been described in

**Table 2**

Differential diagnosis of a myometrial cyst.

Diagnosis	Clinical indicators	MRI findings	Histological findings
Adenomyotic cyst	Symptomatic (pain) May have known endometriosis/adenomyosis Infertility	Hyperintense cystic contents (T1 weighted) and hypointense wall (T2 weighted)	Cyst lined by endometrial epithelium with surrounding endometrial stroma [1]
Cystic leiomyoma	Symptomatic (pain) Menorrhagia May be known to have fibroids	Myometrial or adnexal cyst	Cyst with smooth muscle lining (no epithelial lining)
Müllerian cysts	Asymptomatic Pelvic pain	Midline cyst close to uterine serosa	Cyst lined by columnar (ciliated) epithelium with smooth muscle wall (no endometrial stroma). Immunohistochemistry (IHC) shows positive expression of WT1, ER and PR.
Wolffian cysts/Mesonephric cysts [12]	Usually asymptomatic Pelvic pain	Lateral position	Cyst lined by simple flattened/cuboidal epithelium with smooth muscle wall
Adenomatoid tumour	Asymptomatic Pelvic pain	Frequently arise from posterior wall and are usually <5 cm 80% solitary	Uni- or multicystic lesion composed of tubules lined by flattened to cuboidal cells with no atypia. IHC shows positive expression of WT1, calretinin and pancytokeratins.
Accessory uterus [13]	Pelvic pain Dysmenorrhoea	Non-communicating cavitated mass	Cavitated cystic space simulating normal uterus. Lined by endometrial epithelium and stroma with a smooth muscle wall.
Intramymetrial hydrosalpinx [14]	Pelvic pain Infertility History of pelvic infections		Cystic dilatation of the fallopian tube. Tubal epithelial lining.

the literature, cystic adenomatoid tumours have been noted [4]. Mesothelial cysts have been described in the round ligament [5]. However, in our cases the cysts were not located in the cornual region.

Cystic degeneration within leiomyoma is a well recognised phenomenon. There are two case reports [6,7], in both of which large (10–13 cm) cysts presented as possibly ovarian but at surgery were found to be myometrial cysts, confirmed histologically as leiomyomas. Our case did not present in the same way, as imaging clearly showed a myometrial cyst. Müllerian cysts are hard to diagnose without histology; however, an incidental finding of a cyst in a midline position with a lack of a solid component would increase suspicion [8].

In the vast majority of published cases, myometrial cysts represent benign pathologies; however, rare case reports of malignant myometrial cysts are reported. These include a clear cell adenocarcinoma arising in background cystic adenomyosis [9]. The possibility of cystic change in sarcomas or carcinosarcomas [10] and endometrial carcinomas [11] are radiological differential diagnoses (Table 2). In these instances, heterogeneity of imaging appearance is an important pointer towards the neoplastic nature of these lesions.

## 5. Conclusion

Myometrial cysts are uncommon lesions that occur over a wide age range. They are usually benign. Adenomyotic cysts are the commonest and usually present in women of reproductive age with MRI evidence of adenomyosis in the background myometrium. Simple mesothelial cysts can occur but may be a manifestation of a multicystic adenomatoid tumour. Cystic degeneration of leiomyomas can present as an adnexal cyst but background leiomyomas are usually found, providing a diagnostic clue. Other uncommon causes include congenital cysts (of Müllerian and Wolffian derivation), accessory uterus and malignancy.

## Patient consent

Obtained.

## Author's Contribution

Lucy J. Green gathered data, reviewed pathology and prepared the manuscript.

Tervinder Sokhi gathered data and reviewed pathology.

Moji Balogun gathered data and reviewed pathology.

Raji Ganesan reviewed pathology and prepared the manuscript.

## Funding

No funding from an external source was sought or secured in relation to this case series.

## Ethical approval

All patients attending the imaging department are informed that any images produced as part of their normal treatment may at some

time be used for diagnosis, further treatment, research, study or teaching. They are also informed that if their images are used for research, teaching or study purposes, they will not be identified, as all identifiers will be removed, in keeping with GDPR policies in England and Wales.

## Declaration of Competing Interest

The authors declare that they have no conflict of interest regarding the publication of this case series.

## Provenance and peer review

This case series was peer reviewed.

## References

- [1] I. Brosens, S. Gordts, M. Habiba, G. Benagiano, Uterine cystic adenomyosis: a disease of younger women, *J. Pediatr. Adolesc. Gynecol.* 28 (December (6)) (2015) 420–426, <http://dx.doi.org/10.1016/j.jpog.2014.05.008>.
- [2] L. Manta, N. Suci, A. Constantin, O. Toader, F. Popa, Focal adenomyosis (intra-mural endometriotic cyst) in a very young patient - differential diagnosis with uterine fibromatosis, *J. Med. Life* 9 (April–June (2)) (2016) 180–182, PubMed PMID: 27453751.
- [3] O. Koukoura, E. Kapsalaki, A. Daponte, G. Pistofidis, Laparoscopic treatment of a large uterine cystic adenomyosis in a young patient, *BMJ Case Rep.* 2015 (October) (2015), <http://dx.doi.org/10.1136/bcr-2015-210358>, pii: bcr2015210358.
- [4] N. Sakurai, Y. Yamamoto, Y. Asakawa, H. Taoka, K. Takahashi, K. Kubushiro, Laparoscopically resected uterine adenomatoid tumor with coexisting endometriosis: case report, *J. Minim. Invasive Gynecol.* 18 (March–April (2)) (2011) 257–261.
- [5] M. Tirnaksiz, A. Erkan, A.B. Dogrul, O. Abbasoglu, Mesothelial cysts of the round ligament of the uterus in 9 patients: a 15-year experience, *Int. Surg.* (April) (2016).
- [6] I.A. Fenuyi, A.R.L. Weekes, Giant myometrial cyst, *J. Obstet. Gynaecol.* 17 (1) (1997) 88–89.
- [7] R.L. Yarwood, E. Arroyo, Cystic degeneration of a uterine leiomyoma masquerading as a postmenopausal ovarian cyst. A case report, *J. Reprod. Med.* 44 (1999) 649–652.
- [8] H. Nakae, Y. Osuga, A. Fujimoto, S. Nakagawa, M. Ichinose, T. Yano, Y. Taketani, Müllerian cyst of the uterus treated with laparoscopy and diagnosed using immunohistology, *J. Obstet. Gynaecol. Res.* 39 (January (1)) (2013) 430–433.
- [9] O. Yoshiki, H. Shigeharu, S. Takao, I. Katsuhide, K. Kaoru, et al., Clear cell adenocarcinoma arising from a giant cystic adenomyosis: a case report with immunohistochemical analysis of laminin-5 gamma2 chain and p53 overexpression, *Pathol. Res. Pract.* 204 (9) (2008) 677–682.
- [10] S.E. Rha, J.Y. Byun, S.E. Jung, S.L. Lee, S.M. Cho, S.S. Hwang, H.G. Lee, S.E. Namkoong, J.M. Lee, CT and MRI of uterine sarcomas and their mimickers, *AJR Am. J. Roentgenol.* 181 (November (5)) (2003) 1369–1374.
- [11] S.C. Faria, T. Sagebiel, A. Balachandran, C. Devine, C. Lal, P.R. Bhosale, Imaging in endometrial carcinoma, *Indian J. Radiol. Imaging* 25 (April–June (2)) (2015) 137–147.
- [12] K. Pushpalatha, P. Mishra, N.D. Bag, An unprecedented large mesonephric cyst posing diagnostic dilemma and surgical challenge, *Int. J. Reprod. Contracept. Obstet. Gynecol.* 4 (June (3)) (2015) 905–907.
- [13] N. Jain, R. Verma, Imaging diagnosis of accessory and cavitated uterine mass, a rare müllerian anomaly, *Indian J. Radiol. Imaging* 24 (April–June (2)) (2014) 178–181.
- [14] N. Chongchitnant, L.B. Otken, Intrauterine hydrosalpinx, *Hum. Pathol.* 15 (June (6)) (1984) 592–594.