

Bullous Fixed Drug Eruption Following Ibuprofen Ingestion

Seyed Amirhossein Fazeli^{1,2,3}, Morteza Abbasi^{4,5}, Hadi Jalali⁶, Sonia Eskandari⁷, Farzaneh Shamshirgaran⁸, Zahra Dehghani⁹, Reza Golabchifard³, Shahram Ghiyasvand¹⁰, Kaveh Ghannad¹¹

¹Department of Anatomy, Gorgan University of Medical Sciences, Gorgan, Iran

²Department of Embryology and Histology, Gorgan University of Medical Sciences, Gorgan, Iran

³Department of Internal Medicine, Zahedan University of Medical Sciences, Zahedan, Iran

⁴Department of Nursing, Birjand University of Medical Sciences, Birjand, Iran

⁵Department of Emergency, Sarbisheh Ali-Ebne-Abitaleb Hospital, Birjand University of Medical Sciences, Birjand, Iran

⁶Department of Pathology, Birjand University of Medical Sciences, Birjand, Iran

⁷School of Medicine, Tehran University of Medical Sciences, Tehran, Iran

⁸Department of Pharmacy, Zabol University of Medical Sciences, Zabol, Iran

⁹Department of Radiology, Shahid Beheshti University of Medical Sciences, Tehran, Iran

¹⁰Department of Internal Medicine, Tabriz University of Medical Sciences, Tabriz, Iran

¹¹Department of Surgery, Shahid Beheshti University of Medical Sciences, Tehran, Iran

Received: September 2017.

Accepted: November 2017.

ABSTRACT

Fixed drug eruption (FDE) is a drug reaction involving skin and less commonly mucosal membranes. The common manifestation is localized well-demarcated patches or plaques appeared following receiving of a culprit drug. When re-exposure occurs, the rashes will appear at areas involved in previous episodes. Limited reports on bullous FDE due to ibuprofen have been documented before. Herein, we described an elderly man who experienced multifocal lesions in his oral mucosa, penis, and multiple sites of skin following ibuprofen ingestion confirmed as FDE by pathological studies. The culprit drug had been discontinued. Systemic and topical glucocorticoids as well as supportive care had been instituted. The patient's outcome was favorable and his lesions had been recovered within the next weeks. Patient's follow-up showed that he had received ibuprofen again sometime later resulting in anal mucosal lesion and similar penile involvement. In routine clinical practice, mucocutaneous adverse drug reactions should be considered. A high index of suspicion, the detailed medication history, the course of the symptoms, and distributing pattern of the lesions are essential clues for the diagnosis. However, judicious and prompt pathological studies can help to differentiate multifocal bullous FDE from major skin drug reactions such as Stevens–Johnson syndrome/toxic epidermal necrolysis.

KEYWORDS: Bullous, fixed drug eruption, Ibuprofen, Stevens–Johnson syndrome, toxic epidermal necrolysis

INTRODUCTION

Ibuprofen is one of the nonsteroidal anti-inflammatory drugs (NSAIDs) with widespread use around the world.^[1] NSAIDs are mainly used for the treatment of pain, fever, and inflammation, and diseases such as osteoarthritis are well-known examples of their common usages.^[2]

Like other NSAIDs, ibuprofen can cause gastrointestinal side effects including mucosal erosion, peptic ulcer, and gastrointestinal bleeding.^[2] In addition, the frequency of cardiovascular toxicity in patients received traditional and selective NSAIDs, particularly those with underlying cardiovascular disorders, is increased.^[3] NSAIDs can cause different nephrotoxicities including ischemic kidney

Address for correspondence:

Dr. Seyed Amirhossein Fazeli, E-mail: sa.fazeli@gmail.com

This is an open access journal, and articles are distributed under the terms of the Creative Commons Attribution-NonCommercial-ShareAlike 4.0 License, which allows others to remix, tweak, and build upon the work non-commercially, as long as appropriate credit is given and the new creations are licensed under the identical terms.

For reprints contact: reprints@medknow.com

How to cite this article: Fazeli SA, Abbasi M, Jalali H, Eskandari S, Shamshirgaran F, Dehghani Z, et al. Bullous fixed drug eruption following ibuprofen ingestion. J Res Pharm Pract 2018;7:51-56.

Access this article online

Quick Response Code:



Website: www.jrpp.net

DOI: 10.4103/jrpp.JRPP_17_81

injury, interstitial nephritis, nephrotic syndrome, and modest elevation of systolic blood pressure.^[4] In addition, NSAIDs have some effects on the central nervous system and can cause aseptic meningitis, psychosis, and tinnitus. They also can trigger an asthmatic attack.^[5]

Different skin reactions following ingestion of ibuprofen have been introduced up to now. Contact dermatitis, photosensitivity, angioedema, and urticarial rashes are some of the described mucocutaneous side effects associated with ibuprofen.^[6] However, bullous fixed drug eruption (FDE) due to ibuprofen ingestion is an uncommon skin reaction.^[6]

According to the studies, approximately 6% of all hospital admissions are the result of adverse drug reactions (ADRs).^[7] Skin involvements as an ADR are frequent and affect 2%–3% of hospitalized patients.^[8] FDE is a sudden-onset ADR characterized by round or oval cutaneous patches or plaques manifested as solitary or multifocal rashes.^[6,9,10] These well-defined erythematous to violaceous, hyperpigmented lesions with dusky gray centers developed within minutes to 24 h following exposure to causative drugs.^[6,9,10] Paucity of constitutional symptoms such as fever is the usual presentation of the FDE, and the patient is a nontoxic individual with stable vital signs.^[10] The main sites of involvement are the lips, groin, and palms/soles, but the lesions could be developed anywhere on the body including penile shaft.^[10] Mucosal membranes of the eyes, nose, mouth, urethra, vagina, and anus are usually spared.^[10] It is called as “fixed” because that next exposures to a specific agent can result in re-appearance of the rashes at the same areas seen in previous episodes of exposures to that agent.^[6,9,10] Spontaneous recovery of the lesions within 7–10 days following withdrawal of causative agents is a rule.^[10] A residual hyperpigmentation could be found in healed areas.^[10]

A wide range list of medications including prescribed medications, over-the-counter (OTC) drugs and herbal remedies can cause FDE.^[10] Antibiotics such as trimethoprim/sulfamethoxazole, NSAIDs, and antiepileptics are the most famous culprit drugs.^[10] Table 1 shows a summary of the causative agents Reported by Mahboob and Haroon.^[11]

Widespread bullous FDE is a variant of FDE with blister formation.^[10,12] It may mimic severe form of adverse cutaneous drug reactions, i.e., Stevens–Johnson syndrome (SJS)/toxic epidermal necrolysis (TEN). In such clinical background, the differential diagnosis could be challenging.^[10,12]

To our best of knowledge, limited reports on bullous FDE following ibuprofen ingestion have been documented

Table 1: Some medications with reported risk of fixed drug eruption

Names of medications
NSAIDs
Naproxen
Diclofenac sodium
Indomethacin
Ibuprofen
Mefenamic acid
Antibiotics
TMP/SMX
Amoxycillin
Ampicillin
Erythromycin
Phenylbutazone
Clindamycin
Metronidazole
Tetracycline
Antifungals
Tinidazole
Albendazole
Griseofulvin
Pyrantel pamoate
Anticonvulsants
Phenobarbitone
Miscellaneous
Metamizole
Allopurinol
Chlormezanone
Paracetamol
Acetylsalicylic acid

TMP=Trimethoprim, SMX=Sulfamethoxazole, NSAID=Nonsteroidal anti-inflammatory drugs

before.^[6,13,14] Herein, we described an elderly man who developed multifocal mucocutaneous lesions following ibuprofen ingestion, and the diagnosis of bullous FDE was confirmed after pathological studies.

CASE REPORT

Our patient was a 65-year-old male from Makhunik village of Sarbisheh town, South Khorasan Province, located in East of Iran. He was visited in internal medicine clinic complaining of recent-onset skin rashes and oral ulcer. According to the history and initial evaluations, he received some medications including ibuprofen (Gelofen®) 400 mg orally because of toothache within a week before admission. Less than 24 h after ingestion, he experienced burning sensation in the dorsal aspect of the left 4th finger. Subsequently, a well-demarcated bullous lesion appeared within hours involving the dorsal surface of the proximal and middle phalanx of the left 4th finger [Figure 1a]. Similarly, a well-defined painful oral ulcer developed in the hard palate following initial burning sensation and bulla

formation [Figure 1b]. The detailed physical examination revealed also an erythematous lesion in the upper lip [Figure 1b] and a painless ulcer in the ventral surface of penile shaft. In addition, an erythematous patch was found in the right lower abdominal wall with size of 6 cm × 8 cm [Figure 1c]. Further examination showed a similar erythematous patch in the left medial malleolus sized 2 cm × 3 cm [Figure 1d].

No history of atopy or previous episodes of allergic reactions was found, and medical history was negative for systemic diseases. The laboratory studies were unremarkable, and no evidences of infection or systemic inflammatory diseases were found.

The first clinical diagnosis was FDE. However, given the extent of mucocutaneous lesions, the biopsy was considered to differentiate FDE and early SJS. Incisional biopsies were prepared from the margin of abdominal and malleolar lesions. The microscopic studies of abdominal skin tissue showed hyperkeratosis of the epidermis, mild hydropic degeneration of basal layer, mixed inflammatory infiltration in the dermoepidermal junction with eosinophilic predominance, neutrophilic infiltration of blood vessels and melanin incontinence in the papillary dermis [Figure 2]. The malleolar skin biopsies showed similar hyperkeratosis and hydropic degeneration. In addition, saw tooth appearance, mild spongiosis as well as lymphocyte-predominant inflammatory infiltration of dermoepidermal junction were seen in the malleolar skin biopsies [Figure 3]. The pathologic findings were compatible with clinical diagnosis of FDE.

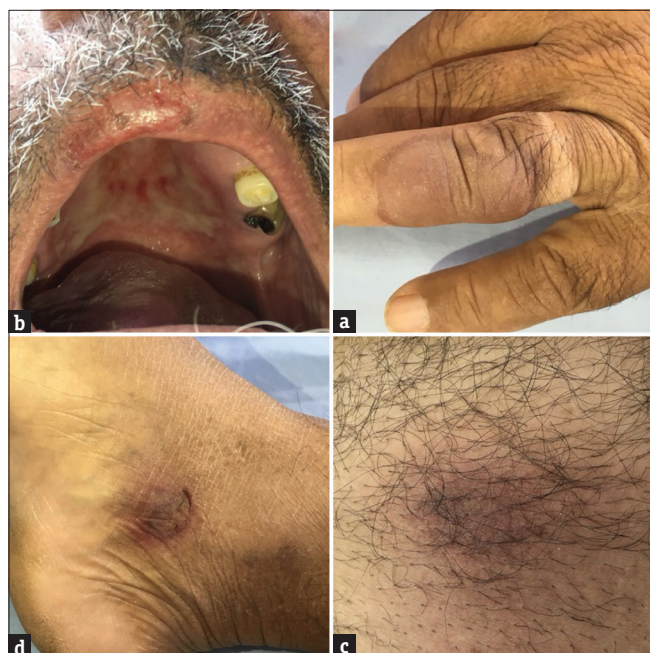

Figure 1: (a-d) The patient's skin and oral lesions at arrival

Ibuprofen and cephalexin had been withdrawn. Given the widespread disturbance of the lesions, systemic glucocorticoid, antihistamines, and antibiotics had been introduced as empirical treatment of other possible serious differential diagnoses such as SJS. Following pathological studies and dermatology consultation confirming diagnosis of FDE, systemic glucocorticoid had been discontinued and fluocinolone acetonide cream 0.025% as well as topical moisturizing antiseptics including mupirocin 2% cream, and rivanol 1/5000 solution was administered according to dermatology consult.

No skin patch tests were available. Following the withdrawal of the medications and supportive care, the patient's outcome was favorable. His oral and skin lesions have been recovered with residual hyperpigmentation within the next weeks [Figure 4]. The patient had been recommended for avoidance of the culprit preparations. Patient's follow-up showed that he received ibuprofen again sometime later resulting in anal mucosal lesion and similar penile involvement. This re-exposure can confirm the causative role of the ibuprofen as the culprit drug for the initial FDE. The timeline of the patient's clinical events is summarized in Table 2.

The written informed consent was obtained from the patient to publish the case report. The ethical approval was issued by the local ethical committee.

DISCUSSION

FDE is a common skin reaction and could be appeared due to many medications used in daily practice including

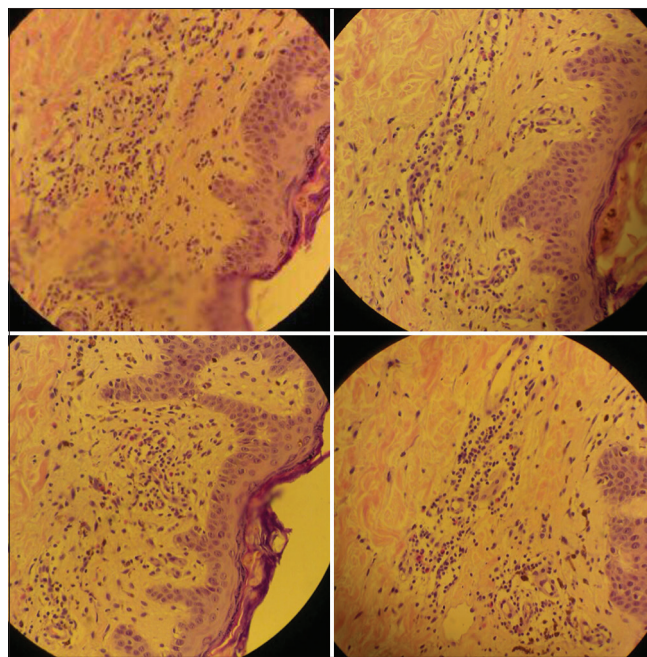


Figure 2: The microscopic pictures of the patient's abdominal skin biopsies

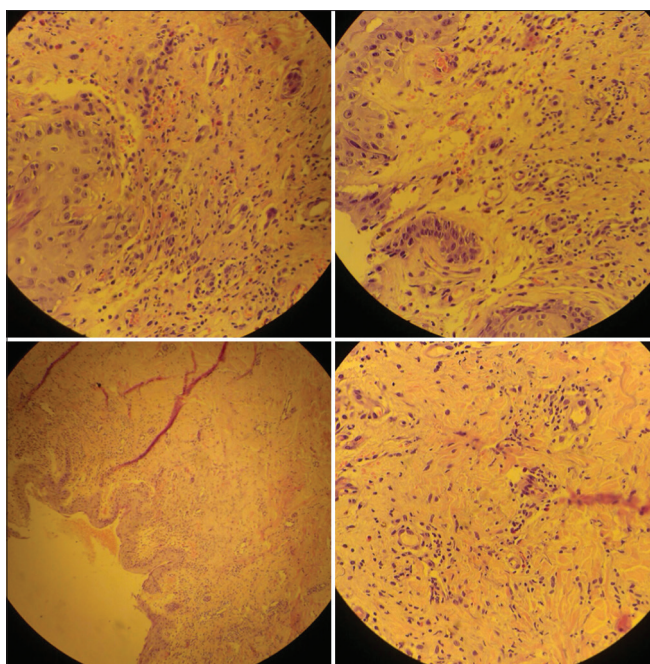


Figure 3: The microscopic pictures of the patient's malleolar skin biopsies

Table 2: The summary of patient's clinical events

Timeline	Clinical events
A week before admission	Ingestion of medication including ibuprofen (Gelofen®) 400 mg for toothache
Within 24 h after ingestion	Burning sensation and appearance of bullous lesion in the left 4 th finger Developing painful ulcer in the hard palate and an erythematous lesion in the upper lip Appearance of a painless penile ulcer Appearance of skin rashes in the abdominal wall and left medial malleolus
Internal medicine outpatient visit	Hospitalization, withdrawal of possible culprit medications, incisional biopsy, systemic glucocorticoid, supportive care
Pathological confirmation of FDE	Discontinuing of systemic glucocorticoid, institution of topical glucocorticoid and topical moistures and antiseptics
Discharge from internal medicine ward	Close follow-up, recovery of the mucocutaneous lesions within next weeks with residual hyperpigmentation
Inpatient follow-up visit	History of re-exposure to ibuprofen resulting to anal lesion and similar penile involvement; confirmation of causative role of ibuprofen

FDE=Fixed drug eruption

prescribed, OTC drugs, and herbal remedies.^[10] However, bullous FDE is a uncommon side effect of ibuprofen with previous limited reports.^[6]

Al Aboud *et al.* reported FDE in daughter and father following ibuprofen ingestion.^[14] This familial occurrence can indicate a genetic predisposition for FDE due to ibuprofen. Alvarez Santullano *et al.* described FDE lesions affecting skin, tongue, and oral mucosa in an elderly

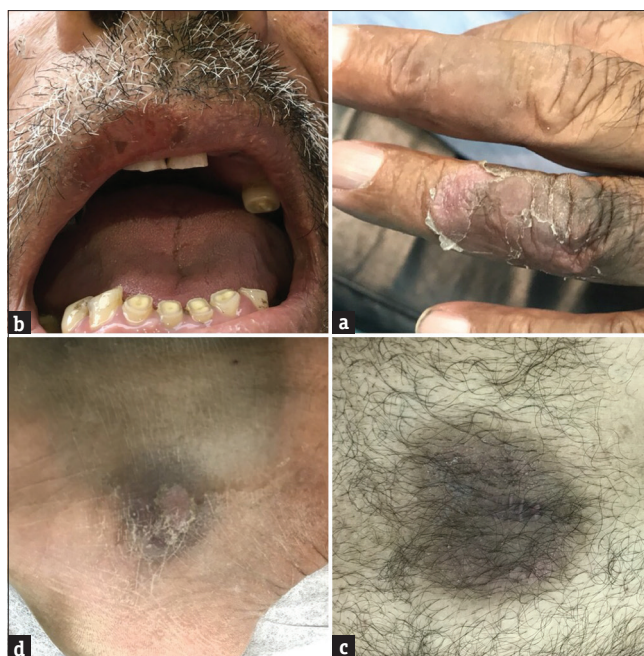

Figure 4: The recovery of patient's skin and oral lesions within next weeks following withdrawal of the causative medication. Note hyperpigmentation of recovered lesions characteristic of fixed drug eruption. (a) patient's finger lesion, (b) upper lip lesion, (c) malleolar skin, (d) abdominal skin

woman within 2 days following ibuprofen exposure. Bullous palatine lesion was reported in the initial episode and the bullous skin lesions had been appeared following re-exposure to ibuprofen.^[13] Sánchez-Morillas *et al.* reported two episodes of FDE following ibuprofen ingestion in an old man. The involvement pattern included the flank and lower extremities, and mucosal involvement was seen only in initial presentation. No evidence of bullous lesions was reported. Interestingly, the patient was tolerable to ibuprofen before the initial episodes of FDE.^[6] Alvarez Santullano *et al.* and Sánchez-Morillas *et al.* not reported penile lesions.^[6,13]

Generalized bullous FDE has been documented for other NSAIDs including naproxen and diclofenac.^[9,12,15] Patell *et al.* reported widespread bullous FDE following diclofenac intake with oral and palmoplantar pattern of involvement in a middle-aged man.^[12] Furthermore, medications other than NSAIDs including acetaminophen, barbiturates, sulfonamide antibiotics, and tetracycline can also cause the bullous FDE.^[10,16-18]

Severe cutaneous drug reactions includes SJS, drug-induced vasculitis, serum sickness diseases, and hypersensitivity syndrome.^[8] Among them, SJS and TEN are two syndromes with very progressive clinical course.^[10] Erosive mucosal lesions can be seen in the both syndromes involving at least two mucosal membranes.^[8] In conjunction to mucosal involvement, SJS presents purpuric macules or atypical targets on

the skin.^[8] The confluence of the lesions is rare. Small blisters could be seen, but the detachment extent is up to 10 percent of body surface area.^[8,10] The lesions of TEN are similar to SJS. However, confluent erythema and detachment area of >30% of total body surface are seen, and large necrotic epidermal sheets can be developed.^[8] A detachment area of 10%–30% of total body surface area can be considered as an overlap syndrome of SJS/TEN.^[10] Constitutional symptoms such as fever are present in some SJS cases, but nearly, all cases of TEN.^[8] Involvement of the internal organs including respiratory and gastrointestinal tracts can be found in both syndromes.^[8] Mortality rates of SJS and TEN are <5% and 30%, respectively. The leading cause of mortality is sepsis.^[8] Most important therapeutic measures are withdrawal of the culprit drugs, precise fluid and electrolyte management, antibiotic coverage, nutritional support, and other intensive supportive cares as needed.^[8] Institution of glucocorticoids is controversial. Plasmapheresis, cyclosporine, and monoclonal antibodies have been reported as potential therapies.^[8]

The main causative drugs SJS and TEN are trimethoprim/sulfamethoxazole, carbamazepine, sulfadiazine, barbiturates, allopurinol, and aminopenicillins.^[8] Among the NSAIDs, piroxicam is one of most frequently associated causative agents. However, diclofenac, naproxen, ibuprofen, sulindac, and ketoprofen can also cause SJS and TEN.^[8] These syndromes can be developed within 1–3 weeks subsequent to initiating exposure to causative agents.^[8] Therefore, special attention should be placed on the drugs introduced within 1 month before the development of the skin lesions.^[8]

When FDE presents with multifocal bullous lesions involving the skin and mucosal membrane, the clinician should also note other widespread drug reaction with bullous mucocutaneous manifestation including SJS or TEN.^[10] The clinical course, diagnostic laboratories, therapeutic measures, and prognosis of FDE and SJS/TEN are different and differential diagnosis is essential.^[10] In contrast to FDE, complete blood counts, blood biochemistry including creatinine and electrolytes, frozen section, and immunofluorescence are important diagnostic measures for the SJS/TEN.^[8,10] While the withdrawal of culprit drugs and conservative management such as frequent dressing change are the mainstay treatment in majority of the cases of FDE, patients with SJS/TEN may need intensive care and frequent monitoring. In addition, systemic glucocorticoids and other immunosuppressive agents can be useful for SJS/TEN.^[8,10]

The presence of patient's illness, constitutional symptoms such as fever, mucosal erosive lesions, visceral

involvement, ill-defined blisters or patches, and lack of history of previous episodes with similar affected areas are in favor of SJS/TEN rather than generalized FDE.^[10,12,19] In the case of FDE, the interval between exposure to causative agent and the onset of symptoms is about minutes to 24 h. In contrast, this interval is about 1–3 weeks for SJS/TEN. This timing can be a differential clue. In addition, histopathological examination and immunohistochemical studies can differentiate these two categories of skin reaction.^[20]

The skin patch test is helpful to confirm the role of causative drug to develop the FDE lesions.^[13] As a limitation of our report, no confirmatory skin patch test of ibuprofen was available.

Ibuprofen is a relatively safe NSAID. Herein, an uncommon bullous FDE due to ibuprofen was described. Comprehensive history of recent prescribed and OTC medications as well as herbal remedies, course of symptoms, and detailed examination are the mainstay of FDE clinical diagnosis. In the case of such multifocal bullous eruptions, the differential diagnosis of SJS/TEN is essential. Judicious and prompt pathological studies can help to confirm definite diagnosis in equivocal clinical scenarios.

Declaration of patient consent

The authors certify that they have obtained all appropriate patient consent forms. In the form the patient(s) has/have given his/her/their consent for his/her/their images and other clinical information to be reported in the journal. The patients understand that their names and initials will not be published and due efforts will be made to conceal their identity, but anonymity cannot be guaranteed.

AUTHORS' CONTRIBUTION

Seyed Amirhossein Fazeli was the attending physician contributed in the diagnosis of the disease, the patient's treatment, the concept and the design of the study and the drafting and editing of the manuscript. Morteza Abbasi, Sonia Eskandari and Farzaneh Shamshirgaran helped the corresponding author in taking the patient's history, clinical photographs and preparation of the pictures. Kaveh Ghannad prepared skin biopsies and Hadi Jalali collaborated in pathological studies. Zahra Dehghani, Reza Golabchifard and Shahram Ghiyasvand helped the corresponding author in editing of the manuscript.

Financial support and sponsorship

Nil.

Conflicts of interest

There are no conflicts of interest.

REFERENCES

- Díaz Jara M, Pérez Montero A, Gracia Bara MT, Cabrerizo S, Zapatero L, Martínez Molero MI, *et al.* Allergic reactions due to ibuprofen in children. *Pediatr Dermatol* 2001;18:66-7.
- Sinha M, Gautam L, Shukla PK, Kaur P, Sharma S, Singh TP, *et al.* Current perspectives in NSAID-induced gastropathy. *Mediators Inflamm* 2013;2013:258209.
- Dajani EZ, Islam K. Cardiovascular and gastrointestinal toxicity of selective cyclo-oxygenase-2 inhibitors in man. *J Physiol Pharmacol* 2008;59 Suppl 2:117-33.
- Zadrazil J. Nonsteroidal antiinflammatory drugs and the kidney. *Vnitr Lek* 2006;52:686-90.
- Risser A, Donovan D, Heintzman J, Page T. NSAID prescribing precautions. *Am Fam Physician* 2009;80:1371-8.
- Sánchez-Morillas L, Rojas Pérez-Ezquerro P, González Morales ML, González-Mendiola R, Laguna Martínez JJ. Fixed drug eruption due to ibuprofen with patch test positive on the residual lesion. *Allergol Immunopathol (Madr)* 2013;41:203-4.
- Pirmohamed M, James S, Meakin S, Green C, Scott AK, Walley TJ, *et al.* Adverse drug reactions as cause of admission to hospital: Prospective analysis of 18 820 patients. *BMJ* 2004;329:15-9.
- Roujeau JC, Stern RS. Severe adverse cutaneous reactions to drugs. *N Engl J Med* 1994;331:1272-85.
- Bilgili SG, Calka O, Karadag AS, Akdeniz N, Kosem M. Nonsteroidal anti-inflammatory drugs-induced generalized fixed drug eruption: Two cases. *Hum Exp Toxicol* 2012;31:197-200.
- Dharamsi FM, Michener MD, Dharamsi JW. Bullous fixed drug eruption masquerading as recurrent Stevens Johnson syndrome. *J Emerg Med* 2015;48:551-4.
- Mahboob A, Haroon TS. Drugs causing fixed eruptions: A study of 450 cases. *Int J Dermatol* 1998;37:833-8.
- Patell RD, Dosi RV, Shah PC, Joshi HS. Widespread bullous fixed drug eruption. *BMJ Case Rep* 2014. pii: bcr2013200584.
- Alvarez Santullano CV, Tover Flores V, De Barrio Fernández M, Tornero Molina P, Prieto Garcia A. Fixed drug eruption due to ibuprofen. *Allergol Immunopathol (Madr)* 2006;34:280-1.
- Al Aboud K, Ramesh V, Al Hawsawi K. Fixed drug eruption to ibuprofen in daughter and father. *J Drugs Dermatol* 2003;2:658-9.
- Bandino JP, Wohltmann WE, Bray DW, Hoover AZ. Naproxen-induced generalized bullous fixed drug eruption. *Dermatol Online J* 2009;15:4.
- Ayala F, Nino M, Ayala F, Balato N. Bullous fixed drug eruption induced by paracetamol: Report of a case. *Dermatitis* 2006;17:160.
- Savchak VI. Fixed bullous erythema after administration of corvalol. *Vestn Dermatol Venerol* 1987;(6):62-3.
- Jain VK, Dixit VB, Archana. Fixed drug eruption of the oral mucous membrane. *Ann Dent* 1991;50:9-11.
- Lipowicz S, Sekula P, Ingen-Housz-Oro S, Liss Y, Sassolas B, Dunant A, *et al.* Prognosis of generalized bullous fixed drug eruption: Comparison with Stevens-Johnson syndrome and toxic epidermal necrolysis. *Br J Dermatol* 2013;168:726-32.
- Lin TK, Hsu MM, Lee JY. Clinical resemblance of widespread bullous fixed drug eruption to Stevens-Johnson syndrome or toxic epidermal necrolysis: Report of two cases. *J Formos Med Assoc* 2002;101:572-6.