

CASE REPORT

Hydrodissection technique with t-tube placement in atelectatic ear

Eleana Tzoi^{1,2}  | Konstantinos Garefis^{1,2} | Anastasia Kupriotou^{1,2} | Vasileios Nikolaidis^{1,2} | Konstantinos Markou^{1,2}

¹2nd Academic Department of ENT, Aristotle University of Thessaloniki, Papageorgiou general hospital, Thessaloniki, Greece

²Department of Otolaryngology-Head and Neck Surgery, 2nd Academic Department of ENT, Aristotle University of Thessaloniki, Papageorgiou General Hospital, Thessaloniki, Greece

Correspondence

Eleana Tzoi, 2nd Academic Department of ENT, Aristotle University of Thessaloniki, Papageorgiou general hospital, Thessaloniki, Greece.
Email: eleana-tzoi@hotmail.com

Abstract

Hydrodissection technique is a safe way to establish a fully functional tympanic membrane in cases of early stages of atelectatic ears.

KEYWORDS

atelectasis, chronic otitis media, tympanoplasty, ventilation tube

1 | INTRODUCTION

The existence of a classification system is useful in documenting and following the atelectatic ear and is helpful with determining management. Often, nasal steroids and decongestants are sufficient. On failure, surgical management of the atelectatic ear is brought to the fore. It includes reconstruction of tympanic membrane either by perichondrium/cartilage/temporal fascia graft or by laser technique, with or without ventilation tube insertion. We present a case of atelectatic ear that was treated using hydrodissection technique and t-tube insertion with good anatomical and functional results.

2 | CASE REPORT

A 4-year-old female presented to the ENT clinic with bilateral hearing loss and ear fullness, progressively worsening

over the past 3 weeks. She denied otorrhea, otalgia, tinnitus, vertigo, and headaches; she had no history of ear surgery, ear trauma, or significant noise exposure. Otoscopy revealed a diffused and retracted tympanic membrane involving both pars flaccida and pars tensa, progressing inward and touching the promontory (Grade IV in Sade's classification) (Figure 1). Fiber-optic endoscopic evaluation revealed no sinus or nasopharynx inflammation. An audiogram was obtained and revealed conductive hearing loss and an air-bone gap of 40 dB. She received medical treatment with nasal steroids, normal saline irrigations, and decongestants without improvement. Surgery was indicated, and hydrodissection technique took place. Endoscopically assisted, intratympanic injection of saline in the middle ear was performed, via trascanal approach, under general anesthesia. The drum was detached from the promontory and ossicular chain (Figure 2). Through myringotomy on the anterior-inferior part of the par tensa, mucoblenoid fluid (Figure 3) was withdrawn and a t-tube was inserted (Figure 4). The procedure took place bilaterally.

This is an open access article under the terms of the Creative Commons Attribution License, which permits use, distribution and reproduction in any medium, provided the original work is properly cited.

© 2020 The Authors. *Clinical Case Reports* published by John Wiley & Sons Ltd

Ten days postoperatively, audiogram showed comprehensive restoration of hearing. Otoscopy revealed complete compensation of the atelectatic and atrophic tympanic membrane which was highly functional (Figure 5).

3 | DISCUSSION

The atelectatic tympanic membrane poses a significant management challenge. The under-ventilated middle ear and retracted drum can progress to ossicular erosion, progressive hearing loss, or cholesteatoma formation.^{1,2} Management of this problem remains difficult given that the etiology of the atelectatic membrane is not completely understood. It is

unknown whether Eustachian tube dysfunction and negative pressure in the middle ear are the only responsible for this problem.³ In-ear instillation of traditional products, inflammation of upper respiratory tract, such as rhinitis and nasopharyngitis, craniofacial anomalies, immunosuppression, atopy, and low socioeconomic level are some of the contributing factors that increase the risk of transition to chronicity.⁴ The controversy is augmented by the fact that, early in the course of the disease, and even in the presence of incus necrosis, hearing loss is frequently minimal, and patients are mostly asymptomatic.⁴

A grading system that is a modification of Sades has been used to develop a treatment algorithm for this condition.² The treatment of COM is medicosurgical. Surgery is a modality when medical treatment is insufficient, particularly in grade III-IV.² Surgical procedures consist of traditional tympanoplasty via cartilage/perichondrium graft, CO₂ laser tympanoplasty and mastoidectomy in case of cholesteatoma.⁵ It may be accompanied by ossicular reconstruction and usually ventilation tube insertion preoperatively.⁵ The aim is to reverse atelectasis and to repneumatize the middle ear. In certain situations, such as the atelectatic ear, cholesteatoma, and revision tympanoplasty, temporal fascia and perichondrium have been shown to undergo atrophy and subsequent failure in the postoperative period, regardless of placement technique.⁵ The interest leads to the establishment of cartilage in TM reconstruction. Its rigid quality tends to resist resorption and retraction, even in patients with pervasive Eustachian tube dysfunction.⁵ Hydrodissection technique aims to re-establish the tympanic membrane and repair middle ear pathology without impairment of the physical tympanoossicular chain. It includes normal anatomical and physiological reconstruction of the middle ear, is cost-effective, easy to perform, no time-consuming, bears no risk of disease transmission, nor risk of graft surveillance, and graft dissolution. It constitutes of an alternative endoscopic technique especially preferable in the pediatric population. Moreover, in adults it can be made in an outpatient basis, under topical anesthesia.

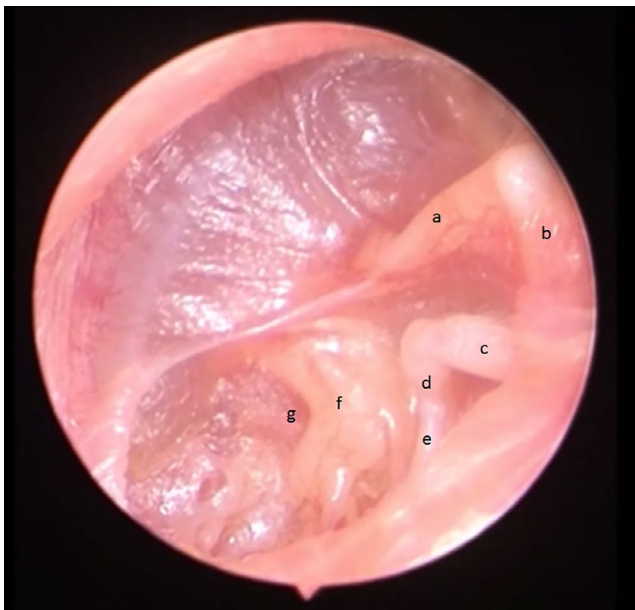


FIGURE 1 Left ear with completely retracted tympanic membrane. TM is adhered to the ossicles and promontory. a. malleus handle, b. Short process of malleus, c. long process of incus, d. incudostapedial joint and head of stapes, e. stapedius muscle, f. promontory, g. round window membrane

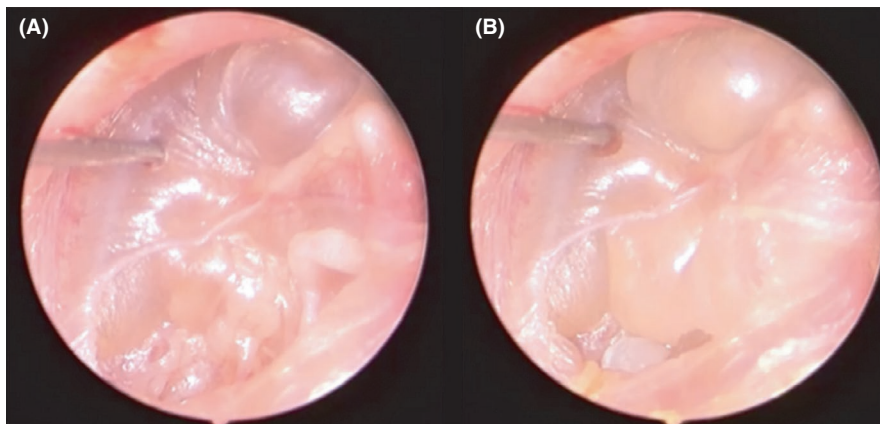


FIGURE 2 A and B, Injection of saline in the middle ear and complete detachment of tympanic membrane from the ossicular chain and promontory

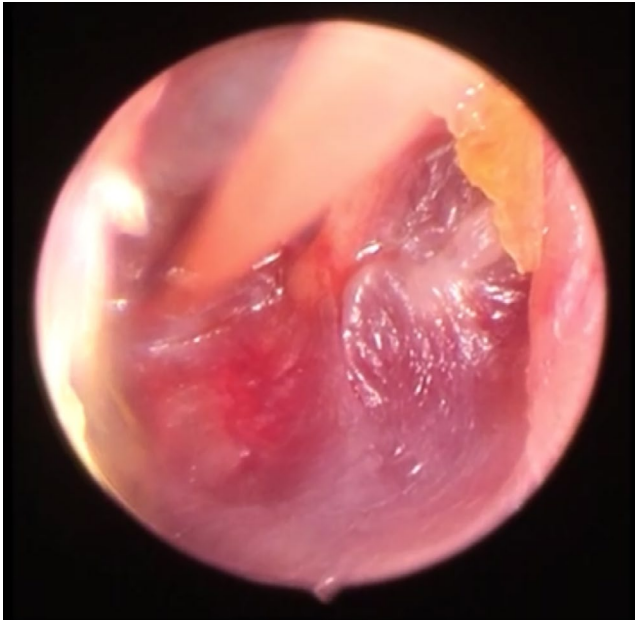


FIGURE 3 Myringotomy on the anterior-inferior part of the TM and mucoblenoid fluid abstraction from the middle cavity

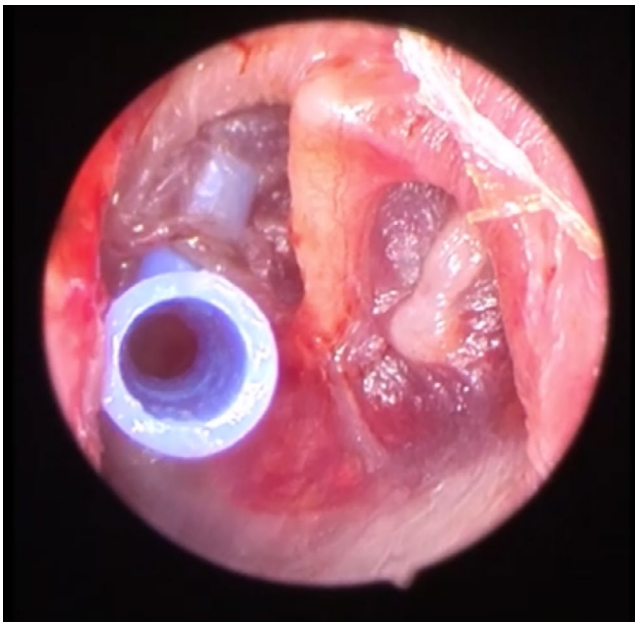


FIGURE 4 Concomitant intraoperative ventilation t-tube insertion

4 | CONCLUSION

Hydrodissection technique is safe technique for tympanic membrane restoration that may lead to a more effective and

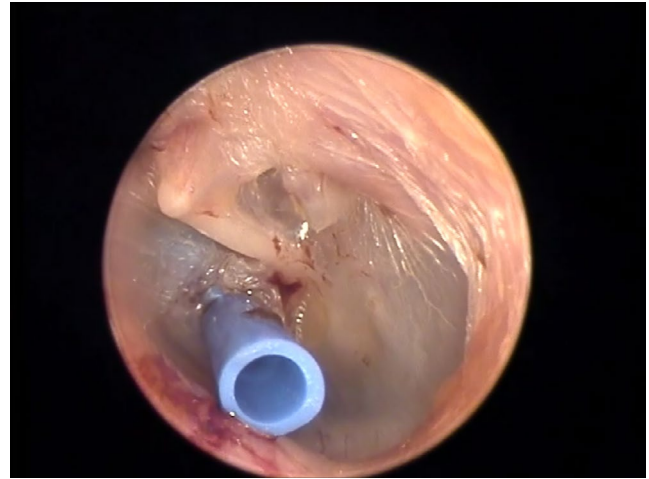


FIGURE 5 Postoperative otoscopic image with complete compensation of the atelectatic and atrophic tympanic membrane

faster surgical management of the early atelectatic cases without the existence of cholesteatoma. It appears to offer an extremely reliable method for reconstruction of the tympanic membrane in cases of atelectatic membrane with a significant improvement of hearing and no sign of recurrence.

ACKNOWLEDGMENTS

No other individual contributed to this paper. Published with written consent of the patient.

CONFLICT OF INTEREST

None declared.

AUTHOR CONTRIBUTIONS

Eleana Tzoi: contributed to writing—original draft. Konstantinos Garefis: contributed to project administration. Anastasia Kupriotou: contributed to project administration, visualization. Vasileios Nikolaidis: contributed to conceptualization, investigation, and writing—review. Konstantinos Markou: contributed to supervision.

ORCID

Eleana Tzoi  <https://orcid.org/0000-0002-6546-4194>

REFERENCES

1. Danner CJ. Middle ear atelectasis: what causes it and how is it corrected? *Otolaryngol Clin North Am.* 2006;39(6):1211-1219.
2. Borgstein J, Gerritsma TV, Wieringa MH, Bruce IA. The Erasmus Atelectasis Classification: proposal of a new classification for atelectasis of the middle ear in children. *Laryngoscope.* 2007;117:1255-1259.

3. Hartzell Larry D, Dornhoffer JL. Timing of tympanoplasty in children with chronic otitis media with effusion. *Curr Opin Otolaryngol Head Neck Surg.* 2010;18:550-553.
4. Dornhoffer JL. Surgical Management of the Atelectatic Ear. *Am J Otol.* 2000;21:315-321.
5. Friedman AB, Gluth MB, Moore PC, Dornhoffer JL. Outcomes of cartilage tympanoplasty in the pediatric population. *Otolaryngol Head Neck Surg.* 2013;148(297):301.

How to cite this article: Tzoi E, Garefis K, Kupriotou A, Nikolaidis V, Markou K. Hydrodissection technique with t-tube placement in atelectatic ear. *Clin Case Rep.* 2020;8:2701–2704. <https://doi.org/10.1002/ccr3.3242>