

## Simultaneous Idiopathic Dissections of the Coronary and Superior Mesenteric Arteries

Masato Nishi<sup>1</sup>, Daisuke Sueta<sup>1</sup>, Takashi Miyazaki<sup>1</sup>, Kenji Sakamoto<sup>1</sup>, Eiichiro Yamamoto<sup>1</sup>, Yasuhiro Izumiya<sup>1</sup>, Kenichi Tsujita<sup>1</sup>, Sunao Kojima<sup>1</sup>, Koichi Kaikita<sup>1</sup>, Osamu Ikeda<sup>2</sup>, Yasuyuki Yamashita<sup>2</sup> and Seiji Hokimoto<sup>1</sup>

---

### Abstract

---

A 49-year-old man complained of sudden upper abdominal pain but was not given a definitive diagnosis. The day after he was discharged, he noticed left chest pain. An in-depth electrocardiogram indicated acute myocardial infarction, and emergent coronary angiography revealed 99% stenosis of his left coronary artery. An intravascular ultrasound revealed spontaneous coronary artery dissection (SCAD), and the lesion was successfully stented. In an atherosclerosis screening, superior mesenteric artery dissection (SMAD) was confirmed, after which the lesion was successfully stented. This case suggests that SCAD and SMAD might have similar pathological backgrounds.

**Key words:** spontaneous coronary artery dissection, superior mesenteric artery dissection

(Intern Med 56: 1363-1367, 2017)

(DOI: 10.2169/internalmedicine.56.8043)

---

### Introduction

---

Primary spontaneous coronary artery dissection (SCAD) and superior mesenteric artery dissection (SMAD) are rare diseases, the latter of which uncommonly manifests with acute abdominal pain. Although difficult to diagnose in the early phases, it has recently become possible to achieve an early diagnosis of these conditions with the development of imaging diagnostic techniques. SCAD and SMAD are reported to be associated with degeneration of the tunica media. We herein report the first case of anterior wall myocardial infarction in the left coronary artery anterior descending branch due to both SCAD and SMAD, as well as the subsequent successful treatment with stents for both lesions. We describe an extremely rare case with bibliographic discussions.

---

### Case Report

---

A 49-year-old man was admitted to the emergency depart-

ment (ED) of a hospital with a complaint of sudden upper abdominal pain. His body height and weight were 174 cm and 60.4 kg, respectively. A medical examination revealed no other symptoms observed beyond the reported abdominal pain. He did not have any cardiac risk factors such as hypertension, dyslipidemia or a history of smoking. After four days, he was discharged without a definitive diagnosis (such as through performing gastroscopy) because the symptom disappeared over time.

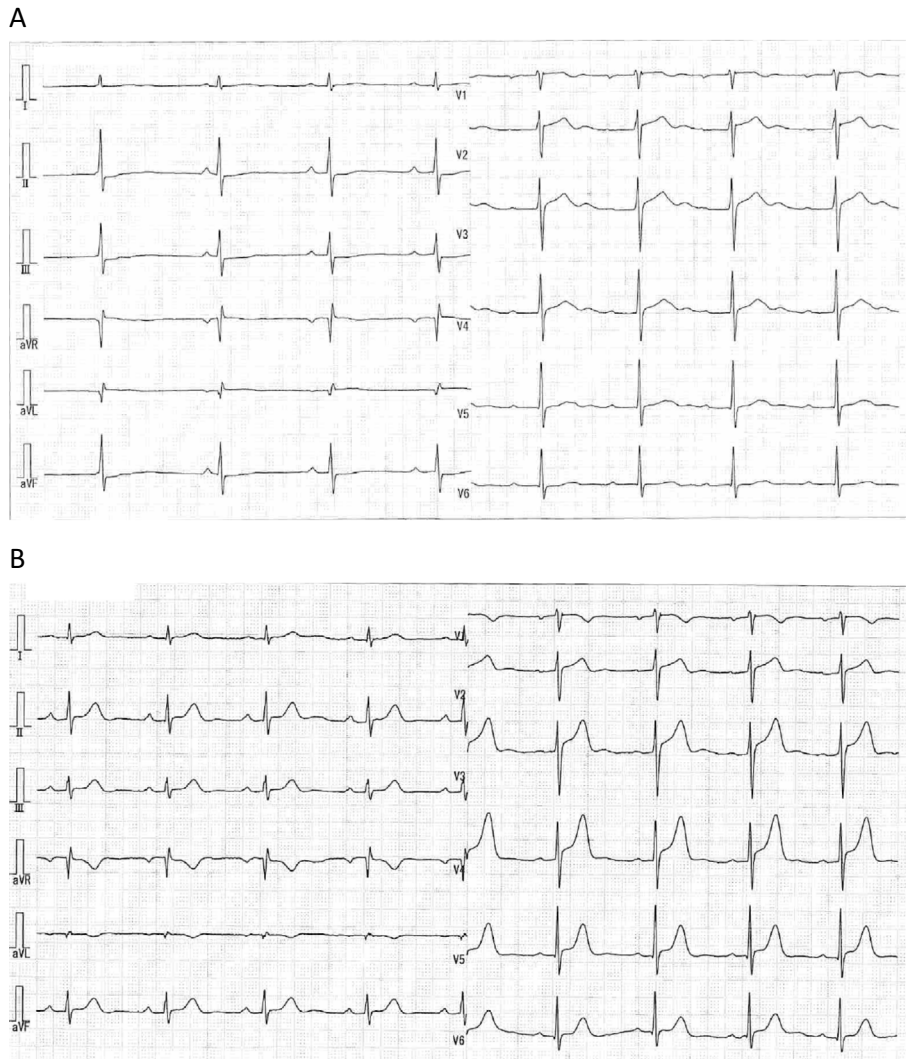
The day after he was discharged, he noticed left chest pain and returned to the ED. An electrocardiogram (ECG) revealed serious ST-segment elevations in the II, III, aVF and V2-V6 leads (Fig. 1A) compared to the ECG from his initial admission (Fig. 1B). Thus, he was suspected of having ischemic heart disease and was transferred to our institution. All cardiac markers (including troponin T levels) were normal. His blood pressure was 176/116 mmHg, and his heart rate was 63 beats per minute. Significant ST-segment changes in his ECG were also observed at our ED, with the results showing severe hypokinesia in the apex. Given these findings, he was diagnosed with ST-elevated myocardial in-

---

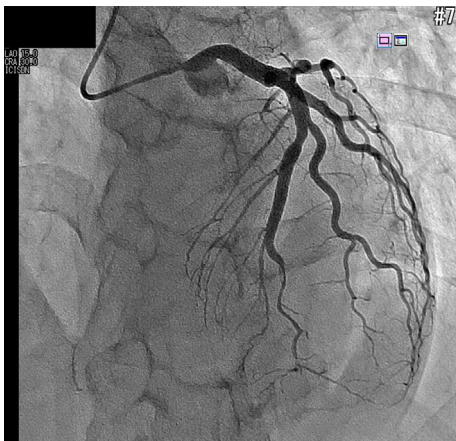
<sup>1</sup>Department of Cardiovascular Medicine, Kumamoto University Graduate School of Medical Sciences, Japan and <sup>2</sup>Department of Diagnostic Radiology, Kumamoto University Graduate School of Medical Sciences, Japan

Received for publication July 23, 2016; Accepted for publication October 3, 2016

Correspondence to Dr. Daisuke Sueta, sueta-d@kumamoto-u.ac.jp



**Figure 1.** Electrocardiograms performed at the originating hospital. (A) ECG performed on admission due to upper abdominal pain. (B) ECG performed during the ED visit due to left-sided chest pain.

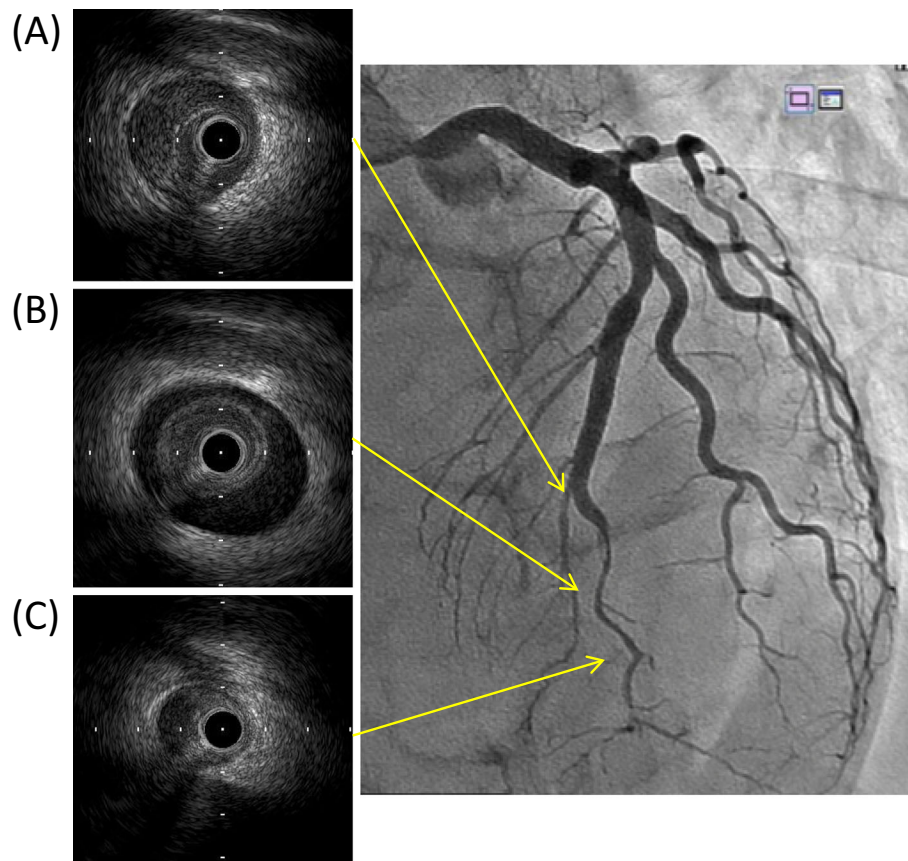


**Figure 2.** Approximately 99% stenosis of the proximal-left anterior descending coronary artery as revealed by coronary angiography.

99% stenosis of his distal-left anterior descending coronary artery (LAD, Fig. 2). Intravascular ultrasound (IVUS) revealed dissection of the media tunica and a hematoma pressing on the true lumen (Fig. 3); thus, SCAD in the lesion was confirmed. The cause of his chest pain was identified as STEMI due to SCAD in the LAD. Subsequently, sequential balloon expansions were performed, and the lesion was successfully stented (PROMUS Premier™ 2.5×38 mm; Fig. 4, IVUS images).

In a whole-body atherosclerosis screening, a dissecting aneurysm of the superior mesenteric artery (SMA) was revealed by contrast-enhanced computed tomography (CT). The diameter was 10 mm, and the length was 80 mm (Fig. 5). His upper abdominal pain observed at the previous hospital was thought to have been caused by SMAD. The dissecting lumen was partially occluded by thrombi, and there was no evidence of rupture or intestinal ischemia; thus, the lesion was dealt with by conservative medical treatment (hypotensive agents and aspirin). However, thrombi obstruction was not observed at the entry site of the

fraction (STEMI) and underwent emergent coronary angiography (CAG) because his symptoms persisted. CAG revealed



**Figure 3.** Intravascular ultrasound images before percutaneous coronary intervention. (A) The proximal region of spontaneous coronary artery dissection (SCAD). (B) The middle region of SCAD. (C) The distal region of SCAD.

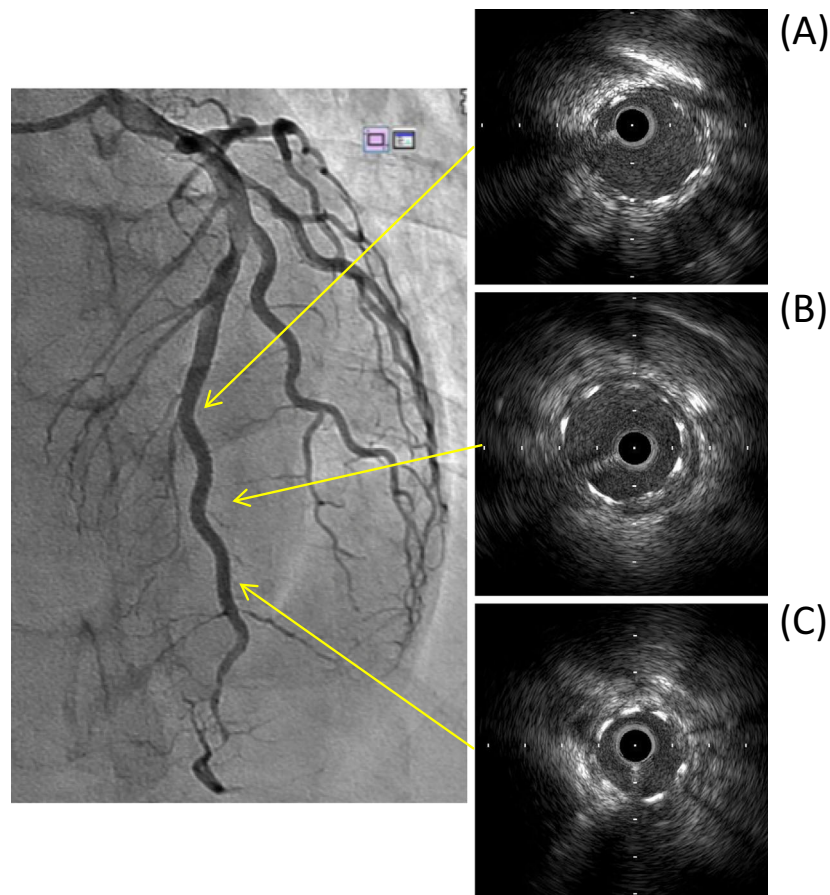
dissection on a follow-up contrast-enhanced CT scan. Stenting for SMAD was performed electively [Epic™ 8.0×40 mm (proximal side) + Epic™ 9.0×40 mm (distal side)], and the disappearance of the contract inflow to the false lumen was confirmed.

## Discussion

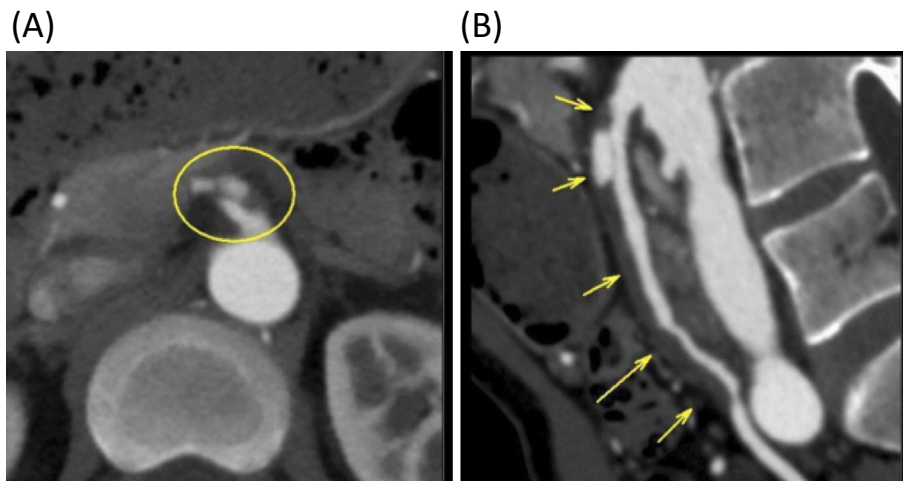
Idiopathic SCAD is a cause of sudden death in healthy young adults, with Pretty et al. reporting the first case in 1931 (1). SCAD is a rare disease for which the frequency has been reported to be approximately 0.1% to 1.1% in consecutive coronary angiography cases (2, 3). However, the presence of SCAD has been reported in cases of either acute coronary syndrome or sudden death at rates ranging from 0.1 to 0.4% (2, 4). Approximately 80% of patients suffering from this disease are 30- to 70-year-old females. None of the patients presented with either coronary risk factors or significant symptoms prior to the onset of SCAD. The causes of coronary artery dissection remain unclear, but puerperium, coronary spasm, arteriosclerosis, collagen diseases and SCAD have been described as possible contributors (5). On autopsy of confirmed cases, eosinophilic infiltration and medial cystic necrosis were observed in a significant percentage of cases and thus were assumed to be the mechanisms of coronary artery dissection (6).

With regard to the treatment of SCAD, if the coronary artery dissections are left and distal coronary artery flow is maintained, then conservative medical therapy is acceptable (7). Some studies have reported that revascularization by either percutaneous coronary intervention (PCI) or coronary artery bypass surgery ameliorated the symptoms and reduced the mortality rate (4, 6). A recently published comprehensive review stated that there was no definitive guideline regarding the treatment of SCAD (8). In the present case, the patient's symptoms persisted, and he was diagnosed with STEMI, after which he underwent emergent PCI, as advised in other publications. A trial using data from a registry called DISCOVERY (DISsection of COronary arteries: Veneto and Emilia RegistrY), which provides guidance on the most appropriate therapeutic approach to SCAD, is ongoing at present (9); our case underscores the importance of the results of this trial for ensuring patient health.

Idiopathic isolated SMAD is rare, with Bauersfeld et al. first reporting a case in 1947 (10). The incidence ratios have been reported as 0.06% (11) in autopsy cases and 0.6% in patients undergoing abdominal CT in the ED (12). The pathogenesis and progression of SMAD has not been elucidated, with the listed causes including arteriosclerosis, medial necrosis, fibromuscular dysplasia (FMD), vasculitis, segmental arterial mediolysis (SAM), iatrogenesis and trauma (13). The methods of treatment are conservative



**Figure 4.** Intravascular ultrasound images after percutaneous coronary intervention. (A) The proximal region of spontaneous coronary artery dissection (SCAD). (B) The middle region of SCAD. (C) The distal region of SCAD.



**Figure 5.** Superior mesenteric artery dissection as revealed by contrast-enhanced computed tomography. (A) Transverse plane. (B) Sagittal plane.

treatment, surgical treatment and intravascular stenting (14, 15). Stent therapy is a novel therapeutic approach that has been adapted to SMAD and only recently has been employed as a treatment option. Conservative treatment includes anticoagulation therapy, antiplatelet therapy and observation without medical therapy (12, 16-18).

A literature search turned up no reports of cases of con-

comitant SCAD and SMAD. Recently, in the cardiovascular field, the relationship between SCAD and FMD has been discussed (19). In addition, studies in the abdominal vascular field have suggested the involvement of SAM with SMAD. Although there are many questions regarding the causes of SAM, the leading theories include the distribution of the affected vessel, precursor lesions of FMD showing a

similar appearance and similar diseases serving as a precursor (20). Although SCAD and SMAD have been previously discussed in different regions within the body, we experienced a case in which both diseases were assumed to be associated with medial degeneration and were presumed to have a similar pathology. Of note, accumulating evidence indicates that SAM is a rare vasculopathy of unknown etiology characterized by the disruption of the arterial medial layer, with resultant susceptibility to vessel dissection (21). Although the abdominal visceral arteries are most frequently affected in SAM (22), any vessel may be involved, including the coronary arteries (23). Thus, the underlying mechanism in this rare case was assumed to be the concurrence of SAM in the coronary and abdominal arteries.

The only limitation of this assumption was that systemic factors, such as humoral factors, or fluctuations in the blood pressure might also have led to SCAD and SMAD. Thus, further pathophysiological and molecular physiological studies, including animal experiments, may be required to verify our theories.

Despite this limitation, to our knowledge, this is the first case of the spontaneous concurrence of SCAD and SMAD, which may have been due to a similar pathological background for these two diseases.

**The authors state that they have no Conflict of Interest (COI).**

#### Acknowledgement

We would like to thank all of the paramedical staff and clinical secretaries for their support of this work.

#### References

1. Pretty HC. Dissecting aneurysm of coronary artery in a woman aged 42: rupture. *BMJ* **i**: 667, 1931.
2. Paraskevaidis S, Theofilogiannakos EK, Chatzizisis YS, et al. Spontaneous dissection of right coronary artery manifested with acute myocardial infarction. *Open Cardiovasc Med J* **4**: 178-180, 2010.
3. Kamran M, Guptan A, Bogal M. Spontaneous coronary artery dissection: case series and review. *J Invasive Cardiol* **20**: 553-559, 2008.
4. Yip A, Saw J. Spontaneous coronary artery dissection - a review. *Cardiovasc Diagn Ther* **5**: 37, 2015.
5. Basso C, Morgagni GL, Thiene G. Spontaneous coronary artery dissection: a neglected cause of acute myocardial ischaemia and sudden death. *Heart* **75**: 451-454, 1996.
6. Shamloo BK, Chintala RS, Nasur A, et al. Spontaneous coronary artery dissection: aggressive vs. conservative therapy. *J Invasive Cardiol* **22**: 222-228, 2010.
7. Tanis W, Stella P, Pijlman A, Kirkels J, Peters R, De Man F. Spontaneous coronary artery dissection: current insights and therapy. *Neth Heart J* **16**: 344-349, 2008.
8. Saw J, Mancini GJ, Humphries KH. Contemporary review on spontaneous coronary artery dissection. *J Am Coll Cardiol* **68**: 297-312, 2016.
9. Fontanelli A, Olivari Z, La Vecchia L, et al. Spontaneous dissections of coronary arteries and acute coronary syndromes: rationale and design of the DISCOVERY, a multicenter prospective registry with a case-control group. *J Cardiovasc Med* **10**: 94-99, 2009.
10. Bauersfeld SR. Dissecting aneurysm of the aorta: a presentation of fifteen cases and a review of the recent literature. *Ann Intern Med* **26**: 873-889, 1947.
11. Foord A, Lewis R. Primary dissecting aneurysms of peripheral and pulmonary arteries: dissecting hemorrhage of media. *Arch Pathol* **68**: 553, 1959.
12. Kimura M, Matsuda T, Fukase K, et al. Clinical study of dissection of the superior mesenteric artery. *Nihon Shokakibyō Gakkai Zasshi* **99**: 145-151, 2002 (in Japanese, Abstract in English).
13. Park YJ, Park KB, Kim D-I, Do YS, Kim D-K, Kim Y-W. Natural history of spontaneous isolated superior mesenteric artery dissection derived from follow-up after conservative treatment. *J Vasc Surg* **54**: 1727-1733, 2011.
14. Zerbib P, Perot C, Lambert M, Seblini M, Pruvot FR, Chambon JP. Management of isolated spontaneous dissection of superior mesenteric artery. *Langenbecks Arch Surg* **395**: 437-443, 2010.
15. Froment P, Alerci M, Vandoni R, Bogen M, Gertsch P, Galeazzi G. Stenting of a spontaneous dissection of the superior mesenteric artery: a new therapeutic approach? *Cardiovasc Intervent Radiol* **27**: 529-532, 2004.
16. Takayama H, Takeda S, Saitoh SK, Hayashi H, Takano T, Tanaka K. Spontaneous isolated dissection of the superior mesenteric artery. *Intern Med* **41**: 713-716, 2002.
17. Suzuki S, Furui S, Kohtake H, et al. Isolated dissection of the superior mesenteric artery. *Abdom Imaging* **29**: 153-157, 2004.
18. Kumazawa S, Takizawa S, Okuma H, Shinohara Y. Crossed pontine infarction caused by vertebro-basilar artery dissection. *Intern Med* **44**: 520-521, 2005.
19. Saw J, Ricci D, Starovoytov A, Fox R, Buller CE. Spontaneous coronary artery dissection: prevalence of predisposing conditions including fibromuscular dysplasia in a tertiary center cohort. *JACC Cardiovasc Interv* **6**: 44-52, 2013.
20. Morishima A. A Surgical treated case of celiac artery aneurysm due to segmental arterial mediolysis. *Jpn J Vasc Surg* **17**: 471-474, 2008.
21. Baker-LePain JC, Stone DH, Mattis AN, Nakamura MC, Fye KH. Clinical diagnosis of segmental arterial mediolysis: differentiation from vasculitis and other mimics. *Arthritis Care Res (Hoboken)* **62**: 1655-1660, 2010.
22. Slavin RE. Segmental arterial mediolysis: course, sequelae, prognosis, and pathologic-radiologic correlation. *Cardiovasc Pathol* **18**: 352-360, 2009.
23. Slavin RE, Cafferty L, Cartwright J Jr. Segmental mediolytic arteritis: a clinicopathologic and ultrastructural study of two cases. *Am J Surg Pathol* **13**: 558-568, 1989.

The Internal Medicine is an Open Access article distributed under the Creative Commons Attribution-NonCommercial-NoDerivatives 4.0 International License. To view the details of this license, please visit (<https://creativecommons.org/licenses/by-nc-nd/4.0/>).