



Case Report

Intra cardiac thrombus in critically ill patient with coronavirus disease 2019: Case report



Ghizlane EL aidouni^{a,*}, Manal Merbouh^a, Mohammed Aabdi^a, Amine Bouabdallaoui^a, Houssam Bkiyar^a, Nabila Smaili^b, Nouha Elouafi^b, Brahim Housni^{a,c}

^a Intensive Care Unit, Mohammed VI University Hospital Center, Mohammed first University, Faculty of medicine and pharmacy, Oujda, Morocco

^b Cardiology Department, Mohammed VI University Hospital Center, Mohammed first University, Faculty of medicine and pharmacy, Oujda, Morocco

^c Mohammed First University, Faculty of medicine and pharmacy, LAMCESM, Oujda, Morocco

ARTICLE INFO

Keywords:

COVID-19
Thrombus
Cardiac cavity
Coagulation
Echocardiography
Case report

ABSTRACT

Introduction: With the outbreak of COVID-19, the number of cardiac manifestations related to this virus was more remarkable, among them heart thrombus (HTH) which is considered as a rare and severe complication associated with thromboembolic phenomena.

Methods: We present case report of 4 patients who presented heart thrombus as a complication of COVID-19.

Cases report management: During the pandemic, these patients were presented to our center for respiratory symptoms related to COVID-19 infection. All of them was hemodynamically unstable. On further assessment, Diagnosis was confirmed by trans -thoracic echography, one patient (1/4) had left ventricle thrombus, one patient (1/4) had right atrium thrombus and right ventricle thrombus was dominated in the rest of patients (2/4). Therapeutic component was based on unfractionated heparin and fibrinolytic.

Conclusion: COVID-19 patients could represent a population at high risk of HTH. Multidisciplinary approach and bed routine transthoracic echography can enhance the management of this cardiac complication.

1. Introduction

Coronavirus disease 2019 (COVID-19) is usually manifests with severe acute respiratory syndrome, cardiac manifestations can also be related to this infection.

A clinically significant effect of the inflammation is coagulopathy. Thrombosis events has quickly emerged as a major-medical challenge since a significant rate of patients were thrombosed, despite well-conducted curative anticoagulation [1].

It is important to note that up to a third of these thrombosis events are diagnosed in initial admission of patients to intensive care unit. These Patients presents a high death rate, it is therefore a major prognostic factor [2].

In this report, we describe our experience with 4 critically ill coronavirus disease 2019 patients who developed intra cardiac thrombus as a cardiovascular complication.

2. Case report 1

A 47 years old female, with history of psychosis, presented to the emergency department after nine days of symptoms with chest pain, dyspnea and fever, Physical examination showed a low blood pressure (80/40 mmHg), tachycardia (130 bpm) and pulmonary crackles with positive homans sign, she was hypoxic, with an SpO₂ of 70% and 50 mmHg of partial pressure of oxygen in the arterial blood (PaO₂). Her blood work demonstrated a high level of D-Dimer, Fibrinogen, Troponin, Ferritin, elevated inflammatory markers (CRP, white blood cells, LDH) with low prothrombin ratio, lymphopenia, and acute renal failure, IL6 analysis was not available at that time in our city (Table 1).

Diagnosis of COVID-19 pneumonia was based on PCR and CT scan that revealed a bilateral ground-glass opacity with crazy paving pattern estimated at 30% (Fig. 1). The ECG showed a right axis deviation with no abnormality of cardiac muscle repolarization, Transthoracic echocardiogram (TTE) however, revealed a dilated cardiomyopathy with ejection fraction of 10% and intra left ventricular mobile thrombus,

* Corresponding author.

E-mail addresses: elaidounighizlane@gmail.com (G. EL aidouni), manal.mrb@gmail.com (M. Merbouh), med.aabdi@gmail.com (M. Aabdi), aminebouabdallaoui1992@hotmail.com (A. Bouabdallaoui), 7b.houssam@gmail.com (H. Bkiyar), nibilette@yahoo.fr (N. Smaili), el.nouha@hotmail.com (N. Elouafi), brahimhousni@yahoo.fr (B. Housni).

<https://doi.org/10.1016/j.amsu.2021.102434>

Received 20 April 2021; Received in revised form 17 May 2021; Accepted 22 May 2021

Available online 26 May 2021

2049-0801/© 2021 The Authors. Published by Elsevier Ltd on behalf of IJS Publishing Group Ltd. This is an open access article under the CC BY-NC-ND license

(<http://creativecommons.org/licenses/by-nc-nd/4.0/>).

Table 1
Laboratory characteristics of Patients infected with COVID-19 infection.

	CASE 1	case 2	case 3	CASE 4
white cell count(μ l)	30310	12560	15300	16180
lymphocyte count(μ l)	120	460	290	410
LDH count(U/L)	3070	969	3325	1492
Creatinine(mg/l)	26	20	22.3	12
FIBRINOGEN(g/l)	9.2	4.3	7.6	4.5
D-dimer(mg/l)	5.2	6.7	22	4.2
CRP(mg/l)	114	213	259	277.29
Hypersensitive cardiac troponin (ng/l)	100	230	484	199
Ferritine(μ g/l)	967	2241	3937	1372
PCT(ng/ml)	5.7	0.7	7.5	2.5
Prothrombin RATIO (%)	37	87	70	65

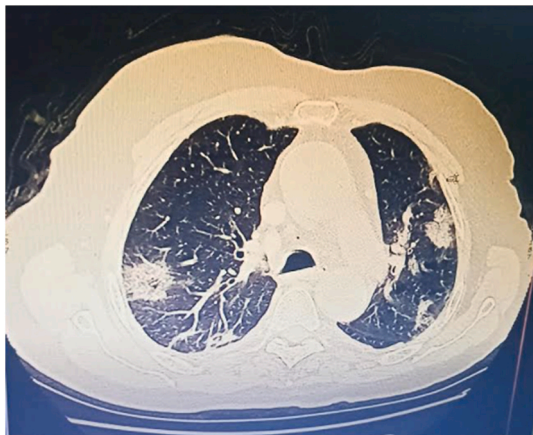

Fig. 1. CT scan of patient infected with SARS COV2.

Hemodynamic variables was assessed by Vigelio system that showed a low cardiac index (1.9 l/min.m²), abnormal stroke volume variation (14%) and high systemic vascular resistance (2300 dyne-sec.m²/cm⁵). It was decided to perform a doppler echocardiography based on positive homans sign. The results showed à Deep vein thrombosis in the middle part of the superficial right femoral vein arriving at the right popliteus vein with an occlusion of the left superficial and deep femoral artery. The patient was admitted to the operating room, under spinal anesthesia, with Fogarty embolectomy of the femoral artery. Fresh thrombotic material was removed, which was sent for histological assessment.

Medical Treatment was based on oxygen supplementary 5 l/min via nasal cannula, on the second day of stay, continuous positive airway pressure was indicated as oxygen support beside Dexamethasone (6 mg per day while 10 days), antibiotics and curative anticoagulation (Tinzaparine 175 UI/kg per day), Hemodynamic instability appeared on the second day of stay required vasoactive drugs (Noradrenaline 0.25 mcg/kg/min, Dobutamine 0.5 mcg/kg/min), Renal function was improved by fluid administration with no need of hemofiltration.

Her ICU course was unremarkable and with no need of mechanical ventilation, her oxygenation and hemodynamic state was improved and the patient was leaving the hospital with no need of oxygen support after 30 days of stay without adverse and unanticipated events noted.

3. Case report 2

An 85-year-old Women, admitted in the emergency after 15 days of symptoms with high fever, dry cough, rhinorrhea, asthenia, diarrhea and dyspnea. One day after her admission, she was transferred in the intensive care unit (ICU) department due to hypoxemic respiratory failure. She was diagnostic with COVID-19 infection and her Nucleic acid test was positive.

In the ICU, her past medical history indicated that she had systemic

hypertension, treated with angiotensin-converting enzyme inhibitor, diuretics, well controlled diabetes treated with insulin and chronic kidney failure without hemodialysis. Physical examination showed a deterioration of general conditions, fever at 39 °C, normal hemodynamic state, pulmonary crackles and her SpO₂ was at 68%. She was hypoxemic at the arterial blood gas (PaO₂ 62 mmHg), oxygen therapy was delivered by a high concentration mask with a flow of 15 l/min.

The complete blood count showed a troponin I, C-reactive protein and white blood cells high respectively, normal hemostasis, normal fibrinogen, kidney failure, high level of ferritin and D-dimer, IL6 analysis was not available at that time in our city (Table 1). The ECG 12-lead showed sinus normocardia with heart rate of 86 bpm, normal axis and right fascicular block (Fig. 2). Computed tomography (CT) scan showed 90% of lung damage (Fig. 3). Transthoracic echocardiogram (TTE) reveled hypertrophy left ventricle with a preserved ejection fraction of 55%, the right ventricular was dilated with limited function and intra right cavity thrombus about 14 mm in length (Fig. 4).

The medical treatment was initiated by antibiotics, corticosteroids (Dexamethasone 6mg per day), and preventive anticoagulation by Tinzaparine (125 000 UI per day).

On the second day of stay, hypercapnia was revealed by the arterial blood gas (PCO₂ 67, PO₂ 50), however a non-invasive ventilation (NIV) sessions were indicated. On the 5 day of stay, she presented with dyspnea and agitation, her arterial blood gas showed hypoxemia whence oro-tracheal intubation was indicated. The ventilation was set in pressure control mode as followed: pressure control 15 cmH₂O, PEEP 10 cmH₂O, tidal volume 6 ml/kg, respiratory rate 18/min, FiO₂ 0.75; static compliance of 48 ml/cmH₂O and a PaO₂/FiO₂ ratio of 98.6 mmHg was recorded. Vasoactive drugs were administered by norepinephrine at a dose of 0,05 mcg/kg/min and dobutamine at a dose of 2 mcg/kg/min following hemodynamic instability. On the same day of stay, a routine bedside TTE was performed resulting a severe dysfunction of right ventricular, a hyperechoic and mobile mass, about 9 mm in width and 17 mm in length.

A Vigiléo (Vigiléo™, Vigiléo-FloTrac sensor™, Edwards, Life-Science) monitoring system found a low cardiac index (2.0 l/min.m²) and high systemic vascular resistance (2580 dyne-sec.m²/cm⁵) hence a decrease the norepinephrine to 0,05 mcg/kg/min and an increase in the flow of dobutamine to 4,6 mcg/kg/min and.

The medical team mutually agreed to start therapeutic by fibrinolytic treatment (Actilyse 100mg within 2h) after eliminating the contraindication of thrombolysis treatment, followed by anticoagulation with unfractionated heparin, with a targeted activated coagulation time (ACT) of 170–190 seconds. On the 7 day of stay, the patient was hemodynamic impairment complicated by cardiac arrest.

4. Case report 3

Our intensive care unit received a 62-year-old female diagnosed with

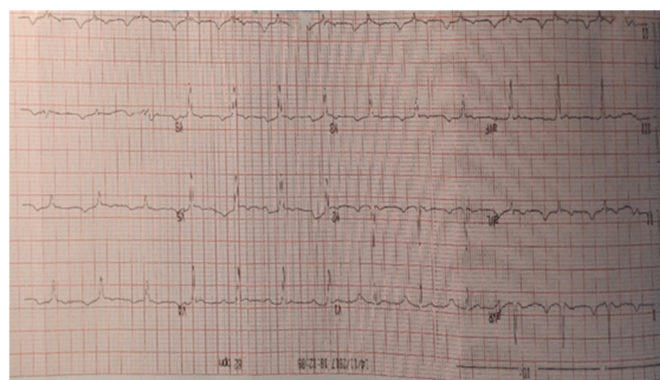


Fig. 2. ECG 12-lead with right fascicular block.

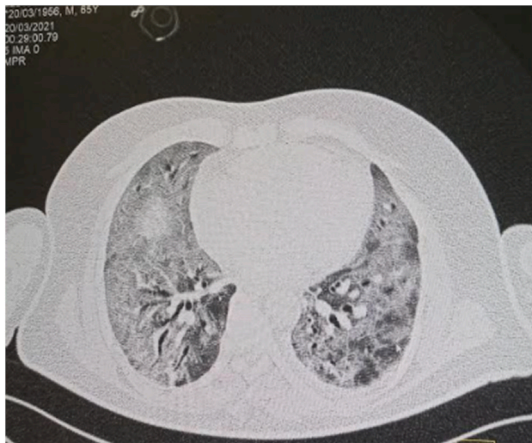

Fig. 3. CT scan of patient infected with SARS COV2.

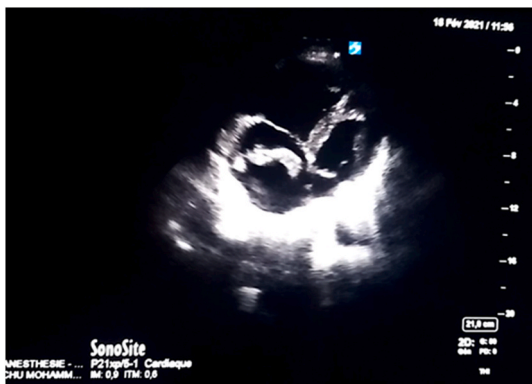

Fig. 4. Intra right cavity thrombus about 62 mm in length of patient infected with SARS COV2.

SARS-CoV-2 from a regional hospital with non-invasive ventilation. Her past medical history included pulmonary fibrosis with 87% basic SpO₂ while breathing room air. Clinical signs was muscle soreness, dry cough, and fever for 4 days, her general condition rapidly deteriorates and developed acute respiratory distress syndrome, state of shock and multiple organ failure. Her SpO₂ on admission was at 40%, the arterial blood gas was hypoxemic (PaO₂: 28 mmHg) despite non-invasive ventilation with 12 cmH₂O of PEEP and 100% of FiO₂, Her blood work demonstrated a high level of D-Dimer, Fibrinogen, Troponin, Ferritin, elevated inflammatory markers (CRP, white blood cells, LDH), lymphopenia and acute renal failure, IL6 analysis was not available at that time in our city, echocardiogram revealed a dilated right cavities with a mobile, linear and large-sized (3.3 × 0.6 cm) echogenic thrombus in the right atrium (Fig. 5), left ventricular ejection fraction was at 35%. She was intubated immediately after non improvement of arterial blood gas test, vasoactive drugs was introduces (Dobutamine 1 mcg/kg/min, Noradrenaline 0.3 mcg/kg/min), Anticoagulation therapy (unfractionated heparin 500 UI/kg per day) and antibiotic was started. After the non-improvement of the FiO₂/PaO₂ ratio (50) despite of early protective ventilation and the presence of cardiogenic chock, the decision to set up veno arteriel extra corporeal membrane oxygenation (ECMO) was taken, after 2 days, the patient had no longer a cardiogenic chock which led us to switch to veno –venous ECMO, Acute renal failure was treated by continuous venovenous hemodiafiltration. 9 days later, the patient presented a cardiac arrest due to septic shock and multiorgan failure.

5. Case report 4

A 65-year-old man with emphysematous lungs and diabetes as his

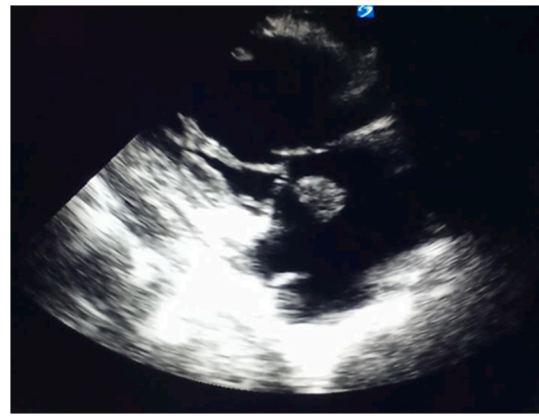


Fig. 5. Intra right cavity thrombus of patient infected with SARS COV2.

past medical history admitted to our service after 8 days of COVID-19 infection confirmed by Nucleic acid test with dyspnea as a main symptom.

Computed tomography (CT) scan confirmed diffuse ground-glass infiltrates of both lungs on emphysematous lungs. Physical examination showed a deterioration of general conditions, hemodynamic stability, pulmonary crackles and his SpO₂ at 59%. The arterial blood gas showed a hypoxemic respiratory failure (PaO₂ 54), oxygen therapy was delivered by Cipap facial mask with 12 PEP and 100% of FiO₂.

The ECG12-lead showed sinusual normocardia with a recorded heart rate of 79 bpm, normal axis and extrasystol. Transthoracic echocardiogram (TTE) reveled left ventricular ejection fraction at 48% associated to the mid-segment hypokinesia, right ventricular site of 10 × 10 mm thrombus with normal systolic function.

The blood analysis showed high troponin with high D-dimers, ferritin and normal hemostasis including fibrinogen. Increased C-reactive protein with white blood cells, IL6 analysis was not available at that time in our city.

The medical treatment was initiated by antibiotics, corticosteroids (Dexamethasone 6 mg per day), and curative anticoagulation by Enoxaparine 100 UI/kg/12h.

On the third day of his admission, he presented commotion state and his condition rapidly deteriorated. Cardiogenic shock was installed whence the decision of thrombolysis after eliminating the contraindication of fibrinolytic treatment (Actilyse 100mg within 2 hours) and he was intubated with early protective ventilation. Hemodynamic instability required vasoactive drugs (Noradrenaline 0.25 mcg/kg/min, Dobutamine 0.5 mcg/kg/min).

On the same day of stay, a routine bedside TTE was performed resulting a severe dysfunction of right ventricular, a hyperechoic and floating mass, about 10 mm in width and 12 mm in length in spite of curative anticoagulation.

Despite thrombolysis, the patient did not improve hemodynamic and he presented a cardiac arrest not recovered after massage.

This cases report follows care guidelines [3].

6. Discussion

This paper describes a rare complication of COVID-19 infection, an intra cavity heart thrombus.

Multiple studies have proven the relation between COVID-19 infection and coagulopathy with unknown cause [3]. The patient's clinical history and the morphology of the thrombus suggested a multifactorial etiology with as main cause of mortality after ARDS is heart cavity thrombus in these patients [4,5].

The most origin of a thrombus could be a consequence of pulmonary embolism. Enrico Merlo et al. on his paper explain that the presence of akinetic segments of the right ventricle could be the result of recent

myocardial ischemia [2].

The hypercoagulability parameters D-dimer and fibrinogen was showed highest in most of our patients, which reflect hypercoagulable status in patients with COVID-19 infection. However, D-dimer cannot be used as a reference to exclude the presence of a thrombus [6]. Studies are under way to build a decision algorithm using D-dimer specifically for Covid-19 patient. In addition, it is not recommended to use D-dimer in routine practice to monitor a possible hypercoagulable state or decide on a treatment [7,8]. Enrico Merlo et al. have highlighted the same result of our case series [2].

Routine bedside transthoracic echocardiogram (TTE) and a multi-disciplinary approach could be sensitive in early detection of heart thrombus which improve the diagnostic and therapeutic process at the right time and identify the risk of pulmonary embolism in order to better help the management of Covid-19 positive patient [2,8].

Anticoagulation with unfractionated heparin seemed to be the reasonable treatment for this rare cardiac complication of COVID-19 infection after eliminating any contraindication and in order to avoid the risk of bleeding following the use of this anticoagulants. Despite the frequent association of an intracardiac thrombus with pulmonary embolism, fibrinolysis appears to be an adequate treatment in certain cases, in particular in cases of right ventricular dysfunction [2,5,9]. There is no evidence of the superiority over the use of fibrinolytic and anticoagulation treatment in patients with an intracardiac thrombus after analyzing the impact on mortality between the two treatment [2,3].

Some studies demonstrate the link between acute pulmonary lesions induced by COVID-19 infection and thrombo-inflammatory response as well as hypercoagulability, the latter involves a therapeutic anticoagulation protocol in order to reduce the morbidity and mortality related to the COVID-19 pandemic [6,7,10,11].

Our patient was satisfied from our medical care.

The conclusion drawn from our cases report is the importance of TTE systematic practice on admission as well as ultrasound monitoring during patient hospitalization in order to reduce morbidity and mortality of our patients following the early diagnosis of this rare complication related to COVID-19.

7. Conclusion

While COVID-19 was considered as a lung disease infection, data has confirmed the systemic and hypercoagulable nature of this disease. Despite the incredible effort in research, many questions remain unanswered such as the algorithm for diagnosing thrombosis events in COVID-19 infection or the best strategy for anticoagulation.

Ethical Approval

The ethical committee approval was not required give the article type (case report). However , the written consent to publish the clinical data of the patients was given and is available to check by the handling editor if needed.

Consent

Obtained

Author contribution

EL AIDOUNI Ghizlane : Study concept , Data collection , Data

analysis , Writing the paper.

MERBOUH Manal : Study concept , Data analysis , Writing the paper
AABDI Mohammed : Data collection
BOUABDALLAOUI Amine : Contributor
Houssam Bkiyar : Supervision and data validation
ISMAILI Nabila Supervision and data validation
ELOUAFI Nouha Supervision and data validation
Brahim Housni : Supervision and data validation

Registration of Research Studies

This is not an original research project involving human participants in an interventional or an observational study but a case report . This registration is was not required .

Guarantor

EL AIDOUNI Ghizlane
MERBOUH Manal

Declaration of competing interest

None

References

- [1] A. Russell, Daniel B Holt Trigonis, Rebecca Yuan, Asma A. Siddiqui, K. Mitchell, Craft, Babar A. Khan, Rajat Kapoor, Omar Rahman, Incidence of venous thromboembolism in critically ill coronavirus disease 2019 patients receiving prophylactic anticoagulation, *Critical care Med* (2020 Jun 30).
- [2] Enrico Merlo, Giuseppe Grutta, Ivo Tiberio, Gabriele Martelli, Right heart thrombus in an adult COVID-19 patient: a case report, *J.Critical Care .Med.* 6 (4) (2020) 237–242.
- [3] David S. Riley, Melissa S. Barber, S Kienle Gunver, Jeffrey K. Aronson, Tido von Schoen-Angerer, Tugwell Peter, Helmut Kiene, Mark Helfand, Harold Sox Douglas G Altman, Paul G. Werthmann, David Moher, Richard A. Rison, Larissa Shamseer, Christian A. Koch, Gordon H. Sun, Patrick Hanaway, Nancy L. Sudak, Marietta Kaszkin-Bettag, E. James, Joel J Gagnier Carpenter, CARE guidelines for case reports: explanation and elaboration document, *J. Clin. Epidemiol.* 89 (2017 Sep) 218–235.
- [4] Adrija Hajra, Sheetal Vasundara Mathai, Somedeb Ball, Dhruvajyoti Bandyopadhyay, Maedeh Veysseh, Sandipan Chakraborty, Carl J. Lavie, S Aronow Wilbert, Management of thrombotic complications in COVID-19: an update, *Drugs* 80 (15) (2020 Oct) 1553–1562.
- [5] Francesca Mai, Rita Del Pinto, Claudio Ferri, COVID-19 and cardiovascular diseases, *J. Cardiol.* 76 (5) (2020 Nov) 453–458.
- [6] Wolfgang Miesbach, Michael Makris, COVID-19: coagulopathy, risk of thrombosis, and the rationale for anticoagulation, *Clin. Appl. Thromb. Hemost.* 26 (2020 Jan-Dec), 1076029620938149.
- [7] Jean M. Connors, H. Jerrold, Levy, COVID-19 and its implications for thrombosis and anticoagulation, *Blood* 135 (23) (2020 Jun 4) 2033–2040.
- [8] Jean M. Connors, H. Jerrold, Levy, Thromboinflammation and the hypercoagulability of COVID-19. *J.Thromb Hemostasis* 18 (7) (2020 Jul) 1559–1561.
- [9] L Dan Hu, Kan Liu, Bixi Li, Zhenhong Hu, Arge intracardiac thrombus in a COVID-19 patient treated with prolonged extracorporeal membrane oxygenation implantation, *Eur. Heart J.* 41 (32) (2020 Jun 1) 3104–3105.
- [10] N. Jansen, Anupamaa Seheult, Matthew D. Seshadri, Neal, Fibrinolysis shutdown and thrombosis in severe COVID-19, *J. Am. Coll. Surg.* (2020 Aug) 203–204.
- [11] Aram Baram, Fahmi H. Kakamad, Hadi M. Abdullah, Dana H. Mohammed-Saeed, Dahat A. Hussein, Shvan H. Mohammed, Binar B. Abdulrahman, Aram J. Mirza, Berwn A. Abdullah, Hawbash M. Rahim, Mohammed J. Rashid, Farhad F. Mohammed-Al, Yad N. Othman, Abdulwahid M. Salih, Large vessel thrombosis in patient with COVID-19, a case series, *Annals of Medicine and Surgery* (2020 Dec) 526–530.