



Endoscopic All-inside Repair of the Flexor Hallucis Longus Tendon in Posterior Ankle Impingement Patients

Akinobu Nishimura, M.D., Ph.D., Shigeto Nakazora, M.D., Ph.D., Naoya Ito, M.D., Aki Fukuda, M.D., Ph.D., Ko Kato, M.D., Ph.D., and Akihiro Sudo, M.D., Ph.D.

Abstract: Longitudinal flexor hallucis longus (FHL) tendon tears are sometimes complicated by posterior ankle impingement syndrome (PAIS), especially in ballet dancers. In recent years, PAIS has been treated endoscopically, but it is difficult to suture FHL tendon tears endoscopically. In this report, we describe how to suture the FHL tendon endoscopically with the Meniscal Viper Repair system (Arthrex, Naples, FL). Without our endoscopic technique, when a patient is found to have a longitudinal tear of the FHL under endoscopy, we must choose to either neglect the tear or convert to an open repair. Open tendon suture techniques have reportedly had relatively good results but require a longer skin incision than endoscopic surgery for PAIS. Compared with the open repair, the advantages of our technique include earlier recovery, less pain, a lower rate of soft tissue complications, and improved healing through better preservation of the blood supply. This technique is an attractive and useful option because it is an easy and safe method for longitudinal FHL tendon tears.

Posterior ankle impingement syndrome (PAIS) is an overuse syndrome of the posterior ankle. In this syndrome, patients experience posterior ankle pain that occurs predominantly with forced plantar flexion of the ankle.¹ The cause of this syndrome is an anatomic variation such as an os trigonum or a large posterior talar process (a Stieda process). We sometimes see this syndrome in athletes who perform repeated full plantar flexion of the ankle, such as ballet dancers and athletes involved in kicking sports. For this lesion, conservative treatment, such as anti-inflammatory medication, physical therapy, orthosis, and steroid injection, is indicated first. After failure of these conservative

treatments, surgical removal is applicable. Open excision through the posterolateral approach is reported to be highly successful. However, postoperative immobilization is usually necessary, and it takes a relatively long time for the patient to fully return to the previous sports activity level. Since van Dijk et al.² reported on a 2-portal endoscopic approach for PAIS, an increasing number of patients with PAIS have been treated successfully endoscopically. This endoscopic technique has some advantages over the open method because it is associated with less overall morbidity and quicker recovery.

Dancers who dance in en-pointe and demi-pointe positions require their ankles to be in extremes of plantar flexion.³ These positions of maximum plantar flexion can lead to excessive compressive forces on the posterior ankle, resulting in PAIS. Extreme plantar flexion in the demi-pointe and en-pointe positions with subsequent movement through the plié or grand plié position in one repetitive motion over time can cause irritation and inflammation of the flexor hallucis longus (FHL) tendon and tendon sheath. This FHL tendinopathy or pathology can be an isolated entity but can also coexist with PAIS. Hamilton et al.⁴ described that an FHL tendinitis can occur simultaneously with PAIS because of other causes such as os trigonum. Secondary degenerative changes can occur within the tendon with repeated inflammation.³ Thus, we can

From the Department of Orthopaedic and Sports Medicine, Graduate School of Medicine, Mie University, Tsu, Mie, Japan.

The authors report that they have no conflicts of interest in the authorship and publication of this article. Full ICMJE author disclosure forms are available for this article online, as [supplementary material](#).

Received March 7, 2017; accepted June 29, 2017.

Address correspondence to Akinobu Nishimura, M.D., Ph.D., Department of Orthopaedic and Sports Medicine, Graduate School of Medicine, Mie University, 2-174 Edobashi, Tsu, Mie 514-8507, Japan. E-mail: meiten@clin.medic.mie-u.ac.jp

© 2017 by the Arthroscopy Association of North America. Published by Elsevier. This is an open access article under the CC BY-NC-ND license (<http://creativecommons.org/licenses/by-nc-nd/4.0/>).

2212-6287/17312

<http://dx.doi.org/10.1016/j.eats.2017.06.059>

sometimes see longitudinal FHL tears with fraying. If we observe a longitudinal FHL tear under the posterior ankle hindfoot endoscopically, we need to consider switching to an open procedure or leaving it alone. The purpose of this study is to introduce the utility of endoscopic all-inside repair of the FHL, which has not been previously reported.

Surgical Technique

Patient Positioning

Surgery is performed under lumbar spinal anesthesia or general anesthesia. The patient is placed in the prone position (Table 1). A deflated pneumatic tourniquet is placed on the proximal femur before surgery in case of vascular injury, but it is not generally used. A flow pump system (Continuous Wave II Arthroscopy Pump, Arthrex, Naples, FL), which is adjusted from 30 to 50 mm Hg, is used throughout the surgical procedure. The ankle is positioned slightly over the distal edge of the operating table with a small cover cloth or triangular support under the distal part of the leg, allowing free movement of the ankle.

Portal Placement

The following landmarks are marked: lateral malleolus, medial malleolus, and Achilles tendon. We use the 2-portal technique according to van Dijk's report.⁵ The posterolateral portal is located proximal to and 0.5 cm anterior to the intersection of a straight line with the lateral border of the Achilles tendon. The posteromedial portal is located at the same level as the posterolateral portal but on the medial side of the Achilles tendon. The posterolateral portal is made first with a No. 11-blade scalpel, and the subcutaneous layer is spread with a mosquito clamp toward the web space between the first and second toes. After blunt dissection, a 2.5-mm, 30° short endoscope (ConMed Linvatec, Largo, FL) is inserted in the same direction. Next, the posteromedial portal is made with a vertical stab incision, and the subcutaneous layer is spread with a mosquito clamp.

Endoscopic Surgery for PAIS

Instruments introduced through the posteromedial portal are inserted perpendicular to the arthroscope until they are in contact. The mosquito clamp is then exchanged for a shaver (POWERMINI 2.9-mm Full Radius Blade, Dyonics POWERMINI Shaver System,

Table 1. Surgical Steps and Technical Tips

Surgical Steps	Technical Tips
Preoperative setting	The patient is prone, and the ankle is positioned slightly over the distal edge of the operating table.
Insertion of the arthroscope	A posterolateral portal is located proximal to and 0.5 cm anterior to the intersection of a straight line with the lateral border of the Achilles tendon. A posteromedial portal is located at the same level as the posterolateral portal, but on the medial side of the Achilles tendon. The posterolateral portal is used as the viewing portal and the posteromedial portal is used as the working portal.
Identification of the FHL tendon	The soft tissue is removed with a shaver and/or radiofrequency instrument to identify the FHL tendon.
Resection of the os trigonum and/or posterior talar process	The posterior talofibular ligament, talocalcaneal ligament, and flexor retinaculum are detached from the posterior talar prominence or os trigonum with an arthroscopic punch or scissors or a shaver or a radiofrequency device. Excision of the posterior talar prominence or os trigonum can be achieved piece by piece with cupped forceps.
Examination of the FHL tendon	The hallux is moved passively and checked with a probe to examine FHL tendon quality.
Setting of the suture instrument	If a longitudinal tear exists, we move to the suture step. The Meniscal Viper is inserted from the posteromedial portal and moved to the longitudinal portion of the FHL tendon. The needle penetrates the tendon when the thumb ring is pushed. Once the needle has captured the suture, the suture is released from the handle clip, and pulled back on the thumb ring.
Suture relay	When the Viper is removed, the suture loop is extracted from the joint space. We pass a 3-0 Vicryl thread into its 2-0 FiberWire loop, and pull the 2-0 FiberWire out. This Vicryl thread penetrates the site of the longitudinal FHL tendon tear.
Knot tying	The thread is fastened using a nonsliding knot technique. As a result, the new thread becomes the suture over the longitudinal tear site.
Additional suture	The FHL suture procedure steps are repeated, depending on the tear size. FHL sutures are usually placed 2 or 3 times.

FHL, flexor hallucis longus.

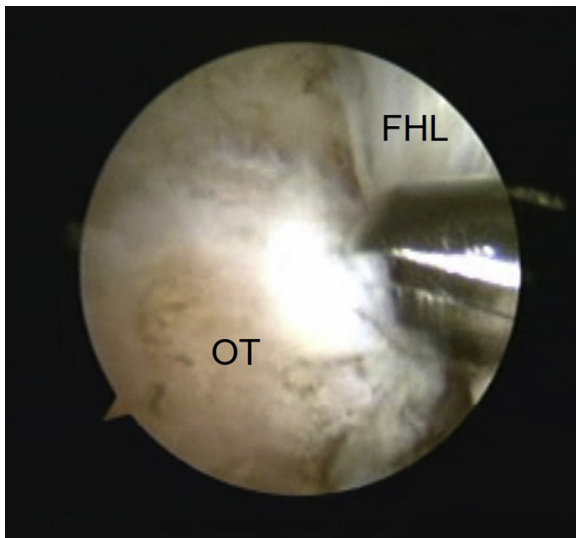


Fig 1. Endoscopic findings before the removal of the os trigonum. The arthroscope is used through a posterolateral portal with the instruments introduced through a posteromedial portal. After careful dissection, we identify the os trigonum or a hypertrophic posterior talar process and the FHL tendon. (FHL, flexor hallucis longus; OT, os trigonum.)

Smith & Nephew, Andover, MA) or a radiofrequency (RF) device (2.3-mm side probe [short], VAPR 3 system, Depuy Mitek, Westwood, MA). The subtalar joint capsule and the soft tissue are gently removed with these instruments. The synovial tissues between the talus and Achilles tendon are debrided with a shaver and/or an RF device. We then identify the os trigonum or a hypertrophic posterior talar process and the FHL tendon (Fig 1). If it is difficult to

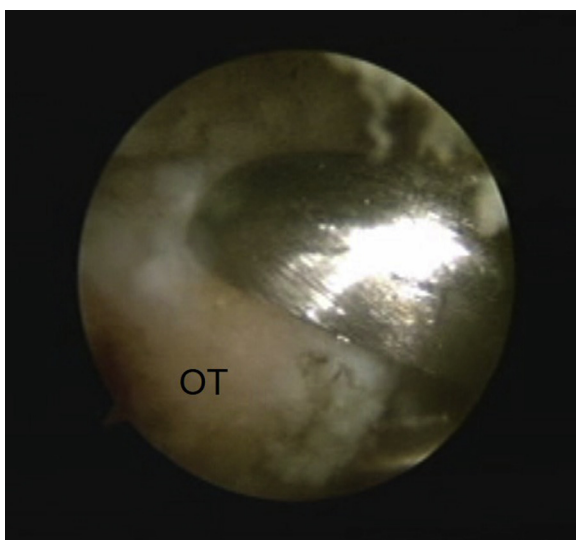


Fig 2. Resection of the os trigonum. The arthroscope is used through a posterolateral portal with the instruments introduced through a posteromedial portal. The os trigonum is removed with cupped forceps. (OT, os trigonum.)

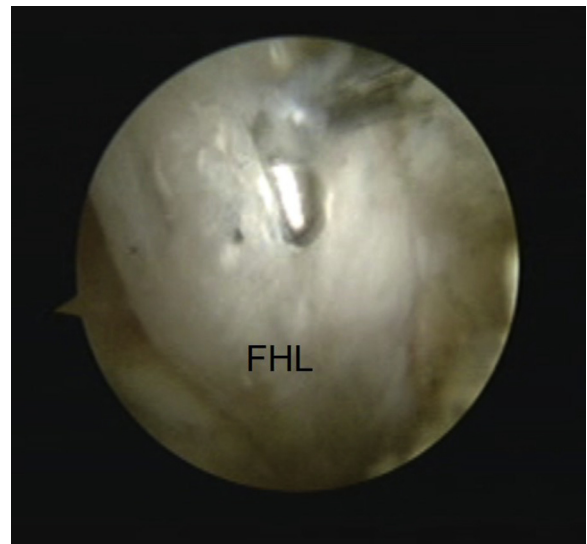


Fig 3. Longitudinal tear of the FHL tendon. The arthroscope is used through a posterolateral portal with the instruments introduced through a posteromedial portal. FHL tendon quality is checked with a probe. (FHL, flexor hallucis longus.)

recognize the FHL tendon, passive motion of the great toe may help in its identification. The FHL tendon is an important landmark. Because the neurovascular bundle runs just medial to the FHL tendon, the area lateral to the FHL tendon is regarded as safe for dissection.

The posterior talofibular ligament, the talocalcaneal ligament, and the flexor retinaculum attach to the posterior talar prominence or os trigonum. These structures are detached from the posterior talar

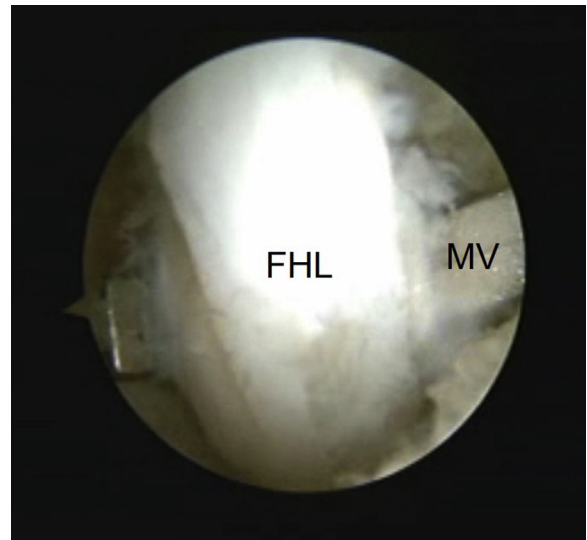


Fig 4. Meniscal Viper is placed on the flexor hallucis tendon. It is introduced through a posteromedial portal and is set on the posterior side of the FHL tendon in this case. (FHL, flexor hallucis longus; MV, Meniscal Viper.)

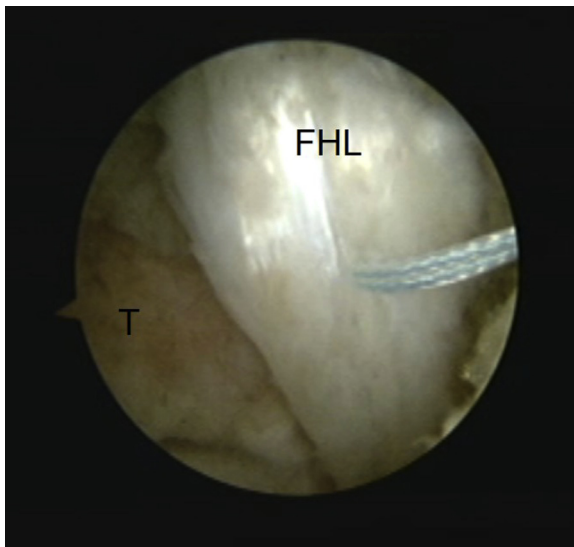


Fig 5. Looped thread penetrates the tendon tear site. The arthroscope is used through a posterolateral portal. A looped 2-0 FiberWire is passed through the FHL tendon after the trigger of the Meniscal Viper is pushed. (FHL, flexor hallucis longus; T, talus.)

prominence or os trigonum with an arthroscopic punch, scissors, a shaver, or an RF device. Excision of the posterior talar prominence or os trigonum can be achieved piece by piece with cupped forceps (Fig 2).

FHL Evaluation Under Endoscopy

After removal of the posterior talar prominence or os trigonum, the flexor retinaculum can be released until the FHL tendon at the level of the sustentaculum tali is

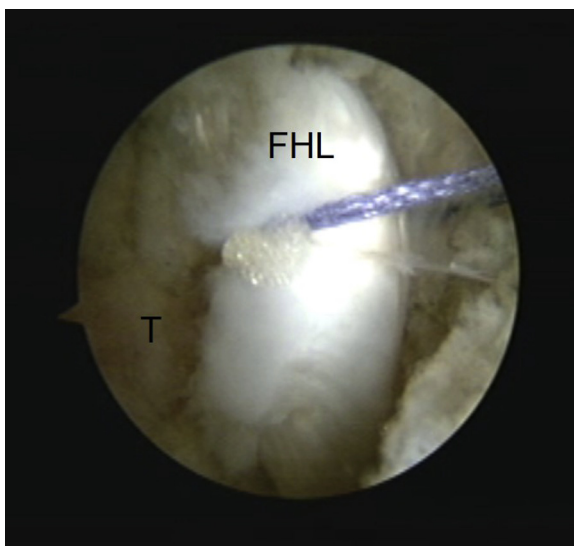


Fig 6. Shuttle relay passing through the FHL tear. The 3-0 Vicryl thread is passed into its 2-0 FiberWire loop, and the 2-0 FiberWire is pulled out. As a result, a 3-0 Vicryl is passed through the FHL tendon. (FHL, flexor hallucis longus; T, talus.)

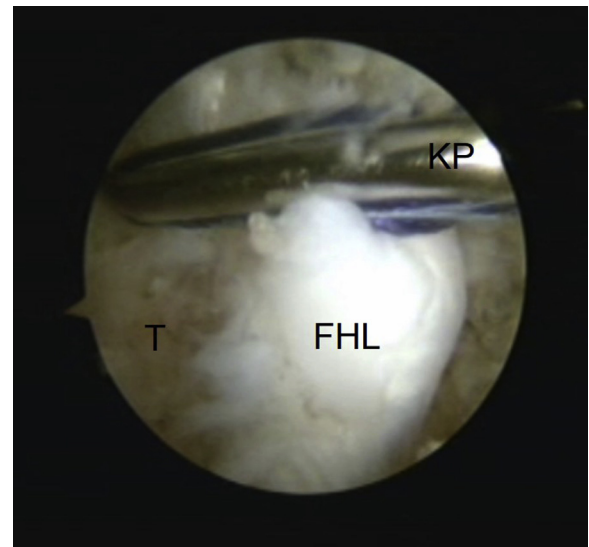


Fig 7. Knot tying with a knot pusher. The 3-0 Vicryl suture is fastened using a nonsliding knot technique with a knot pusher. (FHL, flexor hallucis longus; KP, knot pusher; T, talus.)

visible. On the proximal side, debridement is performed until the distal part of the peroneal muscle belly is inspected. FHL tendon quality is checked with a probe (Fig 3).

Endoscopic FHL Repair

If FHL tendon longitudinal tears are detected, suturing of the FHL tendon is performed. An all-inside meniscus repair device (Meniscal Viper Kit, Arthrex) is inserted from the posteromedial portal. Based on the

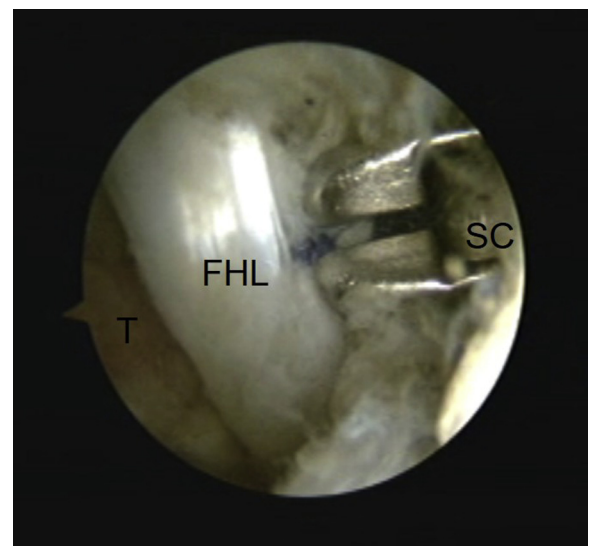


Fig 8. Cutting of the remnant thread tails. The arthroscope is used through a posterolateral portal with the instruments introduced through a posteromedial portal. The remnant tail threads are cut with an arthroscopic suture cutter. (FHL, flexor hallucis longus; SC, arthroscopic suture cutter; T, talus.)

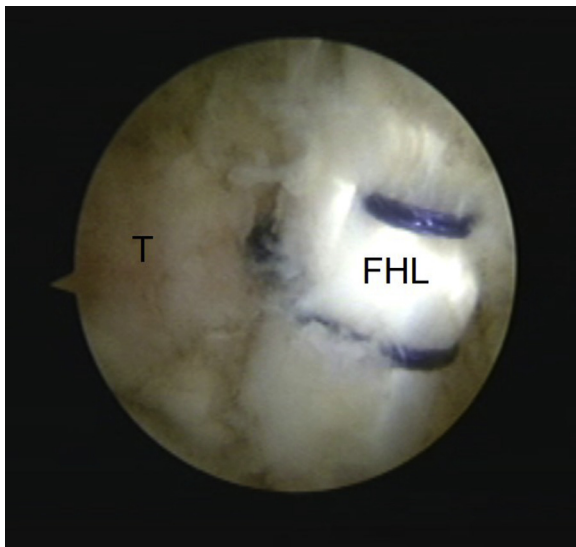


Fig 9. Endoscopic view of the sutured FHL. Suturing of the FHL is repeated 1 or 2 times, depending on the tear size. A posterolateral portal is used as a viewing portal. (FHL, flexor hallucis longus; T, talus.)

tear type, the device is set on the anterior or posterior⁶ side of the FHL tendon (Fig 4). Then, a looped thread (2-0 FiberWire, Arthrex) is passed through the FHL tendon when the instrument trigger is pushed. Once the trigger is returned and the instrument is taken out, both the loop end and 2 free ends of a thread are located outside the portal (Fig 5). Then, we pass a 3-0 Vicryl thread into its 2-0 FiberWire loop, and pull the 2-0 FiberWire out. As a result, a 3-0 Vicryl is passed through the FHL tendon (Fig 6). This thread is fastened using a nonsliding knot technique with a knot pusher (Fig 7). As a result, the new thread becomes the suture over the longitudinal tear site and the remnant thread tails are cut with an arthroscopic suture cutter (Suture Cutter, Arthrex) (Fig 8). This procedure is repeated 1 or 2 times, depending on the tear size (Fig 9). After finishing the FHL tendon sutures, we check the FHL tendon motion by moving the great toe. [Video 1](#) shows the real maneuver in an illustrative case.

Postoperative Care

No immobilization is necessary. Full weight-bearing is allowed as tolerated 1 day after surgery. Ankle and toe range of motion is permitted 1 day after surgery. Jogging is permitted 6 weeks after surgery and return to sports is permitted 2 months after surgery.

Discussion

The FHL tendon passes through a fibro-osseous tunnel between the 2 posterior tubercles as it runs from its origin on the fibula (laterally) to its insertion on the distal phalanx of the hallux. Tendinitis of the FHL tendon behind the medial malleolus of the ankle is one of the major causes of posterior ankle pain, which is known as

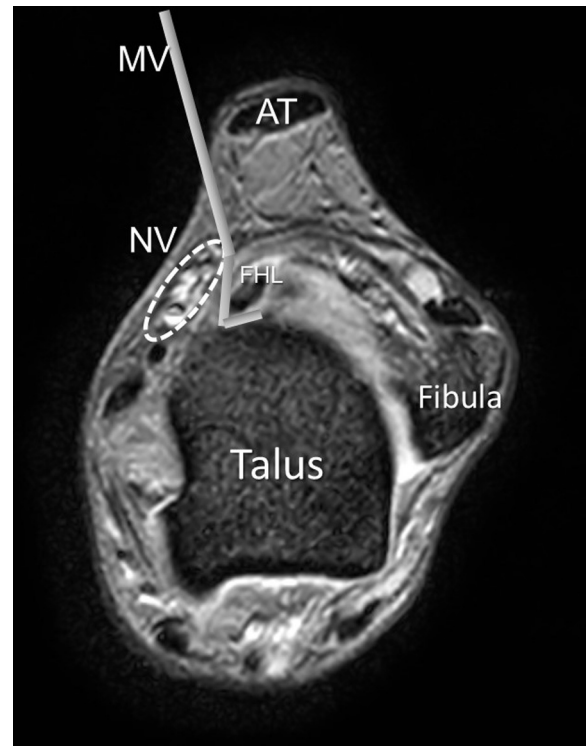


Fig 10. Magnetic resonance imaging schema of the relation between the Meniscal Viper and the neurovascular bundle. Axial T2-weighted MR image just above the talocalcaneal joint level. The Meniscal Viper is inserted through the posteromedial portal and protects a neurovascular bundle. (AT, Achilles tendon; FHL, flexor hallucis longus; MV, Meniscal Viper; NV, neurovascular bundle.)

“dancer’s tendinitis.”⁴ The FHL tendon then passes through a fibro-osseous tunnel behind the talus, like a rope through a pulley. As it passes through this pulley, it is often strained. When this occurs, rather than moving smoothly in the pulley, its movement becomes constricted. This binding causes irritation and swelling, leading to further binding, irritation, and swelling. This chronic cycle leads to FHL tendinitis. This tendinitis typically responds to the usual conservative measures. Safe and accurate injections can be performed into the FHL tendon sheath for diagnostic and therapeutic purposes under sonographic control.⁷ If the pain is relieved by this injection, the diagnosis is almost certain.

Relative rest in a removable walker boot to immobilize the first metatarsophalangeal joint is an important component of the therapy so that the chronic cycle previously described can be broken. Nonsteroidal anti-inflammatory drugs can be helpful. Failure of conservative treatment or recurrence of symptoms may be a sign of rents or longitudinal tears in the tendon.^{8,9}

Surgery is indicated when conservative treatment has failed. Generally, the posterolateral approach is indicated if the patient has an isolated PAIS without FHL tendinitis. However, if the patient has both PAIS and

Table 2. Advantages and Risks and/or Limitations of Endoscopic Suturing of Flexor Hallucis Longus Tendon Tears

Advantages	Risks and/or Limitations
We can assess the condition of a flexor hallucis longus tendon tear more clearly.	Ankle hindfoot endoscopic surgery has a steep learning curve.
This technique is easy and safe (Meniscal Viper can protect the neurovascular bundle).	This endoscopic technique requires specialized equipment (Meniscal Viper).
This endoscopic procedure leads to earlier recovery, less pain, a lower rate of soft tissue complications, and improved healing through better preservation of the blood supply.	It is difficult to mimic a buried running stitch under endoscopy with this system.

FHL tendinitis, the FHL is far from the lateral incision, making it difficult to evaluate the condition of the FHL. For these reasons, the posteromedial approach has been recommended for PAIS with FHL tendinitis. Hamilton et al.,⁴ Abramowitz et al.,⁶ and Marotta and Micheli¹⁰ reported relatively good results using these open procedures. Hamilton et al.⁴ reported results of their procedures on 30 patients (40 ankles). In their report, there were 3 wound infections, 2 wound hematomas, and 1 patient who had persistent dysesthesias around the scar. Marotta and Micheli¹⁰ reported results for 15 ankles in 12 patients. They reported 1 infection and 1 transient sensory neurapraxia of the tibial nerve. Abramowitz et al.⁶ reported their surgical results for 41 patients. Complications in their report included 8 nerve injuries, 1 wound infection, and 1 reflex sympathetic dystrophy. Van Dijk et al.² advocated the 2-portal arthroscopic approach for patients with PAIS. Other reports have shown that an endoscopic approach is better than the conventional open approach because the endoscopic procedure uses a smaller incision and allows wider visualization from the medial to lateral sides of the posterior ankle (including the FHL) than the open procedure. The dynamic pathology of FHL lesions can be easily understood and assessed, especially on passive motion of the hallux during endoscopy. Scholten et al.¹ reported 55 patients with PAIS treated endoscopically. In their report, a complication occurred in only 1 patient who had temporary loss of sensation of the posteromedial aspect of the heel. They also reported a median recovery time for sports activities of 8 weeks, with a mean American Orthopaedic Foot and Ankle Society score of 90 points at the time of follow-up. These results are better than previous reports about open procedures.^{4,6,10} Funasaki et al.¹¹ reported on arthroscopic release of the FHL tendon sheath. In their report, stenosing tenosynovitis of the FHL was treated by cutting the tendon sheath. However, without our technique, when a patient is found to have a longitudinal tear of the FHL under endoscopy, we must choose to either neglect the tear or convert to an open repair. Hamilton et al.¹² reported that they suture the FHL with 3-0 Vicryl when a longitudinal FHL tendon tear is present. We use their suture technique under endoscopy.

The Meniscal Viper Repair system and FAST-FIX 360 Meniscal Repair system (Smith & Nephew) as all-inside

meniscal repair systems have been approved for use in Japan. The FAST-FIX system contains two 5-mm polymer integrated bioinert anchors, with a pretied, self-sliding knot composed of nonabsorbable 2-0 suture. This system needs to penetrate the joint capsule and has a nonabsorbable anchor; thus, this system is not suitable for FHL repair. An advantage of the Meniscal Viper Repair system is that it does not need to penetrate the knee joint capsule and leaves only threads after suturing. We have used this system for suturing of the FHL tendon under endoscopy. By inserting this system from the posteromedial portal, we can protect the posterior tibial neurovascular structures (Fig 10). Moreover, we can easily thread the torn FHL tendon. Hamilton et al. reported that they use a buried running stitch of a 3-0 Vicryl suture for longitudinal FHL tears, so we used 3-0 Vicryl as well. However, it is difficult to mimic a buried running stitch under endoscopy (Table 2). We hope that a new knotless suture system or a new device that can create a buried running stitch will be developed.

In conclusion, we describe an endoscopic FHL tendon suture technique. Using the Meniscal Viper system, it is possible to suture longitudinal tears of the FHL tendon easily and safely. Moreover, this endoscopic procedure leads to earlier recovery, less pain, a lower rate of soft tissue complications, and improved healing through better preservation of the blood supply.

References

- Scholten PE, Sierevelt IN, van Dijk CN. Hindfoot endoscopy for posterior ankle impingement. *J Bone Joint Surg Am* 2008;90:2665-2672.
- van Dijk CN, Scholten PE, Krips R. A 2-portal endoscopic approach for diagnosis and treatment of posterior ankle pathology. *Arthroscopy* 2000;16:871-876.
- Moser BR. Posterior ankle impingement in the dancer. *Curr Sports Med Rep* 2011;10:371-377.
- Hamilton WG, Geppert MJ, Thompson FM. Pain in the posterior aspect of the ankle in dancers. Differential diagnosis and operative treatment. *J Bone Joint Surg Am* 1996;78:1491-1500.
- van Dijk CN, de Leeuw PA, Scholten PE. Hindfoot endoscopy for posterior ankle impingement. Surgical technique. *J Bone Joint Surg Am* 2009;91:287-298 (suppl 2).
- Abramowitz Y, Wollstein R, Barzilay Y, et al. Outcome of resection of a symptomatic os trigonum. *J Bone Joint Surg Am* 2003;85:1051-1057.

7. Mehdizade A, Adler RS. Sonographically guided flexor hallucis longus tendon sheath injection. *J Ultrasound Med* 2007;26:233-237.
8. Sammarco GJ, Miller EH. Partial rupture of the flexor hallucis longus tendon in classical ballet dancers: Two case reports. *J Bone Joint Surg Am* 1979;61:149-150.
9. Sammarco GJ, Cooper PS. Flexor hallucis longus tendon injury in dancers and nondancers. *Foot Ankle Int* 1998;19:356-362.
10. Marotta JJ, Micheli LJ. Os trigonum impingement in dancers. *Am J Sports Med* 1992;20:533-536.
11. Funasaki H, Hayashi H, Sakamoto K, Tsuruga R, Marumo K. Arthroscopic release of flexor hallucis longus tendon sheath in female ballet dancers: Dynamic pathology, surgical technique, and return to dancing performance. *Arthrosc Tech* 2015;4:e769-e774.
12. Hamilton WG. Posterior ankle pain in dancers. *Clin Sports Med* 2008;27:263-277.