

# A novel mutation in the ABCD1 gene of a Chinese patient with X-linked adrenoleukodystrophy

## Case report

Jing Wang, MD<sup>a,b</sup>, Qian Zhu, MD<sup>a,b</sup>, Hongqian Liu, MD<sup>a,b,\*</sup>

### Abstract

**Rationale:** X-linked adrenoleukodystrophy (X-ALD) is the most common peroxisomal disorder, which is inherited as an X-linked recessive trait. ATP binding cassette subfamily D member 1 (ABCD1) localized to Xq28 is the only gene associated with ALD.

**Patient concerns:** We report a case of Chinese boy with childhood cerebral ALD, who began experiencing symptoms at the age of 5 years and 2 months. Very long chain fatty acids analysis revealed high levels of C24/C22 ratio and C26/C22 ratio in the plasma. Magnetic resonance imaging (MRI) showed abnormal bilateral white matter lesions in brainstem, temporal, occipital, and parietal lobes.

**Diagnoses:** Direct sequencing of the ABCD1 gene identified a novel c.1502del mutation on exon 6, which causes a substitution of the 501st amino acid from methionine to serine and finally the 557th codon is changed to stop codon.

**Interventions:** Special education and rehabilitation therapy.

**Outcomes:** The disease progressed rapidly and resulted in death at the age of 8 years.

**Lessons:** Early detection of mutations in the ABCD1 gene may facilitate diagnosis, genetic counseling and potentially aid prenatal diagnosis of the disease.

**Abbreviations:** ABCD1 = ATP binding cassette subfamily D member 1, CCALD = childhood cerebral ALD, X-ALD = X-linked adrenoleukodystrophy.

**Keywords:** ABCD1, cerebellar, novel mutation, X-linked adrenoleukodystrophy

## 1. Introduction

X-linked adrenoleukodystrophy (X-ALD) is the most common peroxisomal disorder, which is inherited as an X-linked recessive trait, the frequency of hemizygotous plus heterozygotous is estimated to be 1:16,800.<sup>[1]</sup> ATP binding cassette subfamily D member 1 (ABCD1) localized to Xq28 is the only gene associated with ALD.

Editor: N/A.

This study was jointly funded by grants from the Program of Science and Technology Department of Sichuan Province (No. 2016FZ0116), the Research Project of Health and Family Planning Commission of Sichuan Province (No. 16ZD018), and the Applied Basic Research Program of Science and Technology Department of Sichuan Province (No. 2017JY0272).

The authors have no conflicts of interest to disclose.

<sup>a</sup> Department of Obstetrics and Gynecology, West China Second University Hospital, Sichuan University, Chengdu, <sup>b</sup> Key Laboratory of Birth Defects and Related Diseases of Women and Children (Sichuan University), Ministry of Education, China.

\* Correspondence: Hongqian Liu, Prenatal Diagnosis Center of Sichuan Province, West China Second University Hospital of Sichuan University, Chengdu, Sichuan 610041, China (e-mail: hongqian.liu@163.com).

Copyright © 2018 the Author(s). Published by Wolters Kluwer Health, Inc. This is an open access article distributed under the Creative Commons Attribution-NoDerivatives License 4.0, which allows for redistribution, commercial and non-commercial, as long as it is passed along unchanged and in whole, with credit to the author.

Medicine (2018) 97:21(e10837)

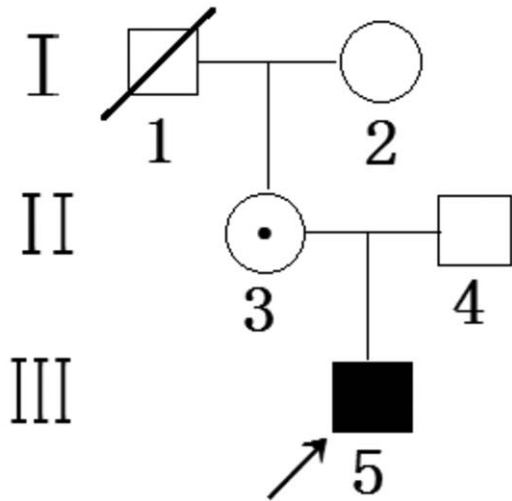
Received: 31 January 2018 / Accepted: 3 May 2018

<http://dx.doi.org/10.1097/MD.00000000000010837>

The disease is divided into 7 different phenotypes according to the age of onset, affected tissues, and the pace of progress: childhood cerebral ALD (CCALD), adolescent cerebral ALD (ACALD), adrenomyeloneuropathy (AMN), adult cerebral ALD (AALD), olivoponto-cerebellar (OPC), Addison (Addison only, AO) and asymptomatic.<sup>[2]</sup> CCALD and AMN are the most common phenotypes, accounting for 70% to 80% of patients with X-ALD.<sup>[2-3]</sup> In the present study, we report a Chinese patient with X-ALD derived from a novel mutation in exon 6 (NM\_000033.3) of the ABCD1 gene at nucleotide position c.1502 (c.1502del; p.Met501Serfs\*56) identified by direct Sanger sequencing and analysis of the entire coding region of the ABCD1 gene.

## 2. Case presentation

The patient was a boy, born to a nonconsanguineous family. His parents are healthy, but the boy's maternal grandfather died of illness at the age of 40 years (the family members cannot provide detailed information on disease) (Fig. 1). The boy was delivered vaginally at term with normal Apgar scores and weighed 3000 g at birth.<sup>[4]</sup> He showed a normal pattern of development, including raising his head steadily at 3 months, crawling at 9 months, speaking 2 to 3 words at 12 months, and walking steadily at 16 months. He performed well in kindergarten until the age of 5 years. The patient began experiencing symptoms at the age of 5 years and 2 months. The earliest symptom was acute vision drop, then poor attention, followed by decreased cognitive and motor abilities. The disease progressed rapidly. After 2 years the patient developed into a vegetative state, and died at the age of

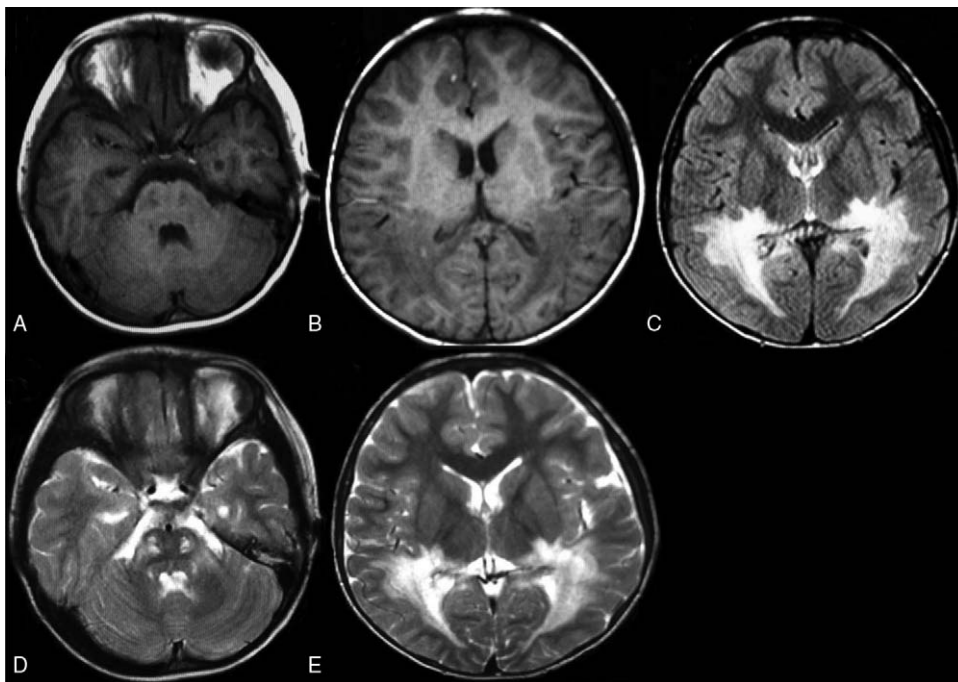


**Figure 1.** Pedigree of the present family. The proband is indicated by an arrow. Carrier female is designated by a circle with dot. Squares indicate males; circles indicate females.

8 years. Physical examination revealed slight neck rigidity, high muscle tone, hyperreflexia of both knees, and ankle jerks. Serum adreno-cortico-tropic-hormone ACTH was normal (23.5 ng/L; 5.0–78.0). VLCFA analysis by liquid chromatography-tandem mass spectrometry (LC-MS/MS) revealed high levels of C24/C22 ratio (1.63; 0.64–0.98) and C26/C22 (0.11; 0.01–0.07) ratio in the plasma. The visual evoked potential (VEP) showed a *prolonged latency of P100 wave in both eyes*. Magnetic

resonance imaging (MRI) showed abnormal bilateral white matter lesions in brainstem, temporal, *occipital, and parietal lobes* (Fig. 2). The brain MRI findings of the patient were consistent with the characteristic MRI changes of X-ALD.<sup>[5]</sup> The study protocol was approved by the Local Ethics Committee of West China Second Hospital, Sichuan University, and informed consent was provided by parents of individuals younger than 18 years old.

Genomic DNA was isolated from 2 mL of EDTA whole blood from the patient and his parents using the QIAamp DNA Blood Mini Kit (QIAGEN, Hilden, Germany) following the manufacturer's protocol. The concentration and purity of the extracted DNA were detected using a NanoDrop 2000 UV-vis spectrophotometer (Thermo Fisher Scientific, Waltham, MA). The 10 exons and the flanking intronic regions of the ABCD1 gene were tested for mutations in the X-ALD patient, his parents, and his maternal grandmother by sequence analysis. Polymerase chain reaction (PCR) primer pairs (Sangon Biotech, Shanghai, China) were synthesized according to reported ABCD1 sequences (Table 1).<sup>[6]</sup> DNA samples were amplified in a final volume of 50  $\mu$ L containing: 100 ng of genomic DNA, 0.2  $\mu$ M of each primer, 10x PCR buffer ( $Mg^{2+}$  free), 1.2 mM  $MgCl_2$ , 0.4 mM dNTP, and 1.25 unit r-Taq DNA polymerase (Takara, Dalian, China). PCR was performed with denaturation at 94°C for 30 seconds, annealing at 60°C to 71°C (Table 1) for 30 seconds, and extension at 72°C for 45 seconds for 30 cycles, with a final extension at 72°C for 10 minutes. All fragments were amplified in an ABI Veriti Dx thermal cycler (Thermo Fisher Scientific, Woodlands, Singapore). PCR products were directly sequenced using the ABI 3730 sequencer (Thermo Fisher Scientific, Tokyo, Japan). Sequencing results were analyzed using Chromas software (Technelysium; South Brisbane, Australia) and compared against ABCD1 sequence (gene ID: 215) referenced in the National Center for



**Figure 2.** Brain MRI of the patient. Decreased signal was observed of the white matter in T1 weighted (A and B) within the brainstem and emporal-occipital- parietal lobes. Increased signal was detected in Flair (C) and T2 weighted (D and E).

**Table 1****Primer sequences used for PCR amplification of the ABCD1 gene.**

Exon	Forward 5' 3'	Reverse 5' to 3'	Fragment length, bp	Annealing temperature, °C
1a	ACAACAGGCCAGGGTCAGA	AGGAAGGTGCGGCTCACCA	422	62
1b	AACCGGGTATTCCTGCAGCG	ACTGGTCAGGGTTGCGAAGC	385	60
1c	CCACGCCTACCGCCTCTACTT	AGACTGTCCCACCGCTC	484	60
2	GGCACTGGGAGACCCTG	TCAGCACCCAGCGGTATGG	332	60
3 and 4	GCAGAAGAGCCTCGCCTTTC	GCAGCAGGTGACACCTGCA	570	62
5	CTGCCAGGGATGGGAATGAG	TCTCACCTTGACCTTGGCCC	337	60
6	GCCATAGGGTACGGGAAGGG	GCCTCTGCAGGAAGCCATGT	276	60
7	CGATCCACTGCCCTGTTTTGG	CTTCCCTAGAGCACCTGG	491	62
8 and 9	CTGAGCCAAGACCATTGCCCCCG	TGCTGCTGCCGGGCCCGC	471	70
10	GAGGGGAGGAGGTGGCCTGGC	GCGGGGTGCGTGCATGGGTGG	427	71

Biotechnology Information (NCBI) using their Basic Local Alignment Search Tool (BLAST) (<http://www.ncbi.nlm.nih.gov/>).

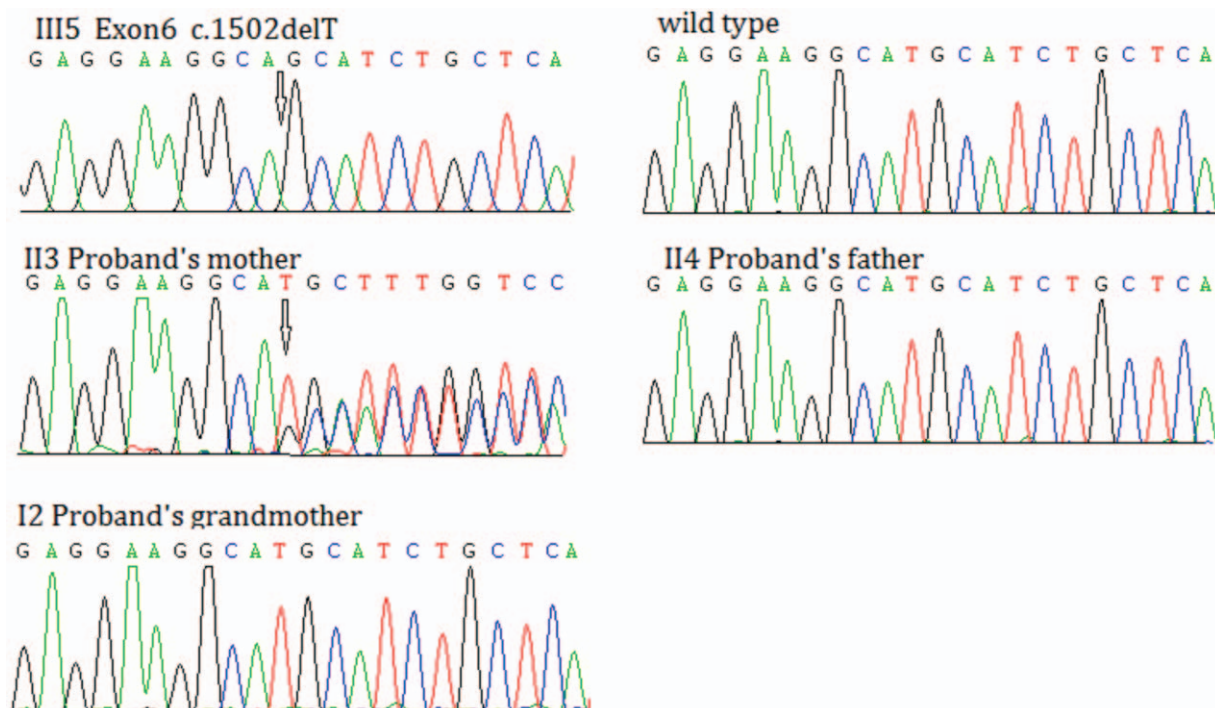
Sanger sequencing revealed a single-nucleotide deletion at nucleotide 1502 in exon 6 of the ABCD1 gene (Fig. 3). The c.1502del mutation causes a substitution of the 501<sup>st</sup> amino acid from methionine to serine and finally the 557<sup>th</sup> codon is changed to stop codon (p.Met501Serfs\*56).

### 3. Discussion

ABCD1 encodes a transporter protein of 745 amino acids, referred to as the adrenoleukodystrophy protein (ALDP). The gene consists of 10 exons spanning 20 kilobases (kb) of genomic deoxyribonucleic acid (DNA) and encodes a 4.2kb messenger ribonucleic acid (mRNA) transcript.<sup>[7]</sup> ALDP is an ATP-binding transport protein involved in the peroxisomal transport or catabolism of very long chain fatty acids (VLCFAs). Therefore, the dysfunction of

ALDP induces an accumulation of VLCFAs in tissues and body fluids, particularly C26:0 and C24:0, which will lead to a neurodegenerative disorder that affected the adrenal cortex, the spinal cord, the cerebellum and the cerebral cortex.<sup>[8,9]</sup>

In our study, we identified a novel frame-shift mutation in exon 6 (c.1502del; p.Met501Serfs\*56) of a Chinese patient that was inherited from his asymptomatic mother. It is worth noting that approximately 50% of female carriers develop a spastic paraparesis secondary to myelopathic changes similar to adrenomyeloneuropathy.<sup>[10]</sup> Therefore, for the female carriers, early diagnosis and treatment can greatly improve disease prognosis. If the female carrier gets pregnant again, the timely use of prenatal diagnosis can significantly reduce the frequency of the severe childhood cerebral phenotype. In our study, there is no mutation at nucleotide 1502 for the boy's maternal grandmother, so, his maternal grandfather may have carried the mutation at c.1502. His maternal grandfather died early, the disease was not



**Figure 3.** Sequence analysis of human ABCD1 gene. A c.1502delT mutation on exon 6 of the ABCD1 gene is identified in the proband (III5), his mother (II3) was an asymptomatic heterozygous carrier. Arrows indicate positions of the novel mutations. ABCD1 = ATP binding cassette subfamily D member 1.

diagnosed, and now cannot be confirmed by further genetic diagnoses. However, based on the available literature, there is no correlation between genotype and phenotype. Although the same mutation is present, the patients exhibit different clinical signs and biochemical aspects.<sup>[11,12]</sup> Therefore, it is possible that the c.1502del mutation was present in the maternal grandfather.

#### 4. Conclusions

This is the first report of a c.1502del mutation on exon 6 of the ABCD1 gene causing the CCALD. The c.1502del mutation causes a substitution of the 501st amino acid from methionine to serine and finally the 557th codon is changed to stop codon. Frameshift or nonsense can often be assumed to disrupt gene function by leading to complete absence of the gene product by lack of transcription or nonsense-mediated decay of an altered transcript.<sup>[13]</sup> Therefore, the c.1502del mutation may cause dysfunction of the ATP-binding cassette transporters. This mutation was coincident with a rapid, devastating course of disease with fatal outcome. Detection may facilitate genetic counseling and potentially aid prenatal diagnosis of the disease.

#### Author contributions

**Conceptualization:** Jing Wang, Hongqian Liu.

**Data curation:** Jing Wang.

**Funding acquisition:** Hongqian Liu.

**Investigation:** Qian Zhu.

**Resources:** Qian Zhu.

**Writing – original draft:** Jing Wang.

**Writing – review & editing:** Hongqian Liu.

#### References

- [1] Bezman L, Moser AB, Raymond GV, et al. Adrenoleukodystrophy: incidence, new mutation rate, and results of extended family screening. *Ann Neurol* 2001;49:512–7.
- [2] Moser HW, Moser AB, Smith KD, et al. Adrenoleukodystrophy: phenotypic variability and implications for therapy. *J Inher Metab Dis* 1992;15:645–64.
- [3] Kemp S, Berger J, Aubourg P. X-linked adrenoleukodystrophy: clinical, metabolic, genetic and pathophysiological aspects. *Biochim Biophys Acta* 2012;1822:1465–674.
- [4] Casey BM, McIntire DD, Leveno KJ. The continuing value of the Apgar score for the assessment of newborn infants. *N Engl J Med* 2001;346:7–11.
- [5] Moser HW, Loes DJ, Melhem ER, et al. X-Linked adrenoleukodystrophy: overview and prognosis as a function of age and brain magnetic resonance imaging abnormality. A study involving 372 patients. *Neuropediatrics* 2000;31:227–39.
- [6] Boehm CD, Cutting GR, Lachtermacher MB, et al. Accurate DNA-based diagnostic and carrier testing for X-linked adrenoleukodystrophy. *Mol Genet Metab* 1999;66:128–36.
- [7] Mosser J, Douar AM, Sarde CO, et al. Putative X-linked adrenoleukodystrophy gene shares unexpected homology with ABC transporters. *Nature* 1993;361:726–30.
- [8] Singh I, Moser HW, Moser AB, et al. Adrenoleukodystrophy: impaired oxidation of long chain fatty acids in cultured skin fibroblasts and adrenal cortex. *Biochem Biophys Res Commun* 1981;102:1223–9.
- [9] Moser HW. Adrenoleukodystrophy: phenotype, genetics, pathogenesis and therapy. *Brain* 1997;120:1485–508.
- [10] Moser HW, Mahmood A, Raymond GV. X-linked adrenoleukodystrophy. *Nat Clin Pract Neurol* 2007;3:140–51.
- [11] Kallabi F, Ellouz E, Tabebi M, et al. Phenotypic variability in a Tunisian family with X-linked adrenoleukodystrophy caused by the p.Gln316Pro novel mutation. *Clin Chim Acta* 2016;453:141–6.
- [12] Mehrpour M, Gohari F, Dizaji MZ, et al. An ABCD1 mutation (c.253dupC) caused diverse phenotypes of adrenoleukodystrophy in an Iranian consanguineous pedigree. *J Mol Genet Med* 2016;10:222.
- [13] Richards S, Aziz N, Bale S, et al. Standards and guidelines for the interpretation of sequence variants: a joint consensus recommendation of the American College of Medical Genetics and Genomics and the Association for Molecular Pathology. *Genet Med* 2015;17:405–24.