




Since January 2020 Elsevier has created a COVID-19 resource centre with free information in English and Mandarin on the novel coronavirus COVID-19. The COVID-19 resource centre is hosted on Elsevier Connect, the company's public news and information website.

Elsevier hereby grants permission to make all its COVID-19-related research that is available on the COVID-19 resource centre - including this research content - immediately available in PubMed Central and other publicly funded repositories, such as the WHO COVID database with rights for unrestricted research re-use and analyses in any form or by any means with acknowledgement of the original source. These permissions are granted for free by Elsevier for as long as the COVID-19 resource centre remains active.



Going viral: A brief history of Chilblain-like skin lesions (“COVID toes”) amidst the COVID-19 pandemic

Paul R. Massey, MD^a, Krystal M. Jones, MD^{b,*}

^a Department of Dermatology, Brigham and Women's Hospital, Harvard Medical School, Boston, MA

^b Dermatology Program, Boston Children's Hospital, Harvard Medical School, Boston, MA

ARTICLE INFO

Article history:

Received 18 May 2020

Accepted 18 May 2020

Keywords:

COVID-19

Chilblains

Chilblain-like lesions

Pernio

Cutaneous manifestations

ABSTRACT

Severe acute respiratory syndrome coronavirus 2 (SARS-CoV-2), the cause of the COVID-19 global pandemic, is notable for an expanding list of atypical manifestations including but not limited to coagulopathies, renal dysfunction, cardiac injury and a multisystem inflammatory syndrome in children. In addition, SARS-CoV-2 has been purportedly linked to multiple cutaneous manifestations, among them chilblain-like skin lesions, also known as “COVID toes.” Driven in large part by social media, dermatologists around the world reported a dramatic increase in the frequency of chilblain-like diagnoses early in the COVID-19 pandemic, often in members of the same family. This phenomenon has been captured in a rapidly expanding medical literature. As of this writing, the chilblain-like presentation has been reported to occur predominantly in younger, minimally symptomatic patients and to emerge late in the COVID-19 disease course. Evidence of SARS-CoV-2 infection is not consistently found when these patients are evaluated by polymerase chain reaction. A robust antiviral immune response in young patients that induces microangiopathic changes has been posited as a mechanism. Herein we review the rapid evolution of the literature regarding chilblain-like skin lesions early in the COVID-19 global pandemic.

© 2020 Elsevier Inc. All rights reserved.

Severe acute respiratory syndrome coronavirus 2 (SARS-CoV-2), the cause of the respiratory illness COVID-19, has led to a global pandemic. COVID-19 is the focus of a nascent and rapidly evolving medical literature. Amidst a panoply of unusual findings for a viral respiratory illness including induced coagulopathies [1], renal dysfunction [2], and cardiac arrests [3,4], a purported cutaneous manifestation of COVID-19, chilblain-like skin lesions – “COVID toes” – has garnered particular attention both in the medical literature and in the national media [5–14].

While COVID-19 was initially reported to have few or no cutaneous findings [15], a multitude of skin manifestations have now been described. Reported cutaneous manifestations of COVID-19 range from those commonly observed with viral illnesses, for example, maculopapular and urticarial eruptions [7,16], to the more unusual, for example, varicella-like eruptions [7] or livedoid and necrotic skin lesions [5,7]. These findings merit further study to parse true viral associations from those of potential confounders including acute or latent coinfections, medical complications of disease, and adverse reactions to medication.

* Corresponding author. Dermatology Program, Boston Children's Hospital, Harvard Medical School, 300 Longwood Ave, Boston, MA 02115. Tel.: 517-355-6117.

E-mail address: krystal.jones@childrens.harvard.edu (K.M. Jones).

The chilblain-like presentation is an unexpected association with COVID-19. Historically chilblains, or pernio, has been defined as an exaggerated skin response to cold in predisposed individuals [17]. It is characterized clinically by pink to violaceous papules arising on acral surfaces, most commonly the hands and feet (Figs. 1 and 2). Histologically, chilblains is an inflammatory disorder showing dermal edema along with a superficial and deep perivascular lymphocytic infiltrate. Chilblains may be idiopathic or associated with systemic disease, such as autoimmune conditions, certain genetic mutations, hematologic malignancy and less commonly infections, such as Epstein-Barr virus (EBV) [17]. Cold agglutinins appear to play a role in chilblains associated with EBV [17]. Chilblains is a relatively rare condition; a Minnesota case series recorded an average of 9–10 diagnoses per year across an entire tertiary academic department [17] (Fig. 3).

In early March 2020, nearly 3 weeks after community spread of COVID-19 was documented in Italy, a 13-year-old boy developed pruritic red-violet lesions on the toes in the setting of fever, myalgia, and headache [11]. Family members were reported to have had fever, cough, and dyspnea 6 days prior. While testing for COVID-19 was not possible in this case, an association was suspected. Shortly after this index report, images of similar acral lesions in the feet of children with suspected COVID-19 were circulated on “Amici DermPed,” an Italian pediatric dermatology forum [11]. In

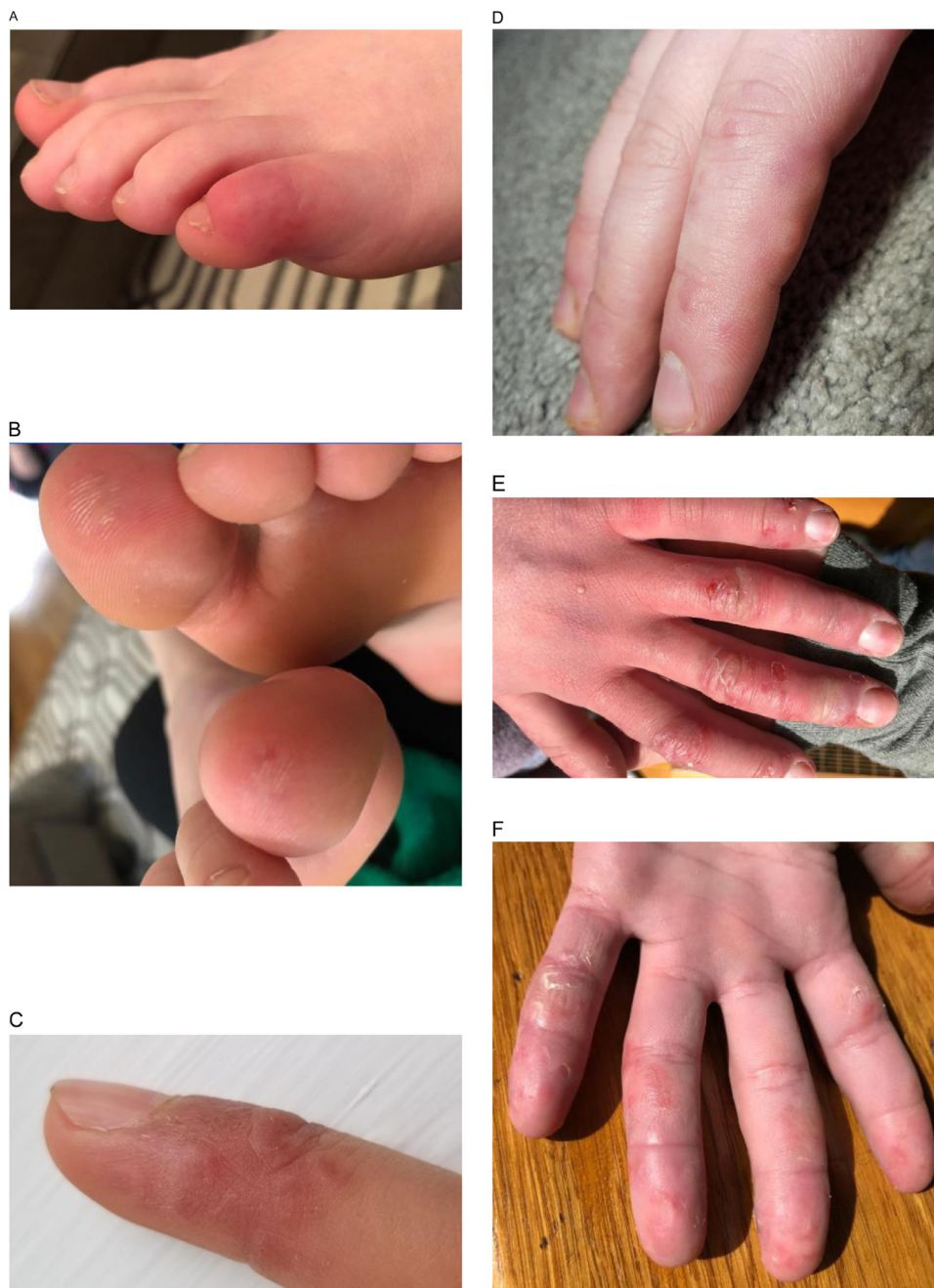


Fig. 1. New-onset chilblain-like lesions diagnosed in May 2020 in Boston, Massachusetts. Red-purple edematous plaque on the 5th (A) and 1st (B) digits of a 15-year-old with no preceding respiratory symptoms. Patient's mother had similar findings. PCR testing for SARS-CoV-2 was negative. Red-brown edematous papules on the distal fingers (C), (D) of an otherwise asymptomatic 16-year-old. PCR testing was not obtained. Red-purple superficially desquamating patches on the dorsal (E) and plantar (F) digits with significant digital edema of an otherwise healthy and asymptomatic 19 year old. Photos courtesy of Marilyn Liang, MD and Kristen Corey, MD. (Color version of figure is available online.)

mid-March, the French Union of Dermatologists and Venereologists created a text messaging group on WhatsApp to share information [6]. One week later, a case of chilblain-like lesions was reported via WhatsApp and with the help of “re-posts” through Facebook between the 2 platforms, 146 individual chilblain-like cases were subsequently circulated [6]. Intensified medical and lay interest in this phenomenon was reflected in unprecedented Google searches for “coronavirus toes.” [18] In the second week in April, just 1 month after the initial report of chilblain-like lesions in Italy, the American Academy of Dermatology, the Pediatric Dermatology Research Alliance, and the Spanish General Council of Podiatrists announced registries that would facilitate the study

of chilblain-like lesions and COVID-19 [10,19,20]. This month-long evolution from first informal reports to national specialty-level registry formation is striking. A detailed timeline is presented in Fig. 2.

Dermatologists in the United States and around the world now report a dramatically increased frequency of chilblain-like diagnoses, not infrequently in members of the same family, amidst the COVID-19 pandemic. The increased incidence [6], coupled with the temporal association with viral symptoms, has led to the colloquialization “COVID toes.” Chilblain-like lesions appear to have a predilection for younger patients who are often minimally or asymptomatic and do not require hospitalization [10,21]. Le-

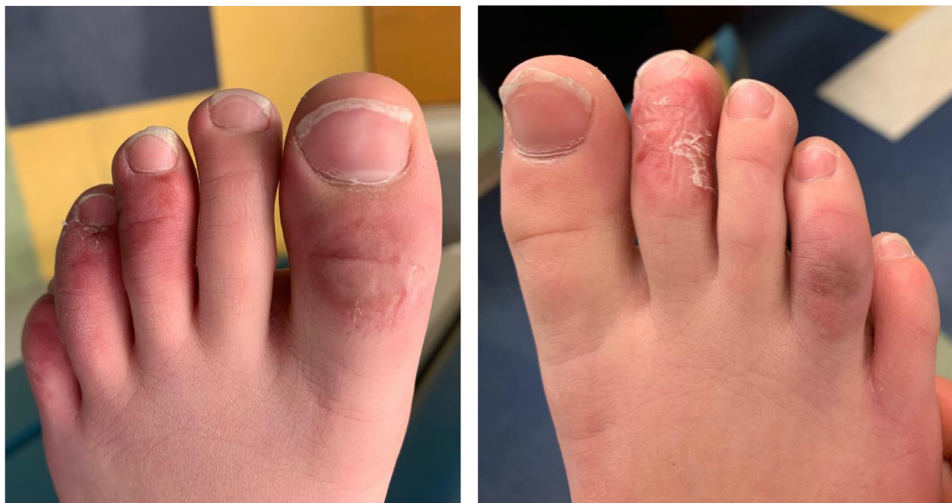

Fig. 2. Idiopathic chilblains. Targetoid red-purple patches on distal toes with superficial desquamation seen in a 12-year-old healthy male following cold exposure in Boston, Massachusetts in 2019, prior to onset of COVID-19 pandemic. Photos courtesy of Sadaf Hussain, MD. Fig. 2. (Color version of figure is available online.)

Table 1

Early reports of chilblain-like lesions amidst the COVID-19 pandemic.

e-Pub Date	First Author	Country	Patients in series (n)	Patients formally assessed for active infection (n)	COVID-19 Confirmed (n)
N/A	Mazzota [11]	Italy	1	-	-
4/18/20	Alramthan [25]	Kuwait	2	2	2
4/18/20	Kolivras [26]	Belgium	1	1	1
4/21/20	Hedou [24]	France	3	-	-
4/22/20	Romaní [23]	Spain	12	12	0
4/24/20	Piccolo [10]	Italy	63	11	2
4/24/20	Recalcati [21]	Italy	14	5	0
4/24/20	Fernandez-Nieto [27]	Spain	132	11	2
4/25/20	Landa [9]	Spain	6	3	2
4/25/20	Duong [5,6]	France	146	-	-
4/28/20	Bouaziz [5]	France	42	8	2
4/29/20	Galvan Casas [7]	Spain	71	71	29
5/6/20	Lopez-Robles [8]	Spain	41	19	0
5/7/20	Colonna [22]	Italy	4	4	0
5/9/20	Andina [28]	Italy	22	19	1
5/12/20	Cordero [29]	USA	6	6	0
Totals			566	172	41

The initial report by Mazzota is not formally published as of this writing. Most assessments for active COVID-19 infection were by PCR.

sions appear late in the evolution of COVID-19 symptoms, often during convalescence. Finally, although a history of upper respiratory tract infection in patients and family members is sometimes elicited [722], evidence of infection is not consistently or regularly found when evaluated by polymerase chain reaction (PCR) for SARS-CoV-2.

In one of the first studies on the topic, Piccolo et al reported 63 cases of chilblain-like lesions during the Italian COVID-19 outbreak; PCR data was available for 11 patients, and only 2 (18%) were positive [10]. Recalcati et al reported no positive cases in a separate Italian series of 14 patients [21]. In a Spanish series of 12 cases with available PCR data, again no patients were found to be positive [23]. The strongest correlation between COVID-19 and chilblain-like lesions is provided by a Spanish study in which 71 cases were reported, 41% with confirmed COVID-19 [7]. At the time of this writing in early May 2020, 17 reports have detailed a pooled 566 patients with new-onset chilblain-like lesions suspected to be related to COVID-19 (Table 1)[5–11,21–29]; formal investigation for active infection, usually by PCR, was undertaken in 172 instances. Among these patients, SARS-CoV-2 was detected in 41 (29 reported by a single study), yielding an overall confirmed infection rate of 23.8%.

This is a strikingly low rate of testing positivity for a viral-associated phenomenon, especially as SARS-CoV-2 can shed for up to 37 days in some patients [30]; at the same time, 23.8% is also above expected background rates of active COVID-19 infection in study locations. Possible explanations for the discrepancy include insufficiently sensitive diagnostic testing, delayed onset of symptoms after clearance of infection, enhanced viral clearance in patients with chilblain-like skin lesions or admixed diagnoses of non-COVID-19 related chilblains due to confounding factors which include unseasonably cold weather in North America and Europe in Spring 2020 [31], heightened self-detection in the context of COVID-19-associated media attention and population behavioral changes during stay-at-home orders.

A mechanistic explanation for the low rate of testing positivity was put forth by Kolivras et al, who hypothesized that a robust antiviral type I interferon response in young patients may truncate the clinical course and induce microangiopathic changes leading to chilblain-like skinlesions [26]. According to this hypothesis, patients present with chilblain-like lesions only after mounting a successful viral response; thus, lesions are detected when symptoms are likely to be subsiding. While more studies are needed to validate this hypothesis, it is consistent with the findings pre-

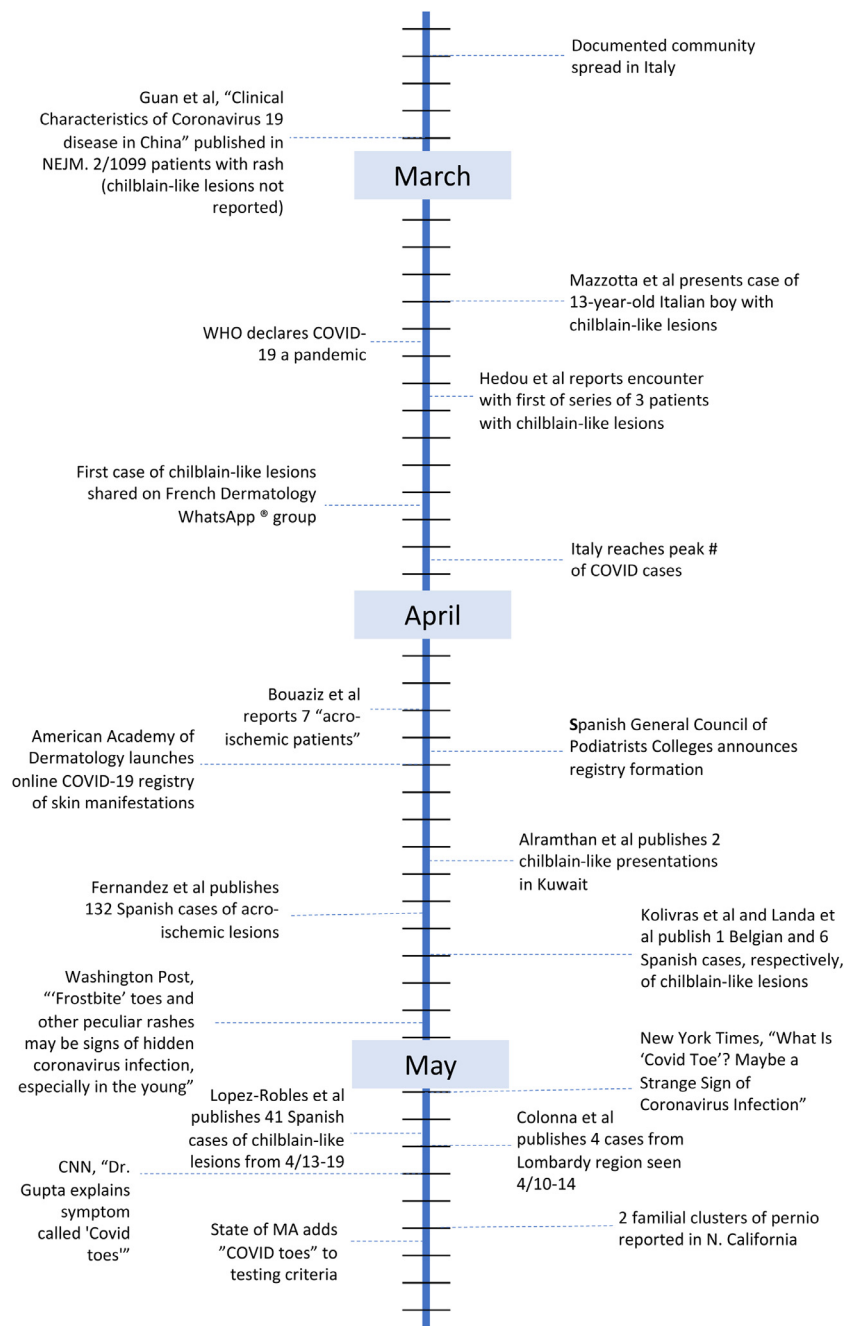


Fig. 3. Early chronology of chilblain-like lesions in the setting of the COVID-19 pandemic.

sented by Galván-casas et al which showed chilblain-like lesions are unique amongst the cutaneous manifestations of COVID-19 in occurring primarily late in the disease course [7]. Regarding its possible association with a robust immune response, emerging data on the occurrence of a pediatric Kawasaki-like syndrome, termed Multisystem Inflammatory Syndrome in Children (MIS-C) by the US Centers for Disease Control and Prevention, amongst children with suspected or confirmed COVID-19 infection suggest that immune complications may eventually be recognized in a larger fraction of those infected [13,32].

Rigorous studies with improved diagnostic testing, including validated antibody-based assays, measurement of COVID-19 viremia and tissue biopsies with lesional PCR or immunohistochemistry are needed to fully elucidate the relationship between

chilblain-like lesions and COVID-19. These data may have significant implications for clinicians, patients and public health officials, including the potential for transmissibility and the need for self-isolation. The impact of the latter may be somewhat limited if these lesions occur in the period of convalescence.

The study of chilblain-like lesions, as in many domains of the global COVID-19 pandemic, is intense and ongoing. The usually deliberate scientific process has moved apace, from the first documented case of chilblain-like lesions in March 2020 to the formation of national registries a mere month later. These undertakings may eventually explain current knowledge gaps, including strikingly low rates of testing positivity and a pauci-symptomatic presentation in many patients.

Funding sources

This research did not receive any specific grant from funding agencies in the public, commercial, or not-for-profit sectors.

Declaration of Competing Interests

None to disclose.

CRediT authorship contribution statement

Paul R. Massey: Conceptualization, Writing - original draft, Writing - review & editing, Formal analysis. **Krystal M. Jones:** Conceptualization, Writing - original draft, Writing - review & editing, Visualization.

References

- [1] Bikdeli B, Madhavan MV, Jimenez D, et al. COVID-19 and thrombotic or thromboembolic Disease: implications for prevention, antithrombotic therapy, and follow-up. *J Am Coll Cardiol* 2020.
- [2] Batlle D, Soler MJ, Sparks MA, et al. Acute kidney injury in COVID-19: emerging evidence of a distinct pathophysiology. *J Am Soc Nephrol* 2020.
- [3] Zheng Y-Y, Ma Y-T, Zhang J-Y, Xie X. COVID-19 and the cardiovascular system. *Nat Rev Cardiol* 2020;17(5):259–60.
- [4] Guo T, Fan Y, et al., Department of Cardiology ZHoWU, Wuhan, China Cardiovascular implications of fatal outcomes of patients with coronavirus disease 2019 (COVID-19). *JAMA Cardiology* 2020.
- [5] Bouaziz JD, Duong T, Jachiet M, et al. Vascular skin symptoms in COVID-19: A French observational study. *J Eur Acad Dermatol Venereol* 2020.
- [6] Duong TA, Velter C, Rybojad M, et al. Did Whatsapp(R) reveal a new cutaneous COVID-19 manifestation. *J Eur Acad Dermatol Venereol* 2020.
- [7] Galvan Casas C, Catala A, Carretero Hernandez G, et al. Classification of the cutaneous manifestations of COVID-19: a rapid prospective nationwide consensus study in Spain with 375 cases. *Br J Dermatol* 2020.
- [8] Lopez-Robles J, de la Hera I, Pardo J, Martinez J, Cutillas-Marco E. Chilblain-like lesions: a case series of 41 patients during the COVID-19 pandemic. *Clin Exp Dermatol* 2020.
- [9] Landa N, Mendieta-Eckert M, Fonda-Pascual P, Aguirre T. Chilblain-like lesions on feet and hands during the COVID-19 Pandemic. *Int J Dermatol* 2020.
- [10] Piccolo V, Neri I, Filippeschi C, et al. Chilblain-like lesions during COVID-19 epidemic: a preliminary study on 63 patients. *J Eur Acad Dermatol Venereol* 2020.
- [11] Mazzota F, Troccoli T. Acute acro-ischemia in the child at the time of COVID-19 (Monday's case). Accessed May 5, 2020.
- [12] Rabin RC. What Is 'Covid Toe'? Maybe a Strange Sign of Coronavirus Infection. *The New York Times* 2020.
- [13] Ariana EC, Janes C. Children are falling ill with perplexing inflammatory syndrome thought to be linked to covid-19. *Washington Post* 2020.
- [14] Cha AE. 'Frostbite' toes and other peculiar rashes may be signs of hidden coronavirus infection, especially in the young. *Washington Post* 2020.
- [15] W-j Guan, Z-y Ni, Hu Y, et al. Clinical characteristics of coronavirus disease 2019 in China. *N Engl J Med* 2020(19):1860–1.
- [16] Recalcati S. Cutaneous manifestations in COVID-19: A first perspective. *J Eur Acad Dermatol Venereol* 2020.
- [17] Cappel JA, Wetter DA. Clinical characteristics, etiologic associations, laboratory findings, treatment, and proposal of diagnostic criteria of pernio (chilblains) in a series of 104 patients at Mayo Clinic, 2000 to 2011. *Mayo Clin Proc* 2014;89(2):207–15.
- [18] Kluger N, Scrivener Y. The use of Google trends for acral symptoms during COVID-19 outbreak in France. *J Eur Acad Dermatol Venereol* 2020.
- [19] American Academy of Dermatology COVID-19 Dermatology Registry; 2020 <https://www.aad.org/member/practice/coronavirus/registry> Published 2020. Accessed May 5th.
- [20] Association PDR. COVID Acral Ischemia/Perniosis in children. <https://pedraresearch.org/2020/04/20/covid-acral-ischemia-perniosis-in-children/>. Published 2020. Accessed May 5th 2020.
- [21] Recalcati S, Barbagallo T, Frasin LA, et al. Acral cutaneous lesions in the time of COVID-19. *J Eur Acad Dermatol Venereol* 2020.
- [22] Colonna C, Monzani NA, Rocchi A, Gianotti R, Boggio F, Gelmetti C. Chilblains-like lesions in children following suspected Covid-19 infection. *Pediatr Dermatol* 2020.
- [23] Romani J, Baselga E, Mitjà O, et al. Lesiones pernióticas y acrales en España durante el confinamiento por COVID: análisis retrospectivo de 12 casos. In: *Actas Dermosifiliogr*.
- [24] Hedou M, Carsuzaa F, Chary E, Hainaut E, Cazenave-Roblot F, Masson Regnault M. Comment on "Cutaneous manifestations in COVID-19: a first perspective" by Recalcati S. *J Eur Acad Dermatol Venereol* 2020.
- [25] Alramthan A, Aldaraji W. A case of COVID-19 presenting in clinical picture resembling chilblains disease. First report from the Middle East. *Clin Exp Dermatol* 2020.
- [26] Kolivras A, Dehavay F, Delplace D, et al. Coronavirus (COVID-19) infection-induced chilblains: A case report with histopathologic findings. *JAAD Case Rep* 2020.
- [27] Fernandez-Nieto D, Jimenez-Cauhe J, Suarez-Valle A, et al. Characterization of acute acro-ischemic lesions in non-hospitalized patients: a case series of 132 patients during the COVID-19 outbreak. *J Am Acad Dermatol* 2020.
- [28] Andina D, Noguera-Morel L, Bascuas-Arribas M, et al. Chilblains in children in the setting of COVID-19 pandemic. *Pediatr Dermatol* 2020.
- [29] Cordero KM, Reynolds SD, Wattier R, McCalmont TH. Clustered cases of acral perniosis: clinical features, histopathology and relationship to COVID-19. *Pediatr Dermatol* 2020.
- [30] Wolfel R, Corman VM, Guggemos W, et al. Virological assessment of hospitalized patients with COVID-2019. *Nature* 2020.
- [31] Rosenbach M. Published 2020. <https://www.aad.org/dw/dw-insights-and-inquiries/2020-archive/april/dermatological-manifestations-covid-19-part-4> Accessed May 5th, 2020.
- [32] Jones VG, Mills M, Suarez D, et al. COVID-19 and Kawasaki disease: novel virus and novel case. *Hosp Pediatr* 2020.