

Available online at www.sciencedirect.com

ScienceDirect

journal homepage: <http://Elsevier.com/locate/radcr>

Interventional Radiology

Use of a mechanical thrombectomy device to treat early hepatic artery thrombosis after orthotopic liver transplant

James C. Meek DO^{a,*}, Jonathan S. McDougal MD^b, Daniel Borja-Cacho MD^c, Mary E. Meek MD^a^a Department of Radiology, College of Medicine, University of Arkansas for Medical Sciences, 4301 W. Markham, Slot 556, Little Rock, AR 72205, USA^b College of Medicine, University of Arkansas for Medical Sciences, Little Rock, AR, USA^c Department of Surgery, College of Medicine, University of Arkansas for Medical Sciences, Little Rock, AR, USA

ARTICLE INFO

Article history:

Received 2 December 2017

Accepted 11 December 2017

Available online 28 December 2017

Keywords:

Hepatic

Liver

Revascularization

Stent

Thrombosis

Transplantation

ABSTRACT

Hepatic artery thrombosis (HAT) is a major cause of morbidity and mortality after orthotopic liver transplantation, occurring in 5% of cases (Piardi et al, 2016). HAT is the second main cause of graft loss after primary nonfunction, the leading cause of graft failure in the immediate postoperative period (<1 month), and is associated with a mortality rate of up to 60% without intervention (Piardi et al, 2016; Pareja et al., 2010; Crossin et al., 2003). Although retransplantation is the preferred therapy, the limited availability of donor organs can necessitate urgent, alternative treatment. These patients present physicians with an often-severe clinical picture, which requires consideration of endovascular approaches as opposed to the more traditional, invasive surgical interventions. The following case study presents a novel mechanical therapy that uses an endovascular approach for revascularization—a stent retriever device.

© 2017 the Authors. Published by Elsevier Inc. under copyright license from the University of Washington. This is an open access article under the CC BY-NC-ND license (<http://creativecommons.org/licenses/by-nc-nd/4.0/>).

Introduction

Orthotopic liver transplantation (OLT) coincides with the loss of native collaterals and the hepatic artery becomes the primary blood supply to the liver and the sole blood supply to the biliary tree. Although liver parenchyma is partially supplied by the portal vein after OLT, the absence of hepatic arterial flow can lead to acute hepatic necrosis and biliary complications. The

clinical presentation of hepatic artery thrombosis (HAT) after OLT is often fulminant hepatic failure or bile duct necrosis that is complicated by gangrene and uncontrollable sepsis in the iatrogenically immunocompromised host. Ischemic damage to bile duct epithelium and hepatocytes can result in recurrent cholangitis, obstructions, the development of biliary and hepatic abscesses, and massive necrosis in the graft [1].

No single etiology of HAT, which occurs in up to 5% of OLT cases, has been described [2]. Surgical causes can include the

Acknowledgment: The authors would like to acknowledge Madison Hedrick, MA, for her work on this manuscript.

Competing Interests: The authors of this manuscript have no conflicts of interest to disclose as described by the journal.

* Corresponding author.

E-mail address: jcmeek@uams.edu (J.C. Meek).

<https://doi.org/10.1016/j.radcr.2017.12.007>

1930-0433/© 2017 the Authors. Published by Elsevier Inc. under copyright license from the University of Washington. This is an open access article under the CC BY-NC-ND license (<http://creativecommons.org/licenses/by-nc-nd/4.0/>).

following, however: injuries during graft recovery (eg, intimal tears, dissection, and hematoma); anastomotic or anatomic issues with stenosis or kinking of the artery; and small or multiple arteries requiring arterial reconstruction. Nonsurgical factors contributing to HAT are generally those that present an increased risk of vessel thrombosis. Factors cited in the literature include preexisting procoagulant states caused by genetic, iatrogenic, or other factors, such as the following: factor V Leiden deficiency, administration of tranexamic acid or aminocaproic acid, perioperative transfusion of large amounts of FFP, or elevated postoperative hematocrit [3].

Some conditions that predispose one to liver dysfunction or arise from it can also increase the risk of thrombosis and subsequent HAT; these include sclerosing cholangitis, HIV infection, and massive ascites [1].

The currently available therapeutic options for HAT are few and each has its own potential limitations; these include retransplanting the graft, attempting to revascularize it (by a surgical or endovascular approach), or salvaging it. Hepatic artery thrombosis is the second leading cause of graft loss after primary nonfunction, and is the leading cause of graft failure in the immediate postoperative period (<1 month). Furthermore, HAT is associated with a mortality rate of up to 60% without intervention [2,4,5]. Although retransplantation is historically the treatment of choice, this approach is limited to the availability of donors. Whether graft salvage through surgical means is an appropriate option is dependent on a patient's clinical status and their ability to tolerate laparotomy. Intra-arterial infusion of thrombolytics is theoretically a targeted, less-invasive therapy; however, it still carries an increased risk of bleeding that must be carefully considered, especially in the postoperative patient immediately after transplant. Endovascular mechanical thrombectomy (EMT), however, requires neither an open abdominal operation nor the use of thrombolytic agents. Therefore, as described in our case study, EMT can provide an alternative approach that mitigates the concerns of other available therapies, as there is no need for donor availability and the patient's ability to tolerate treatment is not a major cause of concern.

EMT with stent retrievers is a relatively new and rapidly growing approach to intravascular thrombolysis. Initially developed for use in patients with acute ischemic stroke, 3 broad device classes have been approved for use in the United States by the Food and Drug Administration: coil retrievers in 2004, aspiration devices in 2008, and stent retrievers in 2012. Stent retrievers are self-expanding, wire stents that are deployed in the occluded vessel within the thrombus, snaring it within the stent. At this point, the stent and the entangled thrombus can be withdrawn back into the delivery catheter and the artery is recanalized.

Case report

The patient consented via phone interview to be included in the publication of this manuscript. The case presented in this study involved a 54-year-old male patient with a history of hepatitis C and alcohol abuse. His liver disease had progressed to decompensated cirrhosis and massive cirrhotic ascites were present; therefore, the patient underwent OLT.

On postoperative day 1, the patient returned to the operating room for evacuation of an intra-abdominal hematoma. At the time of the hematoma evacuation, Doppler interrogation of the hepatic artery showed the artery to be patent. Ultrasound showed the hepatic artery to be patent, with a normal waveform and a patent portal vein. On postoperative day 2, a repeat ultrasound was performed and showed parvus tardus waveform, but this was reported as normal. For the first week postoperation (day 1 to day 6), his bilirubin stayed elevated and above 4.8 mg/dL and his transaminases and alkaline phosphatase remained elevated as well. These findings prompted an additional abdominal ultrasound, during which clinicians were unable to visualize flow in the hepatic artery.

On postoperative day 7, the possibility of transplant HAT was raised and interventional radiology was consulted. We performed a computed tomography scan of the abdomen and pelvis with contrast and found HAT. At that point, the team decided to attempt endovascular hepatic artery thrombectomy. Given the patient's recent OLT surgery and his subsequent operation for hematoma evacuation, prolonged lytic infusion was considered suboptimal.

We obtained right common femoral artery access and a 7Fr 55-cm Ansel 1 guide sheath (Cook Medical, Bloomington, IN) was placed into the distal abdominal aorta. We used a 5Fr 80-cm Cobra catheter (Cook Medical, Bloomington, IN) to select the common hepatic artery and performed an arteriogram that showed the transplant artery was occluded just beyond the gastroduodenal artery (Fig. 1).

We advanced a 2.8Fr 130-cm Progreat microcatheter (Terumo, Somerset, NJ) into the right hepatic artery, and contrast injection showed flow within the distal branches (Fig. 2).

We placed a 4 mm × 40 mm Solitaire thrombectomy device (ev3, Irvine, CA) into the right hepatic artery and allowed it to dwell for 5 minutes. We then withdrew the device while placing continuous suction onto the guide sheath (Fig. 3).

Follow-up injection showed improved flow. We then repeated the maneuver in the left hepatic artery, and again there was an improvement in flow. However, the more proximal portion of the proper hepatic artery continued to have flow-limiting, nonocclusive thrombus within it (Fig. 4).

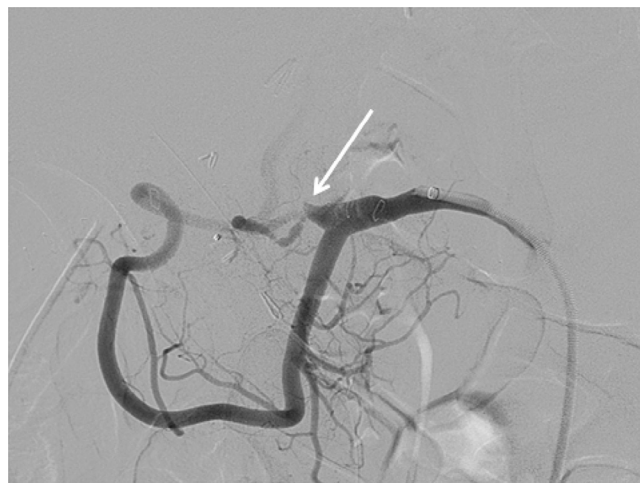

Fig. 1 – Abrupt thrombosis of the proper hepatic artery (arrow).

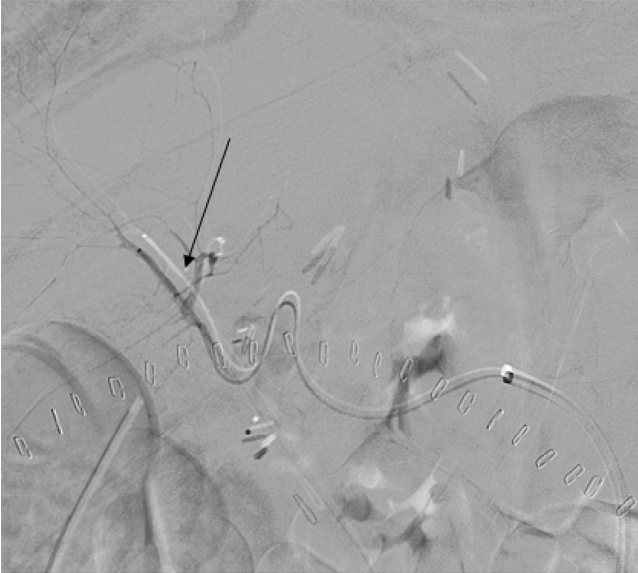


Fig. 2 – After advancement of a 2.8Fr Progreat microcatheter into the distal branches of the right hepatic artery (arrow), contrast injection shows the intrahepatic branches to be patent.

Next, we used a 2.8Fr 150-cm Marksman microcatheter (ev3, Irvine, CA) to deliver a 6 mm × 30 mm Solitaire thrombectomy device (ev3) to the proper hepatic artery. This did not successfully clear the residual thrombus. Thus, we deployed a 7 mm × 2.5 cm Viabahn stent graft (Gore, Flagstaff, AZ) in proper hepatic artery. Follow-up injection showed flow through the stent graft and flow in all the intrahepatic branches.

We performed a repeat angiogram the next morning, and it showed patency of the intrahepatic branches and the stent graft (Fig. 5). We performed Doppler ultrasound approximately 12 hours later, and it showed a patent stent and patent hepatic artery. Over the next 4 days, the bilirubin decreased from 4.8 to 2.3 mg/dL. The transaminases normalized, but the

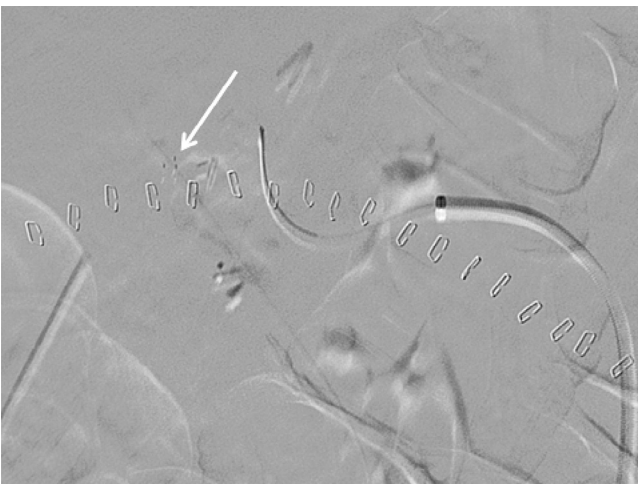

Fig. 3 – The distal marks show the 4 mm × 40 cm Solitaire stent retriever to be deployed in the right hepatic artery (arrow).

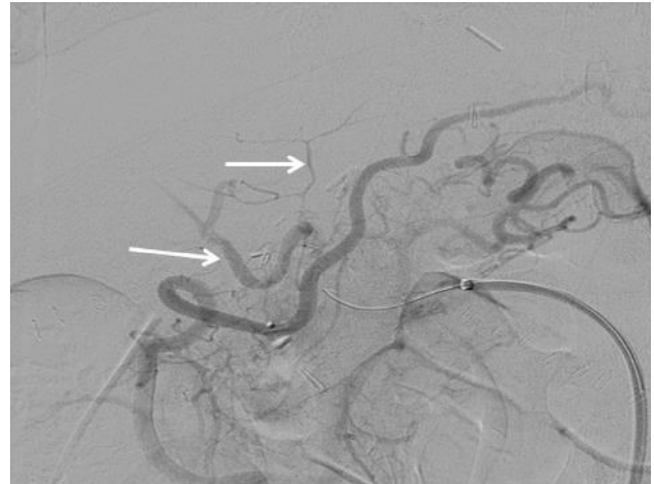


Fig. 4 – After 2 passes, improved blood flow is seen in the right and left hepatic arteries (arrows).

alkaline phosphatase continued to increase. The continued elevation of the alkaline phosphatase prompted further investigation with magnetic resonance imaging. The magnetic resonance imaging showed necrosis of the bile duct, which ultimately required retransplantation. At explant, the hepatic artery was patent.

Discussion

Strict distinctions between early and late hepatic thrombosis are unclear. Definitions of early hepatic thrombosis (eHAT) ranged from 14 to 100 days, depending on the author. For practical purposes, eHAT can be defined as an occlusion that occurs within 1 month after OLT, although generally occurring within the first 10 days after transplantation [6]. Late HAT (lHAT) is less prevalent (<2% of cases) and is generally milder with less of an impact on graft and patient survival rates. Complications in lHAT are ameliorated by the development of new collaterals and are often limited to biliary stricture and

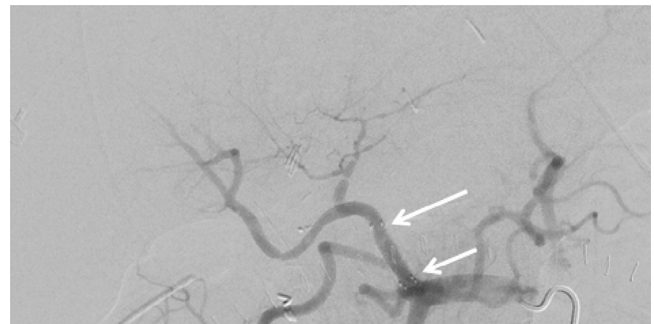


Fig. 5 – Follow-up angiogram 24 hours later shows a patent proper hepatic artery and intrahepatic branches. The 5 mm × 25 mm Viabahn stent graft (arrows) is seen at the location where the residual thrombus could not be removed.

dysfunction. These collaterals can be identified via angiography as early as 2 weeks after transplantation [7].

The incidence of eHAT is more than double that of IHAT (>4% of cases), and it is undoubtedly the more severe presentation. Overall mortality in this group is 33.3% [6]. Bekker et al analyzed outcomes for the 3 currently accepted treatment modalities utilized for eHAT, which include the following: observation, retransplantation, and revascularization.

Observation of eHAT is an approach. Observation only represented 21.5% of cases when including those who received best supportive care without retransplantation and those on the waiting list for transplantation. The incidence of graft failure associated with eHAT is greater than 50% without further intervention, and the overall mortality rate in this group reaches 55% [6].

Retransplantation is generally considered ideal for most groups and is eventually the definitive treatment in up to half of all cases of eHAT (50% of adults and 62% of children). Retransplantation is also often necessary after an attempt at revascularization, occurring in approximately 30% of cases [6]. Retransplantation heralds its own risks, with patients having a sixfold increase of recurrent eHAT compared with primary transplantations, among other complications [6].

Revascularization procedures are attempted in approximately 75% of adult and 54% of pediatric cases, with an average success rate around 56%. It is important to detect eHAT while the patient is still asymptomatic because graft survival after revascularization is much better in this group (81.8%) vs 40% in symptomatic patients [6]. Early diagnosis via rigorous screening protocols (typically including Doppler ultrasound) increases the success of revascularization attempts. The success rate of a revascularization attempt was 66.1% when Doppler ultrasound was performed daily or more frequently vs 44.9% with less frequent screening [8]. Transaminases are another important marker of HAT and are elevated in 75% of patients [2].

Urgent surgical intervention (open thrombectomy or revision and reanastomosis of the hepatic artery) has been the traditional approach to revascularization in appropriate candidates. Given the severe clinical picture of many patients with eHAT, there is an increasingly recognized role for less invasive interventions in this population. In fact, endovascular therapies are being utilized more frequently; they have replaced surgery as the preferred initial therapy in most applicable cases [2].

The percutaneous endovascular approaches currently described in the literature include intra-arterial thrombolysis (IAT), percutaneous transluminal angioplasty (PTA), and stent placement. IAT is the default endovascular approach in otherwise uncomplicated HAT. There is no current protocol defining the best regimen (urokinase, streptokinase, or alteplase) for IAT, or the optimal method of administration. The initial success rate of IAT is shown to be 68%-80%, and the definitive treatment rate has been reported as high as 54.5% [9,10].

If there are underlying anatomic defects predisposing a patient to thrombosis (such as hepatic artery stenosis or kinking) or any factors precluding the use of lytic therapy, PTA or stenting is then considered [9]. PTA with or without stenting was attempted in 62% of patients after IAT [9]. IAT with PTA or stenting showed better patency and survival rates compared with IAT alone [2].

Endovascular interventions are not without their own complications, however. IAT carries a significant risk of hemorrhage (in 1 series, 20% of cases) [10]. Rebound thrombosis occurs one-third of the time. The complications of PTA with subsequent stent placement include thrombosis, vascular dissection, and rupture [2]. Angioplasty may result in hepatic artery bleeding in up to 5% of cases [9].

Multiple systematic reviews of stent retriever devices have shown their increased efficacy without a decrease in safety in the initial, intended use—acute ischemic stroke. This was demonstrated by reduced disability at 90 days in patients undergoing thrombectomy plus the standard therapy, IV recombinant tissue plasminogen activator compared with control groups who received IV recombinant tissue plasminogen activator alone. Thrombectomy was also not associated with any greater mortality rates or an increased risk of hemorrhage [11–13]. These outcomes were still demonstrated even when limiting analysis to those cases where a Solitaire device (ev3) was the only type of stent retriever used [14]. Four randomized clinical trials were terminated early because of the clear advantage of using stent retriever therapy [11].

We performed a literature review using PubMed and ProQuest and discovered only a single case of mechanical thrombectomy utilized for treatment of HAT after OLT. An 8Fr Straub Rotarex rotational thrombectomy device (Switzerland) was successfully used to recanalize a thrombosed hepatic artery graft. This IHAT case is subacute, as treatment was performed 6-month postoperative.

The often-severe clinical picture and early postoperative status of many eHAT patients can be constraining factors when considering therapies. Donor graft availability and the period required for retransplantation often necessitate urgent attempts at revascularization; however, patient condition can greatly increase the risks associated with open surgery or administration of thrombolytics, even when given intra-arterially. Stent retriever devices may show similar benefits in other instances of thrombosis, as they do in acute stroke. Thus, there is a potential role for these endovascular mechanical interventions in HAT. As such, we recommend that mechanical interventional procedures be given careful consideration in these patients, and that further research be performed to examine such cases.

REFERENCES

- [1] Heaton ND. Hepatic artery thrombosis: conservative management or retransplantation? *Liver Transpl* 2013;19(S2):S14–6.
- [2] Piardi T, Lhuair M, Bruno O, Memeo R, Pessaux P, Kianmanesh R, et al. Vascular complications following liver transplantation: a literature review of advances in 2015. *World J Hepatol* 2016;8(1):36–57.
- [3] Bhattacharjya S, Gunson BK, Mirza DF, Mayer DA, Buckels JA, McMaster P, et al. Delayed hepatic artery thrombosis in adult orthotopic liver transplantation—a 12-year experience. *Transplantation* 2001;71(11):1592–6.
- [4] Pareja E, Cortes M, Navarro R, Sanjuan F, López R, Mir J. Vascular complications after orthotopic liver transplantation: hepatic artery thrombosis. *Transplant Proc* 2010;42(8):2970–2.

- [5] Crossin JD, Muradali D, Wilson SR. US of liver transplants: normal and abnormal. *Radiographics* 2003;23(5):1093–114.
- [6] Bekker J, Ploem S, de Jong K. Early hepatic artery thrombosis after liver transplantation: a systematic review of the incidence, outcome and risk factors. *Am J Transplant* 2009;9(4):746–57.
- [7] Gunsar F, Rolando N, Pastacaldi S, Patch D, Raimondo ML, Davidson B, et al. Late hepatic artery thrombosis after orthotopic liver transplantation. *Liver Transpl* 2003;9(6):605–11.
- [8] Frongillo F, Lirosi MC, Nure E, Inchingolo R, Bianco G, Silvestrini N, et al. Diagnosis and management of hepatic artery complications after liver transplantation. *Transplant Proc* 2015;47(7):2150–5.
- [9] Singhal A, Stokes K, Sebastian A, Wright HI, Kohli V. Endovascular treatment of hepatic artery thrombosis following liver transplantation. *Transplant Int* 2010;23(3):245–56.
- [10] Abdelaziz O, Hosny K, Amin A, Emadeldin S, Uemoto S, Mostafa M. Endovascular management of early hepatic artery thrombosis after living donor liver transplantation. *Transplant Int* 2012;25(8):847–56.
- [11] Touma L, Filion KB, Sterling LH, Atallah R, Windle SB, Eisenberg MJ. Stent retrievers for the treatment of acute ischemic stroke: a systematic review and meta-analysis of randomized clinical trials. *JAMA Neurol* 2016;73(3):275.
- [12] Rodrigues FB, Neves JB, Caldeira D, Ferro JM, Ferreira JJ, Costa J. Endovascular treatment versus medical care alone for ischaemic stroke: systematic review and meta-analysis. *BMJ* 2016;353:n/a.
- [13] Chen C, Ding D, Starke RM, Mehndiratta P, Crowley RW, Liu KC, et al. Endovascular vs medical management of acute ischemic stroke. *Neurology* 2015;85(22):1980–90.
- [14] Campbell BCV, Hill MD, Rubiera M, Menon BK, Demchuk A, Donnan GA, et al. Safety and efficacy of solitaire stent thrombectomy: individual patient data meta-analysis of randomized trials. *Stroke* 2016;47(3):798–806.