



# Effectiveness of Two-Year versus One-Year Use of Dual Antiplatelet Therapy in Reducing the Risk of Very Late Stent Thrombosis after Drug-Eluting Stent Implantation

Hamid Reza Poorhosseini, MD, Seyed Kianoosh Hosseini, MD, Tahereh Davarpassand, MD\*, Masoumeh Lotfi Tokaldany, MD, MPH, Mojtaba Salarifar, MD, Seyed Ebrahim Kassaian, MD, Mohammad Alidoosti, MD, Younes Nozari, MD, Ebrahim Nematipour, MD, Ali Mohammad Haji Zeinali, MD, Hasan Aghajani, MD, Ali Reza Amirzadegan, MD

Tehran Heart Center, Tehran University of Medical Sciences, Tehran, Iran.

Received 20 September 2011; Accepted 05 February 2012

## Abstract

**Background:** Impact of 12 months' versus 24 months' use of dual antiplatelet therapy on the prevalence of stent thrombosis in patients undergoing percutaneous coronary intervention (PCI) with the drug-eluting stent (DES) is not clear. As a result, duration of dual antiplatelet therapy is still under debate among interventionists.

**Methods:** From March 2007 until August 2008, all consecutive patients with successful PCI who received at least one DES and were treated with dual antiplatelet therapy (Clopidogrel + Aspirin) were included. All the patients were followed up for more than 24 months (mean = 35.27 ± 6.91 months) and surveyed for very late stent thrombosis and major cardiovascular events.

**Results:** From 961 patients eligible for the study, 399 (42%) discontinued Clopidogrel after 12 months and 562 (58%) continued Clopidogrel for 24 months. The clinical and procedural variables were compared between the two groups. In the 12 months' use group, two cases of definite thrombosis occurred at 18 and 13 months post PCI. In the 24 months' use group, 2 cases of definite thrombosis occurred at 14 and 28 months post PCI, one of them with stenting in a bifurcation lesion. Five cases of probable stent thrombosis were detected at 21, 28, 32, 33, and 34 months after the procedure. It is of note that amongst the 10 cases of stent thrombosis, only 1 (10%) thrombosis occurred when the patient was on Clopidogrel and Aspirin and all the other 9 (90%) cases of thrombosis appeared after the discontinuation of the dual antiplatelet therapy.

**Conclusion:** Extended use of dual antiplatelet therapy (for more than 12 months) was not significantly more effective than Aspirin monotherapy in reducing the risk of myocardial infarction or stent thrombosis, death from cardiac cause, and stroke.

*J Teh Univ Heart Ctr 2012;7(2):47-52*

**This paper should be cited as:** Poorhosseini HR, Hosseini SK, Davarpassand T, Lotfi Tokaldany M, Salarifar M, Kassaian SE, Alidoosti M, Nozari Y, Nematipour E, Haji Zeinali AM, Aghajani H, Amirzadegan AR. Effectiveness of Two-Year versus One-Year Use of Dual Antiplatelet Therapy in Reducing the Risk of Very Late Stent Thrombosis after Drug-Eluting Stent Implantation. *J Teh Univ Heart Ctr 2012;7(2):47-52.*

**Keywords:** Drug-eluting stents • Clopidogrel • Angioplasty • Thrombosis

\*Corresponding Author: Tahereh Davarpassand, Cardiology Department, Tehran Heart Center, North Kargar Street, Tehran, Iran. 1411713138. Tel: +98 21 88029256. Fax: +98 21 88029256. E-mail: dkhatereh@yahoo.com.

## Introduction

It has been demonstrated that the implantation of the drug-eluting stent (DES) reduces the angiographic restenosis and the need for repeat revascularization compared with the bare metal stent.<sup>1-6</sup> However, the use of the DES results in a prothrombotic environment, predisposing the patient to late stent thrombosis.<sup>7, 8</sup> Clopidogrel and Aspirin are the major antiplatelet drugs for the prevention of stent thrombosis. The risk of early thrombosis events amongst patients with the DES is remarkably reduced by dual antiplatelet therapy.<sup>9, 10</sup> According to the current guidelines, antiplatelet therapy is needed for at least 9 to 12 months after the implantation of the DES;<sup>11</sup> still, reports of late and very late stent thrombotic events have raised doubts about whether this regimen is sufficient.<sup>12, 13</sup> One recent report suggested that although a two-year dual antiplatelet regimen with Aspirin and Clopidogrel could prevent the occurrence of very late stent thrombosis after percutaneous coronary intervention (PCI) with the DES,<sup>14</sup> the role of a longer use of Clopidogrel in preventing very late stent thrombosis (one year after angioplasty) needs to be proved. In a recent study, the use of dual antiplatelet therapy for more than 12 months in patients with the DES was not more effective than Aspirin monotherapy in reducing the rate of myocardial infarction or cardiac death.<sup>15</sup>

The aim of this study was to compare the impact of 12 months' versus 24 months' use of dual antiplatelet therapy on the prevalence of stent thrombosis in patients undergoing PCI with DES implantation.

## Methods

From March 2007 until August 2008, all consecutive patients who underwent successful PCI in Tehran Heart Center, received at least one DES, were treated with dual antiplatelet therapy (Clopidogrel + Aspirin), and were free of major adverse cardiac or cerebrovascular events for a 12-month period after angioplasty were included in this study. Patients were excluded if there was an occurrence of a cardiogenic shock before the procedure, a major complication in the laboratory (death, Q wave myocardial infarction, emergency open cardiac surgery, and cerebrovascular accident), and contraindications to the use of antiplatelet drugs. This study was approved by our institutional review board for the human research. Pre-procedural and procedural information was drawn from the PCI registry of Tehran Heart Center.

The procedural description and detailed definition of the pre- and post-procedural variables in our data registry can be found in our previous studies.<sup>16, 17</sup> In summary, all the PCIs were performed using an arterial access via the standard techniques. The patients received 325 mg of Aspirin before

the procedure, and coronary stenting was performed via the routine methods. Following stent placement, the patients received dual antiplatelet therapy with Aspirin (100 mg/day) and Clopidogrel (75 mg/day) for at least 12 months after the implantation of DES.

Given the controversy in recent years over the time course of the dual antiplatelet therapy use, from 2008 our patients were advised to receive Clopidogrel for either 24 months or 12 months at the interventionists' discretion. Thus, the patients were divided into two groups: those receiving Aspirin and Clopidogrel for 24 months and those receiving Aspirin and Clopidogrel for 12 months.

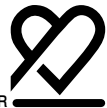The patients were visited in the outpatient clinic 1, 6, and 12 months after PCI regularly and annually thereafter. At these visits, clinical status, all interventions, outcome events, and adverse events were recorded. Those who did not come to the clinic were followed up by telephone and were questioned about the discontinuation time of Clopidogrel and any event. In the case of hospitalization due to myocardial infarction in centers other than our institution, the patients were asked to refer to our outpatient clinic together with all their records of detailed clinical and procedural information during that hospitalization. Patients who interrupted the antiplatelet therapy before the completion of the above-mentioned duration were excluded. Withdrawal of antiplatelet therapy was defined as the interruption of antiplatelet therapy for 7 days regardless of the cause.

The follow-up data were evaluated in detail for death, myocardial infarction, repeated revascularization either via PCI or coronary artery bypass grafting, and cerebrovascular accident during the follow-up period. The end goal of our study was the occurrence of stent thrombosis, defined in accordance with the previously published criteria.<sup>18</sup> The primary endpoint was the first occurrence of myocardial infarction or death from a cardiac cause. The principal secondary endpoints were death from any cause, stroke, and stent thrombosis.

All deaths were considered to be from a cardiac cause unless an unequivocal non-cardiac cause could be established. Definite stent thrombosis was defined as in-stent thrombosis, with or without vessel occlusion, confirmed by angiography or by pathological examination.

Probable stent thrombosis, defined as myocardial infarction or death in the first 30 days after the procedure, was not included because the focus of our study was on later events (after a one-year follow-up). Possible stent thrombosis was defined as myocardial infarction in the distribution of the targeted vessel, where stent thrombosis was not angiographically confirmed and in the absence of any other obvious cause.

The continuous variables are presented as mean  $\pm$  standard deviation. The groups were compared using the Student t-test. The categorical variables are presented by frequencies, and the proportions were compared using the Chi-square test



and Fisher exact test when the expected frequency was less than 5. Event-free survival analysis was performed using the Kaplan-Meier method with log-rank test group comparison. The statistical analyses were carried out with SPSS 15.0 (SPSS, Inc., Chicago, Illinois), and p values < 0.05 (two tailed) were considered statistically significant.

## Results

A total of 961 (83.27%) of the 1154 patients, who underwent angioplasty in our center between March 1<sup>st</sup>, 2007 and August 31<sup>st</sup>, 2008, were eligible to be enrolled in this study. The patients were categorized into two groups according to the duration of their dual antiplatelet therapy.

The mean age was 57 years, and 31% of the patients were women. Group 1 included 399 (42%) patients who stopped Clopidogrel after 12 months and group 2 consisted of 562 (58%) patients who received Clopidogrel for 24 months (100% of the patients were on Clopidogrel and Aspirin at the defined time for each group). From these, 852 (88.7%) patients received one and 109 (11.3%) more than one DES and 69 (7.2%) patients received bare metal stents in addition to the DES. One (3%) patient in group 1 and two (4%)

patients in group 2 underwent primary PCI. The baseline clinical and procedural characteristics of the two study groups are summarized in Table 1. In each group, more than half of the patients had multi-vessel coronary artery disease, and one quarter underwent multi-vessel PCI. No significant difference was observed in terms of the clinical and procedural variables between the two groups. Table 2 demonstrates the distribution of the different DESs in each group. The paclitaxel-eluting stent was the most common type of the DES utilized.

The mean follow-up time was  $35.27 \pm 6.91$  months for all the patients:  $35.55 \pm 6.63$  months for the 12 months' use group and  $35.07 \pm 7.10$  months for the 24 months' use group. During the follow-up period, 11 (1.1%) patients died, 6 (0.6%) of them from cardiac causes. Twelve (1.2%) patients had an acute myocardial infarction and 4 (0.4%) had a stroke. Three patients underwent primary PCI and none of them developed complications. The rate of thrombosis was 10/961 (1%): 4 (0.4%) were definite and 6 (0.6%) were possible cases of stent thrombosis. Repeat revascularization was performed in 22 (2.3%) patients.

After the two-year follow-up period, there was no significant difference with respect to the survival and treatment effects between the two groups (Table 3).

Table 1. Demographic, clinical and procedural characteristics of study population\*

	12 months	24 months	P value
<b>Clinical characteristics</b>			
Mean age (y)	57.54±10.06	57.66±9.10	0.854
Female	124 (31.1)	178 (31.7)	0.845
Previous myocardial infarction	179 (45.1)	232 (41.5)	0.270
Diabetes mellitus	132 (33.2)	167 (29.8)	0.260
Hypertension	185 (46.6)	267 (47.7)	0.742
Hypercholesterolemia	288 (72.5)	375 (67)	0.065
Renal failure	6 (1.5)	3 (0.5)	0.123
<b>Angiographic and procedural characteristics</b>			
Multi-vessel coronary disease	217 (54.4)	333 (59.3)	0.140
Left ventricular ejection fraction	52.16±9.02	51.66±9.57	0.431
<b>Treated vessel</b>			
Left anterior descending	276 (62.3)	404 (63.1)	0.783
Circumflex	60 (13.5)	84 (13.1)	0.842
Right coronary	97 (21.9)	137 (21.4)	0.847
Left main	1 (0.2)	2 (0.3)	0.999
Saphenous vein graft	9 (2.0)	12 (1.9)	0.825
More than one DES implanted	41 (10.3)	68 (12.1)	0.380
Concomitant BMS implanted	24 (6.0)	45 (8.0)	0.239
Ostial lesion	21 (4.7)	47 (7.3)	0.082
Bifurcation lesion	49 (11.1)	54 (8.4)	0.148
At least one lesion type B2/C	351 (88.2)	507 (90.2)	0.316
Total occlusion	33 (7.4)	51 (8.0)	0.753
Multi-vessel PCI	92 (23.1)	125 (22.2)	0.766
Mean RVD	3.12±0.37	3.15±0.36	0.205
Mean stent length	31.85±13.47	31.96±13.37	0.901
Mean Lesion length	26.24±8.64	26.19±8.35	0.928

\*Data are presented as mean±SD or n (%)

DES, Drug-eluting stent; BMS, Bare metal stent; PCI, Percutaneous coronary intervention; RVD, Reference vessel diameter

Table 2. Comparison of different types of drug-eluting stents between patients receiving 12 months' and 24 months' dual antiplatelet therapy\*

	12 months	24 months	P value
Paclitaxel	234 (51.7)	302 (46.5)	0.094
Sirolimus	76 (16.8)	104 (16.0)	0.740
Zotarolimus	72 (15.9)	119 (18.3)	0.292
Everolimus	62 (13.7)	105 (16.2)	0.256
Others	9 (2.0)	19 (2.9)	0.329

\*Data are presented as n (%)

Table 3. Comparison of major cardiac events between patients receiving 12 months' and 24 months' dual antiplatelet therapy\*

	12 months	24 months	P value
Cardiac death	1 (0.3)	5 (0.9)	0.378
Myocardial Infarction	3 (0.8)	9 (1.6)	0.378
Revascularization (CABG or PCI)	11 (2.8)	11 (2.0)	0.414
Definite stent thrombosis	2 (0.5)	2 (0.4)	0.999
Total stent thrombosis	3 (0.8)	7 (1.2)	0.536
Cerebrovascular accident	0	4 (0.7)	0.146

\*Data are presented as n (%)

CABG, Coronary artery bypass grafting; PCI, Percutaneous coronary intervention

In the 12 months' use group, two cases of definite thrombosis occurred at 18 and 13 months post PCI. One possible case of stent thrombosis was observed in this group after 30 months; this patient had stenting in a bifurcation lesion. In the 24 months' use group, two definite cases of stent thrombosis occurred at 14 and 28 months post PCI; one had stenting in a bifurcation lesion. Overall, five cases of possible stent thrombosis were detected at 21, 28, 32, 33, and 34 months after the procedure. It is deserving of note that amongst the 10 cases of stent thrombosis, only 1 (10%) thrombosis occurred when the patient was on Clopidogrel and Aspirin and all the other 9 (90%) cases of stent thrombosis appeared after the discontinuation of the dual antiplatelet therapy. All of the 10 patients received DES implantation.

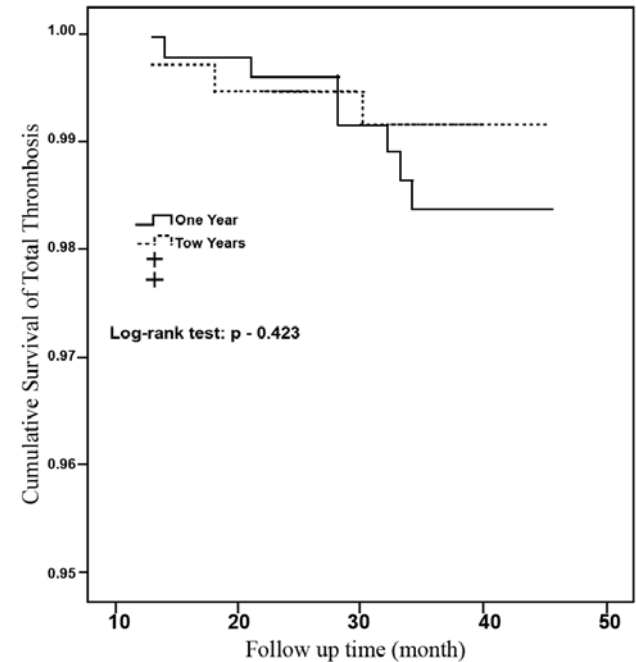
The Kaplan-Meier estimates of freedom from total and definite stent thrombosis and major cardiac adverse events are depicted in Figures 1 and 2.

There was no significant difference between the two treatment groups as regards the risk of primary and secondary endpoints. However, amongst the patients assigned to receive dual antiplatelet therapy, as compared with those receiving Aspirin alone, there was a non-significant increase in the risk of myocardial infarction, stroke, thrombosis, and death.

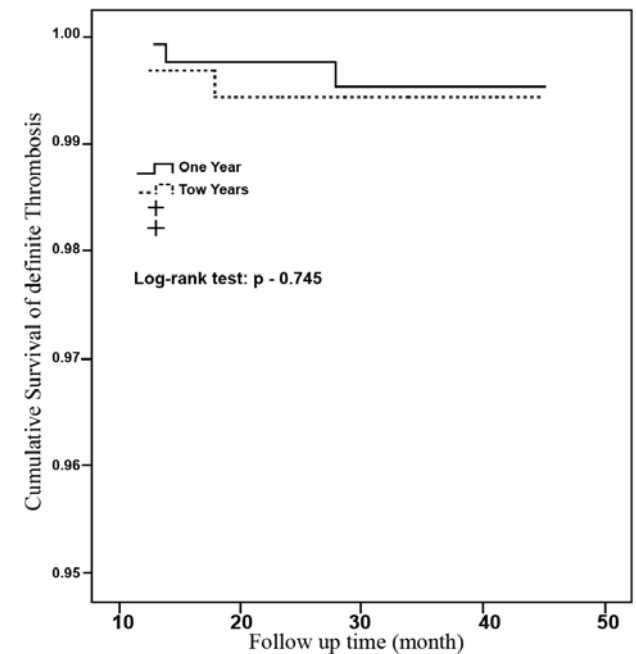
## Discussion

In this study, we found no significant benefit associated with Clopidogrel continuation (use of Clopidogrel plus

Aspirin) as compared with Clopidogrel discontinuation (use of Aspirin alone) after 12 months in reducing the incidence of stent thrombosis, myocardial infarction, stroke, death, and repeat revascularization. The occurrence of the endpoints was higher with Clopidogrel plus Aspirin than that with Aspirin alone, but this difference was not significant.

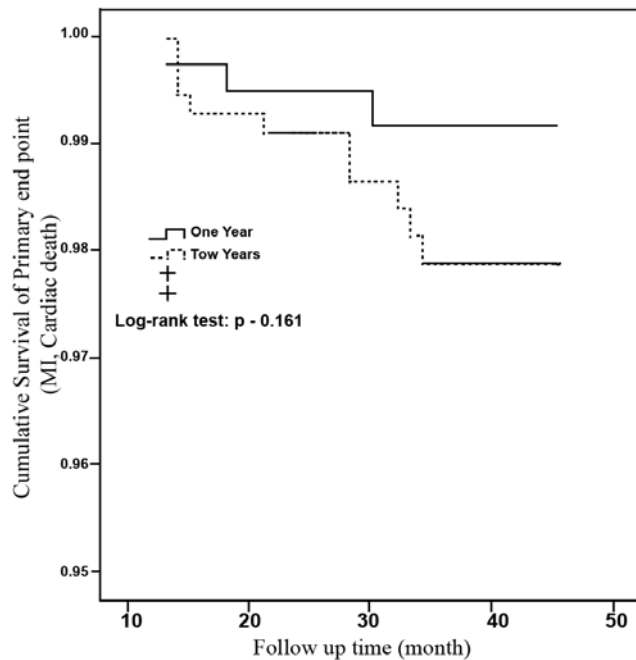
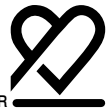

A

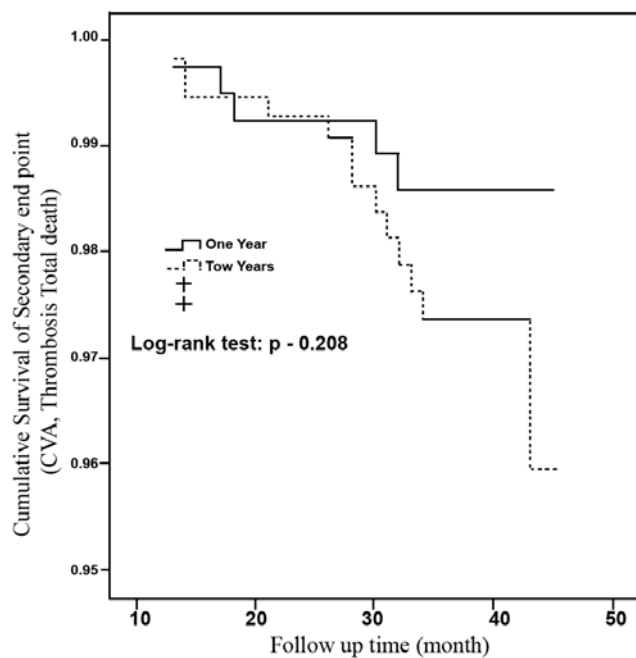


B

Figure 1. The Kaplan-Meier estimates of total thrombosis free (A) and definite thrombosis free (B) survival



A



B

Figure 2. The Kaplan-Meier estimates of primary end point free (cardiac death and myocardial infarction [MI]) (A) and secondary end point free (cerebrovascular [CVA], thrombosis and total death) (B) survival

Our findings showed that the rate of stent thrombosis in patients who underwent successful DES implantation was 1%. Moreover, 90% of the cases of stent thrombosis occurred after the discontinuation of the dual antiplatelet therapy either after 12 months' or after 24 months' use.

The rate of stent thrombosis was between 0% and 2% in previous reports.<sup>19</sup> Total stent thrombosis after 6 months' follow-up in patients undergoing DES implantation who received dual antiplatelet therapy for at least 6 months was 1% in the Ong et al. study.<sup>20</sup> In line with their findings, in the present study the overall rate of stent thrombosis in patients receiving the DES and at least 2 years of dual antiplatelet therapy was 1% during a mean follow-up time of 35 months.

Park et al.<sup>21</sup> reported that Clopidogrel continuation for more than one year did not decrease stent thrombosis and clinical events after DES implantation, and findings by Roy et al.<sup>16</sup> showed that the discontinuation of Clopidogrel during a 12-month period after PCI was not predictive of stent thrombosis. In the present study, 90% of the stent thrombosis events occurred after the discontinuation of Clopidogrel either after 12 months' or after 24 months' use of this drug, which bears out the findings of a study by Eisenstein et al.,<sup>17</sup> who concluded that in patients receiving PCI, the long-term risk for death and major cardiac events was significantly increased amongst patients in the DES group who had discontinued Clopidogrel therapy at 6 or 12 months. Both results are in favor of the idea that the DES may require protracted and possibly indefinite Clopidogrel therapy, although larger studies<sup>17</sup> have suggested that all patients with the DES may benefit from receiving Clopidogrel for up to 24 months after PCI. These results have led to uncertainty about the minimal necessary duration of dual antiplatelet therapy after the implantation of the DES. Our study suggests that the discontinuation of Clopidogrel therapy after approximately one year might have a favorable risk-benefit ratio. Be that as it may, our study is limited by a lack of randomization and by selection bias (longer dual antiplatelet therapy in high-risk patients for stent thrombosis) as well as a small number of patients and a relatively short follow-up period. Because of the small number of the primary and secondary end points, these findings should be interpreted with caution and the interpretation must be speculative, although a similar result was reported in the Park et al. study.<sup>15</sup> Some other limitations of our study should also be taken into consideration: due to the small size of the study population and the small number of the cardiac event rates, our study was underpowered and thus unable to detect a clinically significant difference in the outcomes. Our findings should be confirmed or refuted through larger randomized, clinical trials with long-term follow-up periods.

## Conclusion

In our study, the extended use of dual antiplatelet therapy (for more than 12 months) was not significantly more effective than Aspirin monotherapy in reducing the risk of myocardial infarction or stent thrombosis, death from cardiac cause, and stroke.



Our study did not have sufficient statistical power to allow for a firm conclusion regarding the safety of Clopidogrel discontinuation after 12 months. Larger clinical trials will, therefore, be necessary to resolve this issue.

## Acknowledgements

We would like to thank Miss Fatemeh Esfahani and Mina Pashang for their kind assistance in data gathering and Dr. Mahmood Sheikh Fathollahi for his assistance in data analysis.

## References

1. Babapulle MN, Eisenberg MJ. Coated stents for the prevention of restenosis: part II. *Circulation* 2002;106:2859-2866.
2. Colombo A, Drzewiecki J, Banning A, Grube E, Hauptmann K, Silber S, Dudek D, Fort S, Schiele F, Zmudka K, Guagliumi G, Russell ME. Randomized study to assess the effectiveness of slow- and moderate-release polymer-based paclitaxel-eluting stents for coronary artery lesions. *Circulation* 2003;108:788-794.
3. Moses JW, Leon MB, Popma JJ, Fitzgerald PJ, Holmes DR, O'Shaughnessy C, Caputo RP, Kereiakes DJ, Williams DO, Teirstein PS, Jaeger JL, Kuntz RE. Sirolimus-eluting stents versus standard stents in patients with stenosis in a native coronary artery. *N Engl J Med* 2003;349:1315-1323.
4. Stone GW, Ellis SG, O'Shaughnessy CD, Martin SL, Satler L, McGarry T, Turco MA, Kereiakes DJ, Kelley L, Popma JJ, Russell ME. Paclitaxel-eluting stents vs vascular brachytherapy for in-stent restenosis within bare-metal stents: the TAXUS V ISR randomized trial. *JAMA* 2006;295:1253-1263.
5. Babapulle MN, Joseph L, Belisle P, Brophy JM, Eisenberg MJ. A hierarchical Bayesian meta-analysis of randomised clinical trials of drug-eluting stents. *Lancet* 2004;364:583-591.
6. Alidoosti M, Salarifar M, Haji-Zeinali AM, Kassaian SE, Dehkordi MR, Fathollahi MS. Clinical outcomes of drug-eluting stents compared with bare metal stents in our routine clinical practice. *Hellenic J Cardiol* 2008;49:132-138.
7. Finn AV, Joner M, Nakazawa G, Kolodgie F, Newell J, John MC, Gold HK, Virmani R. Pathological correlates of late drug-eluting stent thrombosis: strut coverage as a marker of endothelialization. *Circulation* 2007;115:2435-2441.
8. Joner M, Finn AV, Farb A, Mont EK, Kolodgie FD, Ladich E, Kutys R, Skorija K, Gold HK, Virmani R. Pathology of drug-eluting stents in humans: delayed healing and late thrombotic risk. *J Am Coll Cardiol* 2006;48:193-202.
9. Spertus JA, Kettelkamp R, Vance C, Decker C, Jones PG, Rumsfeld JS, Messenger JC, Khanal S, Peterson ED, Bach RG, Krumholz HM, Cohen DJ. Prevalence, predictors, and outcomes of premature discontinuation of thienopyridine therapy after drug eluting stent placement: results from the PREMIER registry. *Circulation* 2006;113:2803-2809.
10. Iakovou I, Schmidt T, Bonizzoni E, Ge L, Sangiorgi GM, Stankovic G, Airoldi F, Chieffo A, Montorfano M, Carlino M, Michev I, Corvaja N, Briguori C, Gerckens U, Grube E, Colombo A. Incidence, predictors, and outcome of thrombosis after successful implantation of drug-eluting stents. *JAMA* 2005;293:2126-2130.
11. King SB, III, Smith SC, Jr, Hirshfeld JW, Jr, Jacobs AK, Morrison DA, Williams DO, Feldman TE, Kern MJ, O'Neill WW, Schaff HV, Whitlow PL; ACC/AHA/SCAI, Adams CD, Anderson JL, Buller CE, Ceager MA, Ettanger SM, Halperin JL, Hunt SA, Krumholz HM, Kushner FG, Lytle BW, Nishimura R, Page RL, Riegel B, Tarkington LG, Yancy CW. 2007 Focused update of the ACC/AHA/SCAI 2005 guideline update for percutaneous coronary intervention: a report of the American College of Cardiology/American Heart Association Task Force on Practice guidelines. *J Am Coll Cardiol* 2008;51:172-209.
12. Butler MJ, Eccleston D, Clark DJ, Butler MJ, Eccleston D, Clark DJ, Ajani AE, Andrianopoulos N, Brennan A, New G, Black A, Szto G, Reid CM, Yan BP, Shaw JA, Dart AM, Duffy SJ; Melbourne Interventional Group. The effect of intended duration of clopidogrel use on early and late mortality and major adverse cardiac events in patients with drug-eluting stents. *Am Heart J* 2009;157:899-907.
13. Weideman RA, Little BB, Kelly KC, Rao SV, Reilly RF, Brilakis ES. Comparison of the impact of short (<1 year) and long term (> or =1year) clopidogrel use following percutaneous coronary intervention on mortality. *Am J Cardiol* 2008;102:1159-1162.
14. Tanzilli G, Greco C, Pelliccia F, Pasceri V, Barilla F, Paravati V, Pannitteri G, Gaudio C, Mangieri E. Effectiveness of two-year clopidogrel + aspirin in abolishing the risk of very late thrombosis after drug-eluting stent implantation (from the TYCOON [two-year CLOpidogrel need] study). *Am J Cardiol* 2009;104:1357-1361.
15. Park SJ, Park DW, Kim YH, Kang SJ, Lee SW, Lee CW, Han KH, Park SW, Yun SC, Lee SG, Rha SW, Seong IW, Jeong MH, Hur SH, Lee NH, Yoon J, Yang JY, Lee BK, Choi YJ, Chung WS, Lim DS, Cheong SS, Kim KS, Chae JK, Nah DY, Jeon DS, Seung KB, Jang JS, Park HS, Lee K. Duratin of dual antiplatelet therapy after implantation of drug-eluting stents. *N Engl J Med* 2010;362:1374-1382.
16. Roy P, Bonello L, Torguson R, Okabe T, Pinto Slottow TL, Steinberg DH, Kaneshige K, Xue Z, Satler LF, Kent KM, Suddath WO, Pichard AD, Lindsay J, Waksman R. Temporal relation between clopidogrel cessation and stent thrombosis after drug-eluting stent implantation. *Am J Cardiol* 2009;103:801-805.
17. Eisenstein EL, Anstrom KJ, Kong DF, Shaw LK, Tuttle RH, Mark DB, Kramer JM, arrington RA, Matchar DB, Kandzari DE, Peterson ED, Schulman KA, Califf RM. Clopidogrel use and long-term clinical outcomes after drug-eluting stent implantation. *JAMA* 2007;297:159-168.
18. Mauri L, Hsieh WH, Massaro JM, Ho KK, D'Agostino R, Cutlip DE. Stent thrombosis in randomized clinical trials of drug-eluting stents. *N Engl J Med* 2007;356:1020-1029.
19. Moreno R, Fernandez C, Hernandez R, Alfonso F, Angiolillo DJ, Sabate M, Escaned J, Banuelos C, Fernandez-Ortiz A, Macaya C. Drug-eluting stent thrombosis: results from a pooled analysis including 10 randomized studies. *J Am Coll Cardiol* 2005;45:954-959.
20. Ong AT, Hoye A, Aoki J, van Mieghem CA, Rodriguez Granillo GA, Sonnenschein, Regar E, McFadden EP, Sianos G, van der Giessen WJ, de Jaegere PP, de Feyter P, van Domburg RT, Serruys PW. Thirty-day incidence and six-month clinical outcome of thrombotic stent occlusion after bare-metal, sirolimus, or paclitaxel stent implantation. *J Am Coll Cardiol* 2005;45:947-953.
21. Park DW, Yun SC, Lee SW, Kim YH, Lee CW, Hong MK, Cheong SS, Kim JJ, Park SW, Park SJ. Stent thrombosis, clinical events, and influence of prolonged clopidogrel use after placement of drug-eluting stent: data from an observational cohort study of drug-eluting versus bare-metal stents. *J Am Coll Cardiol Intv* 2008;1:494-503.