

# Dracula tooth: A very rare case report of peg-shaped mandibular incisors

Ashwin Devasya,  
Mythri Sarpangala<sup>1</sup>  
Department of Pedodontics  
and Preventive Dentistry and  
<sup>1</sup>Periodontology, Kannur Dental  
College, Anjarakandy, Kannur,  
Kerala, India

**Address for correspondence:**  
Dr. Ashwin Devasya,  
Department of Pedodontics and  
Preventive Dentistry, Kannur  
Dental College, Anjarakandy,  
Kannur, Kerala, India.  
E-mail: ashwindkumbla@gmail.  
com

## Abstract

Microdontia is a term used to describe teeth which are smaller than normal. Peg-shaped teeth are type of microdontia, a developmental disturbances of teeth mainly due to congenital reasons. Most commonly affecting single teeth, that is maxillary lateral incisors. Incidence of peg shaped tooth in maxillary laterals are usually seen and reported. But in mandibular arch it is very rare. Present case, it affected all the incisors of mandibular arch and also the laterals of maxillary arch which is rarest of condition. This case report presents a non syndromic, peg shaped mandibular incisors in a 11 year old male patient.

**Key words:** Incisors, mandibular, microdontia, peg-shaped teeth

## Introduction

People of all ages are increasingly concerned about their smile and overall appearance. Dental anomalies such as alterations in shape, size, position, color, or texture may have a negative influence on the harmony of smile.<sup>[1]</sup> Dental anomalies can result from numerous genetic and environmental factors. Even though both prenatal and postnatal period are blamed for anomalies in tooth dimensions, position, and number; events in the prenatal period has the most influence on these defects.<sup>[2]</sup>

Peg-shaped laterals are dental anomalies that are likely to be connected to defects in certain genes. There is a strong component of heredity, and peg-shaped lateral incisors have been linked genetically with tooth agencies.<sup>[3,4]</sup> A peg-shaped incisor has a marked reduction in diameter, extending from the cervical region to the incisal edge.<sup>[5]</sup>

Peg shaped incisors are commonly seen affecting the maxillary lateral incisors. The prevalence reported varies from 0.8% to 8.4% of the population.<sup>[6]</sup> The prevalence rates are higher among Mongoloid people, orthodontic patients, and women. Although the prevalence of unilateral and bilateral lateral incisors are the same, the left side of arch is twice as common as the right side.<sup>[7]</sup>

Peg shaped mandibular incisors are mostly associated with syndromes [Table 1].<sup>[8]</sup> Very few case reports have mentioned peg-shaped central or lateral incisors in the mandible. This case report will help clinicians to look at a different possibility of occurrence of peg-shaped tooth in a non syndromic condition and will help to explore more. We present a very rare case report of nonsyndromic peg shaped mandibular incisors and maxillary lateral incisors in an individual.


## Case Report

A healthy 11-year-old boy reported to our dental clinic with a complaint of his pointy shaped front tooth. Ethical clearance

This is an open access article distributed under the terms of the Creative Commons Attribution-NonCommercial-ShareAlike 3.0 License, which allows others to remix, tweak, and build upon the work non-commercially, as long as the author is credited and the new creations are licensed under the identical terms.

**For reprints contact:** reprints@medknow.com

**How to cite this article:** Devasya A, Sarpangala M. Dracula tooth: A very rare case report of peg-shaped mandibular incisors. J Forensic Dent Sci 2016;8:164-6.

Access this article online	
<b>Website:</b> www.jfds.org	<b>Quick Response Code</b> 
<b>DOI:</b> 10.4103/0975-1475.195123	

was taken from a local review board of Indian Dental Association and Informed consent was taken from the parent especially mentioning for the publication purpose. All of his classmates ridicule him by calling him “Dracula tooth” which emotionally disturbs the boy. His past medical history was not contributory, and family history revealed that his maternal uncle had congenitally small sharp teeth.

The patient had no history of trauma or extraction. Extra- and intra-oral examinations showed no abnormalities. Clinical examination showed normal skin, nail, and hair. Intraoral hard tissue examination revealed a mixed dentition stage.

In his mandible, peg-shaped permanent central, lateral, and right permanent canines are present. The left permanent canine is partially erupted hence there is no confirmation of that tooth being peg shaped. In the maxilla, permanent lateral incisors are peg shaped; central incisors were of normal shape with mamelons. Based on these findings, it was diagnosed as nonsyndromic bilateral microdontic peg-shaped mandibular incisors [Figures 1 and 2].

Permission from his parents for orthopantomogram (OPG) to be taken for further diagnosis and given the treatment options as composite restorations to improve the esthetics of the tooth. Parents refused the treatment. Parents advised

that a periodic check up every 6 months to follow-up the eruption and fate of the canine and other permanent teeth should be scheduled.

Ethical clearance was taken from a local review board of Indian Dental Association and also informed consent was taken from the parent to publish this rare case.

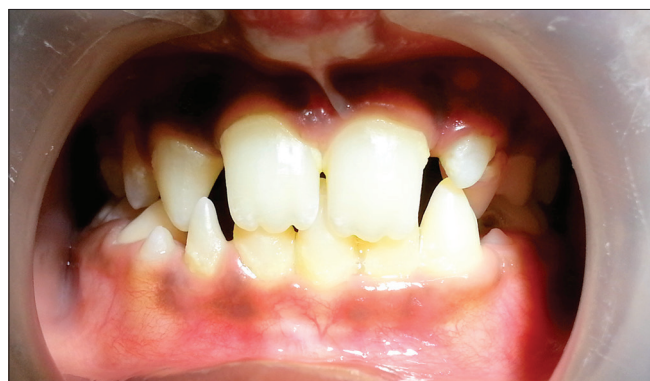## Discussion

Anomalies of tooth number, structure, and morphology can occur within human dentition secondary to genetic and epigenetic influences. These aberrations can manifest as microdontia, macrodontia, hypodontia, and oligodontia.<sup>[9]</sup> Koch *et al.*<sup>[10]</sup> defined tooth size as abnormal, when dimensions deviate two standard deviations from average. This size abnormality can manifest either as macrodontia or microdontia. Microdontia is used to describe teeth which are smaller than normal, i.e. outside the usual limits of variation. The deciduous dentition appears to be affected more by maternal intrauterine influences; while the permanent teeth seem to be more affected by the environment.<sup>[5]</sup> Single tooth microdontia is a common condition. One of the most common forms of localized microdontia is that which affects the lateral maxillary incisors, called a “peg lateral.”<sup>[5]</sup> Peg-shaped teeth are anterior teeth in the primary or permanent dentition with a crown diameter that decreases markedly from cervical margin to incisal edge, thus resulting in the characteristic peg shape.<sup>[11]</sup>

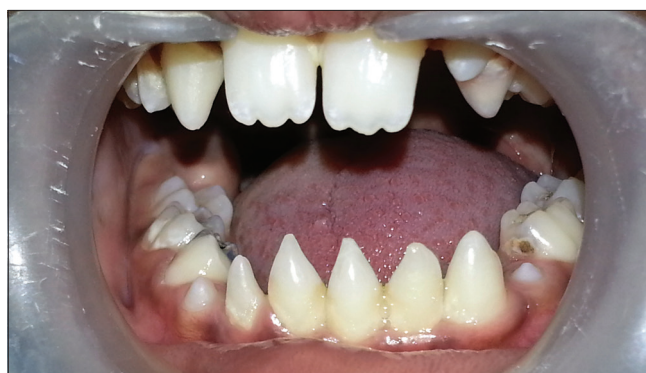The endocrine disturbances may affect the size/form of the crown of teeth in utero or in the first year of life. Size and shape of the root, however, may be altered by disturbances in later periods. Disturbances in morphodifferentiation may affect the form and size of the tooth without impairing the function of the tooth and the function of ameloblasts/odontoblasts, thus, the result may be a peg-shaped/malformed tooth with enamel and dentine that may be normal in structure.<sup>[11]</sup> Documentation of discrepancies helps in assessing the evolutionary structural and morphological changes in human dentition.<sup>[11,12]</sup>

**Table 1: Syndromes associated with mandibular peg shaped incisors**

William’s syndrome
Gorlin-Chaudhry-Moss syndrome
Ullrich-Turner syndrome
Chromosome 13 syndrome
Rothmund–Thomson syndrome
Hallermann–Streiff syndrome
Orofaciodigital syndrome (type 3)
Oculomandibulofacial syndrome
Trichorhinophalangeal syndrome
Type 1 branchiooculofacial syndrome



**Figure 1:** Peg-shaped maxillary incisors



**Figure 2:** Peg-shaped mandibular incisors

**Table 2: Treatment options for peg shaped laterals**

No treatment, patient not concerned
Orthodontic treatment first to align the teeth in the arch
Direct composite bonding onto peg laterals
Indirect composite placement
Bonded crowns
Porcelain bonded to metal crowns (Bello 1997)
Crown lengthening surgery to get better gingival heights than direct bonding
Extractions and implant placement
Combinations of treatment in different sequences

The reports of peg-shaped laterals in the maxilla is more prevalent than any other tooth as 1.8% of incidence is seen<sup>[7]</sup> and 2.15% in the Turkish population,<sup>[13]</sup> 4.3% in the Iranian population,<sup>[7]</sup> and 2.58% in the Indian population.<sup>[14]</sup>

Many studies report maxillary teeth being peg shaped yet only five cases report that the mandibular tooth is affected. Four studies report mandibular central incisor being peg shaped<sup>[8,15-17]</sup> and one study reports the mandibular lateral incisor being affected.<sup>[18]</sup> The treatment aspect of these peg shaped tooth is always esthetic and orthodontic corrected [Table 2].<sup>[19]</sup>

The present case report highlights the alteration of the shape of mandibular incisors, which can affect the psychological well-being of the patient if not treated at an early stage. Since dental esthetics is known to affect the overall quality of life, it is important that a multidisciplinary approach is adopted in the treatment of patients with tooth deformity.

### Financial support and sponsorship

Nil.

### Conflicts of interest

There are no conflicts of interest.

### References

1. Townsend CL. Resective surgery: An esthetic application. *Quintessence Int* 1993;24:535-42.
2. Uslu O, Akcam MO, Evirgen S, Cebeci I. Prevalence of dental

anomalies in various malocclusions. *Am J Orthod Dentofacial Orthop* 2009;135:328-35.

3. Witkop CJ Jr. Agensis of succedaneous teeth: An expression of the homozygous state of the gene for the pegged or missing maxillary lateral incisor trait. *Am J Med Genet* 1987;26:431-6.
4. Arte S, Nieminen P, Apajalahti S, Haavikko K, Thesleff I, Pirinen S. Characteristics of incisor-premolar hypodontia in families. *J Dent Res* 2001;80:1445-50.
5. Neville BW, Damm DD, Allen CM, Bouquot JE. *Oral and Maxillofacial Pathology*. 2<sup>nd</sup> ed. India: Saunders; 2004.
6. Ezoddini AF, Sheikhha MH, Ahmadi H. Prevalence of dental developmental anomalies: a radiographic study. *Community Dent Health* 2007;24:140-4.
7. Hua F, He H, Ngan P, Bouzid W. Prevalence of peg-shaped maxillary permanent lateral incisors: A meta-analysis. *Am J Orthod Dentofacial Orthop* 2013;144:97-109.
8. Bargale SD, Kiran SD. Non-syndromic occurrence of true generalized microdontia with mandibular mesiodens – A rare case. *Head Face Med* 2011;7:19.
9. Malleshi SN, Basappa S, Negi S, Irshad A, Nair SK. The unusual peg shaped mandibular central incisor – Report of two cases. *J Res Pract Dent* 2014;1:1-6.
10. Koch G, Poulsen S. *Pediatric Dentistry: A Clinical Approach*. 2<sup>nd</sup> ed. Oxford: Blackwell Publishing; 2009.
11. Shafer WG, Hine MK, Levy BM, Tomich CE. *Text Book of Oral Pathology*. 4<sup>th</sup> ed. Philadelphia: Saunders; 1993.
12. Pinheiro FN. *Ectodermal Dysplasias: A Clinical and Genetic Study*. New York: Alan R. Liss; 1984.
13. Karatas M, Akdag MS, Celikoglu M. Investigation of the peg-shaped maxillary lateral incisors in a Turkish orthodontic subpopulation. *J Orthod Res* 2014;2:125-8.
14. Shalini Sharma, S Sudeep, Singh A. A Rare Presentation of Non-Syndromic Unilateral Peg Shaped Mandibular Central Incisor – A Case Report. *J Res Adv Dent* 2014; 3:3:63-66. Available form: <http://www.jrad.co.in/volume-3-number-3-article.html>. [Last accessed on 2016 Aug 25].
15. Sharma S, Sudeep S, Singh A. A rare presentation of non-syndromic unilateral peg shaped mandibular central incisor – A case report. *J Res Adv Dent* 2014;3:63-6.
16. Rathore R, Phulari RG, Jain S. Peg shaped mandibular lateral incisor in a hypodontia patient: A case report. *IJSSCase Rep Rev* 2015;8:14-6.
17. Chanchala HP, Nandlal B. Coexistent peg shaped mandibular central incisors along with maxillary lateral incisors: A rare case. *Int J Oral Maxillofac Pathol* 2012;3:65-8.
18. Altug-Atac AT, Erdem D. Prevalence and distribution of dental anomalies in orthodontic patients. *Am J Orthod Dentofacial Orthop* 2007;131:510-4.
19. Greenwell L. Treatment options for peg-shaped laterals using direct composite bonding. *Int Dent S Afr* 2010;12:26-33.