



Review

# Management of acquired rectourethral fistulas in adults

Shulian Chen, Rang Gao, Hong Li, Kunjie Wang\*

Department of Urology, Institute of Urology (Laboratory of Reconstructive Urology), West China Hospital, Sichuan University, Chengdu, Sichuan, China

Received 23 September 2016; received in revised form 14 June 2017; accepted 30 October 2017  
Available online 31 January 2018

## KEYWORDS

Rectourethral fistula;  
Prostate cancer;  
Radical prostatectomy;  
Radiation therapy;  
Diagnosis;  
Management

**Abstract** Rectourethral fistula is an uncommon but devastating condition resulting from surgery, radiation, trauma, inflammation, or occasionally anorectal anomaly. Because of involving the urinary and the digestive system, surgical repair can be challenging. More than 40 different surgical approaches were described in the literature. However, no standardized management exists due to the rarity and complexity of the problem. Spontaneous closure of fistula is rare and most cases need reconstructive procedures. Appropriate preoperative assessment is crucial for the decision of operation time and method. Gradually accumulating evidence indicates surgeons should take fistula size, tissue health and vascularity associated with radiation or infection, urethral stricture, and bladder neck sclerosis into consideration and make a proper treatment plan according to the features of various approaches. Accurate preoperative evaluation and proper approach selection would increase success rates. Multiple surgical team corporation, including colorectal, urological and plastic surgeons, would optimize the outcomes.

© 2018 Editorial Office of Asian Journal of Urology. Production and hosting by Elsevier B.V. This is an open access article under the CC BY-NC-ND license (<http://creativecommons.org/licenses/by-nc-nd/4.0/>).

## 1. Introduction

Rectourethral fistula (RUF) is a connection between the lower urinary tract and the distal part of the rectum. RUFs are rare conditions and can be classified as congenital or acquired [1]. Congenital RUFs, usually related to

imperforate anus, represent a small subset of this pathology and are managed by pediatric surgeons [2–4]. Acquired RUFs resulting from surgery, radiation, trauma, or inflammation often occur in adults and account for the majority of the condition [5]. Due to the rarity of cases and the heterogeneity of causes, RUFs represent a big challenge to

\* Corresponding author.

E-mail address: [wangkj@scu.edu.cn](mailto:wangkj@scu.edu.cn) (K. Wang).

Peer review under responsibility of Second Military Medical University.

urologists and devastating circumstance to patients. Spontaneous closure of the fistula is infrequent and most cases need surgical repair [6–8].

Though over 40 approaches have been described in the literature varying from transanal endoscopic microsurgery to transabdominal surgery, as a result of absence of randomized control study and ideal protocol guiding clinical practice, there is to date no consensus on the optimal method of repair. Surgeon's familiarity with certain procedure often determines the choice. However, RUFs developed by different causes possess different characteristics and different approaches hold varying pros and cons [9–11]. Consequently, it is imperative to review and update the characteristics of RUFs and corresponding repair approaches in order to gain more successful therapeutic effect. Herein, we mainly focus on the acquired RUFs in adults, as they represent the majority of this condition and implicate more difficulty in terms of treatment.

## 2. Incidence and etiology

Acquired RUFs may be caused by surgery of prostate or anorectal cancer, radiation or cryotherapy, trauma, infection. Among them, radical prostatectomy is the main reason, ensuing radiation and ablative therapy. Other rare causes reported in the literature included radiation therapy for rectal cancer [12], repeated prostate biopsy, sclerotherapy for hemorrhoids [13], Fournier's gangrene [14], and Crohn's disease [15].

The incidence of RUFs after prostatectomy was about 0.53%. Most RUFs resulted from unrecognized rectal injury during the operation and usually located at the vesicourethral anastomosis [16]. Prior radiation and/or ablative therapies, in a dose-dependent manner, increased the risk of RUFs after prostatectomy and decreased the likelihood of spontaneous closure of fistula as a result of ischemic and fibrotic tissues they induced [17]. Moreover, these therapies also complicated the repair surgery due to the lack of laxity and the avascularity of the surrounding tissues [18,19].

In addition to surgery, combination or monotherapy of radiation, brachytherapy, cryotherapy, high-intensity focused ultrasound (HIFU) can also incur RUFs, with the incidence rate varying from 0.1% to 3.3% according to the therapy used [20–24]. Advanced age and salvage therapies were related to higher rates of RUFs [17,25]. Rates of rectal injury ranged from 2% to 9% during salvage retropubic radical prostatectomy (RRP), in contrast to 0%–4% in the primary RRP [26,27]. In contrast to primary treatment of prostate cancer, salvage external beam radiotherapy or salvage brachytherapy could increase RUF incidence rate from 0.6% to 3% [28]. It was hard to estimate the accurate incidence rate of RUFs induced by trauma and infection, because of the rarity of these entities [14,29,30].

## 3. Diagnosis and evaluation

Accurate diagnosis and proper preoperative assessment of RUFs are essential for treatment planning. Primary clinical presentations consist of fecaluria, pneumaturia, and urinary drainage through the rectum, as well as some

other symptoms, including hematuria, urinary tract infection, abdominal pain, and fever [16,31,32]. Amid them, fecaluria usually suggests a poor prognosis, which indicates large fistula size [32]. Other factors related to poorer outcomes are large fistula size (>2 cm), radiation and cryotherapy [18,33]. Radiation and cryotherapy may result in microvascular injuries and mucosal ischemia, increasing difficulties in repair.

Clinical suspicion requires a series of complementary tests to confirm diagnosis. Fistulas may be palpated in the anterior rectal wall through digital examination. Cystoscopy and sigmoidoscopy visualize the fistula tract in most cases and provide access for biopsy which is important for prior malignancy to rule out local recurrence, meanwhile, they enable the assessment of the vitality and viability of the surrounding tissues [34]. Voiding cystourethrography or retrograde urethrography usually provides a definitive diagnosis and delineate the size and location of RUFs, which is important for surgical planning. Besides that, upper urinary imaging should be carried out to exclude ureteral injury. In elderly and radical prostatectomy patients, it is important to assess the continence and sphincteric function in preoperative counseling, because repair of RUFs only is insufficient to bring about continence in many patients with severe stress incontinence [33].

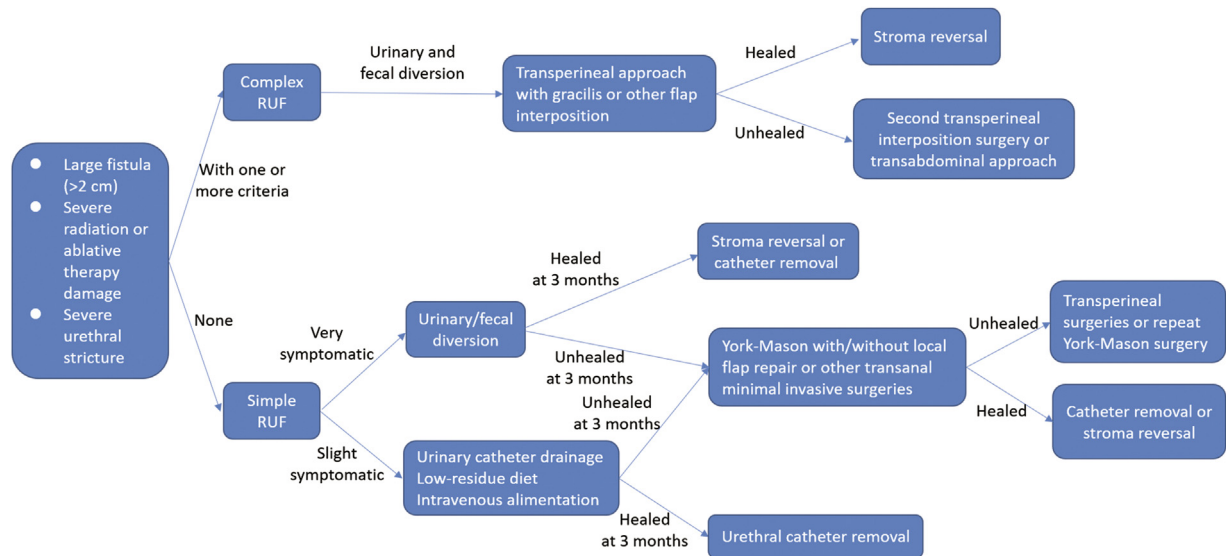
## 4. Management

Though over 100 years has passed since the first reported surgical management of RUFs, treatment of this pathology remains the most debated topic [35]. There is no consensus on the optimal procedure of choice. Reasons can be ascribed to the rarity and the complexity of RUFs, and absence of comparative trials in the published literature. However, with the accumulation of experience resulting from cases, particularly some large sample studies, some principles of importance can be extracted [5,12,16,36,37].

Prior to treatment planning, accurate assessment of the complexity of RUF is crucial for employing appropriate approach. There are several important factors highly associated with the complexity of RUFs [10,16,38]. If fistula size larger than 2 cm, presence of severe urethral stricture, and/or ischemic tissue due to prior ablative therapies exist, RUF is considered complex. On the other hand, a fistula is regarded as simple [5,12]. Fig. 1 shows the management algorithm for RUFs.

## 5. Conservative management

Conservative management refers to procedures without surgical intervention of fistula, including low residue diet, urethral catheterization, urinary or fecal diversion related surgery such as suprapubic cystostomy, nephrostomy, ileostomy, and colostomy [39]. Residue diet, urethral catheterization and hyperalimentation can be applied to simple RUF without severe symptoms. For simple RUF with severe symptoms, urinary diversion and/or fecal diversion should be used to alleviate present symptoms [40]. If the epithelization of the fistulous tract is visualized by cystoscopy or sigmoidoscopy, spontaneous closure is rarely possible [41]. General closure interval of simple fistula is



**Figure 1** Management algorithm for RUF. RUF, rectourethral fistula.

within 12 weeks. If fistula still exits exceeding 12 weeks, surgical treatment should be adopted [38]. Spontaneous closure of complex RUFs is exceptional, especially in radiated tissues, so conservative methods should not be employed in these patients. Success rate of conservative management in simple RUFs ranged from 14% to 100% [32,42,43].

## 6. Surgical management

Surgical repair is often used for complex RUFs. Though not always possible, closure of fistula and restoration of bowel and bladder function should be the treatment goal for RUF [10]. Despite a large array of approaches were described in the literature, four main approaches were frequently used in large volume reconstructive urology centers, including transperineal, transsphincteric (York–Mason), transanal and transabdominal (open, laparoscopic, or robotic). The advantages, disadvantages and indications of the four approaches are shown in Table 1.

The transsphincteric approach: It is well known as York–Mason approach which was first reported by Kilpatrick and Mason [44] in 1969. This method makes preservation of potency, urinary continence, and rectal innervation possible as a result of avoiding intervention of lateral pelvic and pararectal space. However, there are several intrinsic limitations in the procedure. First, it is difficult to expose the bulbar and membranous urethra, hindering urethral reconstruction [10]. Second, apart from local rectal advancement flap, it is impossible to use other healthy tissue flap to separate the rectum and urethra. Therefore this approach is not suitable for RUF patients caused by radiation or ablative therapies [45]. Third, it is associated with higher rates of wound dehiscence, wound infection and possibility of fecal fistula. Fourth, due to division of anal sphincter, fecal incontinence is one of the feared complications [12]. However, the reported complication rate of fecal incontinence in the literature was less than 1% [46]. According to the report of Hechenbleikner et al. [5], employing this method, the

overall success rate of nonirradiated and irradiated RUF patients was 94.7% and 75%, respectively. Now, this method is widely used in the treatment of simple RUFs in suitable patients [47].

The transperineal approach: In 1904, Lydston [48] first reported transperineal surgical treatment for RUFs. This is the most commonly used method for the complex RUFs in the literature, with the advantage of wide exposure of the urethra and rectum, enabling various flap interposition, avoiding intervention in multi-operated area in the setting of previous abdominal surgery, and facilitating urethral reconstruction. An array of interposition flaps have been shown in the published studies, including gracilis, dartos, gluteus maximus, omentum, island groin, scrotal myocutaneous, dartos pedicle flaps, and levator ani muscle. Among them, gracilis muscle is the most-widely used one, because of its excellent vascularity and easy mobility with minimal donor site morbidity. Particularly, gracilis muscle is far from radiation location exempt from ischemic and hypoxia damage. However, special consideration should be taken on the baseline urinary function on this population, due to its intervention around the urethral sphincter. Stress urinary incontinence is the most common complication in patients following transperineal gracilis muscle interposition with reported incidence rate ranging from 58% to 70% [10,49]. Voelzke et al. [50] who reported 23 RUF patients treated with transperineal approach highlighted the importance of an interposition muscle flap to increase successful outcomes in the setting of energy ablative RUFs. Vanni et al. [51] treated 74 RUF patients using transperineal approach in a single stage, with 100% and 84% closure rates for nonradiated RUFs and radiated/ablation RUFs respectively at a mean follow-up of 20 months. A study by Ghoniem et al. [33] reported 25 complex RUFs treated with transperineal approach and achieved 100% closure rate at a mean follow-up of 28 months. Recently, a multi-institutional study was published by Harris and his colleagues [52], which included 210 RUF patients secondary to prostate cancer treatment. A transperineal approach was used in 79% of patients. Muscle

**Table 1** Advantages, disadvantages and indications for the four main approaches in the treatment of rectourethral fistula.

Approaches	Advantages	Disadvantages	Indications	Representative references
Transperineal approach	Wide exposure of the urethral and rectum Various flap interposition Facilitating urethral reconstruction	Stress urinary incontinence Bladder outlet contracture	Complex RUFs, large fistula size, urethral stricture, radiation, ablative therapy	[10,33,44,49–51]
Transsphincteric approach (York–Mason)	Small morbidity Preserving urinary continence	Relative small exposure of urethra, rectal sphincter injury Unsuitable in patients with severe proctitis	Simple fistula, small size, nonradiation, non-ablative therapy	[6,10,12,44–47]
Transanal minimal invasive surgeries	Minimal postoperative morbidity and mortality Shortened hospital stay Without involving division of sphincter	Relative small maneuver space	Simple fistula, small size, nonradiation, non-ablative therapy	[1,12,19,34,38,51–53]
Transabdominal approach	Enabling greater omental flap interposition	Intervening abdominal cavity Deep pelvic dissection	Complex RUFs, comorbidity of non-functioning bladder, positive surgical margins	[11,54–58]

RUFs, rectourethral fistulas.

flap and omentum were used in 91.9% of cases. The overall success rate was 92.8% and the authors suggested surgical repair using muscle or omentum flap to avoid permanent urinary diversion. From May 2015 to August 2017, we treated five complex RUFs using transperineal approach with a mean follow-up of 14.3 months in our center, and all patients were free of fistula recurrence. Together with aforementioned studies and our experience, the transperineal approach should be a suitable method for complex RUFs, and muscle flap interposition can increase the success rate, especially for large fistula size, radiation and ablation circumstances [5].

The transabdominal approach: This is a less commonly used approach which is conducive to offer greater omentum or peritoneum flap for interposition [1,19,34]. Specially, it is suitable for non-functional bladder or positive oncologic margins, which provides extensive excision and corresponding repair procedure [38]. However, open surgery via abdomen usually involves greater morbidity, a longer recovery period, more importantly poor exposure in the deep pelvis and can be technically difficult in patients who have undergone prior abdominal surgery [12]. Using laparoscopy-assisted abdominal approach with omentum flap, Sotelo et al. [53] treated three patients with simple RUF following a 100% success rate. Linder et al. [54] shared their experience using robot-assisted technique for surgical repair of one postoperative RUF with success. To date, data pertaining to this approach are rare and limited to simple RUFs.

The transanal approach: This method was first introduced by Jones et al. [55] in 1987 for the treatment of RUFs. This is a less commonly used approach for simple RUFs. In literature, there are two methods via transanal approach, transanal endoscopic microsurgery (TEM) and transanal minimal invasive surgery (TMIS). Wilbert et al. [56], Quinlan et al. [57], and Bochove-Overgaauw et al. [58] reported five cases of RUFs with TEM repair. Of them, four

succeeded and the fistula of one patient with a failed prior graciloplasty persisted. Atallah et al. [59], documented TMIS successfully repaired the RUF secondary to cryoablative therapy for prostate cancer in one patient. Recently, Nicita et al. [11] reported 12 RUF patients who were successfully treated with TMIS. However, RUFs in this study were smaller than 1.5 cm and were not radiation-induced.

Some other assisted procedures, such as application of fibrin glue or fulguration for the fistulous tract, have been shown effective in simple fistulae in selected patients [15,60,61]. However, studies in this respect are case report which compromise universal adoption of these methods.

## 7. Conclusion

RUF is an uncommon condition mainly induced by the treatment procedures of prostate cancer, as well as other rare causes. As the heterogeneity of etiology, proper pre-operative evaluation is essential for treatment planning. Though absence of comparative studies, an evolving array of cases gradually delineated the technical features of the four main surgical approaches. Taking fistula condition and features of different methods into consideration is vital to select the best approach for repair.

## Conflicts of interest

This study was supported by the National Natural Science Foundation of China (Nos. 31370951 and 81470927), the National Science Foundation for Young Scholars of China (No. 81300579), the Foundation for Young Scholars of Sichuan University (No. 2014SCU04B21) and the Application

Foundation of Committee Organization Department of Sichuan Provincial Party (No. JH2015017).

## References

- [1] Bukowski TP, Chakrabarty A, Powell IJ, Frontera R, Perlmutter AD, Montie JE. Acquired rectourethral fistula: methods of repair. *J Urol* 1995;153:730–3.
- [2] Diao M, Li L, Ye M, Guan KP, Wei YD, Cheng W. Congenital anomaly rectified at birth: one-stage single-incision laparoscopic-assisted anorectoplasty for newborns with anorectal malformations and recto-urethral fistula. *Surg Endosc* 2016;30:5156–64.
- [3] Yamataka A, Lane GJ, Koga H. Laparoscopy-assisted surgery for male imperforate anus with rectourethral fistula. *Pediatr Surg Int* 2013;29:1007–11.
- [4] Lima M, Tursini S, Ruggeri G, Aquino A, Gargano T, De Biagi L, et al. Laparoscopically assisted anorectal pull-through for high imperforate anus: three years' experience. *J Laparoendosc Adv Surg Tech* 2006;16:63–6.
- [5] Hechenbleikner EM, Buckley JC, Wick EC. Acquired rectourethral fistulas in adults: a systematic review of surgical repair techniques and outcomes. *Dis Colon Rectum* 2013;56:374–83.
- [6] Renschler TD, Middleton RG. 30 years of experience with York-mason repair of recto-urinary fistulas. *J Urol* 2003;170:1222–5.
- [7] Singh I, Mittal G, Kumar P, Gangas R. Delayed post-traumatic prostatic-urethrorectal fistula: transperineal rectal sparing repair-point of technique. *Int J Urol* 2006;13:92–4.
- [8] Dafnis G, Wang YH, Borck L. Transsphincteric repair of rectourethral fistulas following laparoscopic radical prostatectomy. *Int J Urol* 2004;11:1047–9.
- [9] Yetisir F, Sarer AE, Acar HZ, Parlak O, Osmanoglu G, Karalova G. Management of recurrent rectourethral fistula by York mason posterior transrectal transsphincteric approach. *Case Rep Urol* 2015;2015:854365.
- [10] Tran H, Flannigan R, Rapoport D. Transperineal approach to complex rectourinary fistulae. *Can Urol Assoc J* 2015;9: E916–20.
- [11] Nicita G, Villari D, Caroassai Grisanti S, Marzocco M, Li Marzi V, Martini A. Minimally invasive transanal repair of rectourethral fistulas. *Eur Urol* 2017;71:133–8.
- [12] Choi JH, Jeon BG, Choi SG, Han EC, Ha HK, Oh HK, et al. Rectourethral fistula: systematic review of and experiences with various surgical treatment methods. *Ann Coloproctol* 2014;30: 35–41.
- [13] Tanwar R, Singh SK, Pawar DS. Rectourethral fistula: a rare complication of injection sclerotherapy. *Urol Ann* 2014;6: 261–3.
- [14] Ruiz-Lopez M, Mera S, Gonzalez-Poveda I, Becerra R, Carrasco J, Toval JA, et al. Fournier's gangrene: a complication of surgical glue treatment for a rectourethral fistula in a patient with human immunodeficiency virus infection. *Colorectal Dis* 2012;14, e203.
- [15] Etienney I, Rabahi N, Cuenod CA, Hoffmann P, Charachon A, Bauer P. Fibrin glue sealing in the treatment of a rectourethral fistula in Crohn's disease: a case report. *Gastroenterol Clin Biol* 2009;33:1094–7.
- [16] Ramírez-Martín D, Jara-Rascón J, Renedo-Villar T, Hernández-Fernández C, Lledó-García E. Rectourethral fistula management. *Curr Urol Rep* 2016;17:22.
- [17] Lane BR, Stein DE, Remzi FH, Strong SA, Fazio VW, Angermeier KW. Management of radiotherapy induced rectourethral fistula. *J Urol* 2006;175:1382–8.
- [18] Chrouser KL, Leibovich BC, Sweat SD, Larson DW, Davis BJ, Tran NV, et al. Urinary fistulas following external radiation or permanent brachytherapy for the treatment of prostate cancer. *J Urol* 2005;173:1953–7.
- [19] Nyam DC, Pemberton JH. Management of iatrogenic rectourethral fistula. *Dis Colon Rectum* 1999;42:994–9.
- [20] Blana A, Walter B, Rogenhofer S, Wieland WF. High-intensity focused ultrasound for the treatment of localized prostate cancer: 5-year experience. *Urology* 2004;63:297–300.
- [21] Chin JL, Pautler SE, Mouraviev V, Touma N, Moore K, Downey DB. Results of salvage cryoablation of the prostate after radiation: identifying predictors of treatment failure and complications. *J Urol* 2001;165:1937–42.
- [22] Gotto GT, Yunis LH, Vora K, Eastham JA, Scardino PT, Rabbani F. Impact of prior prostate radiation on complications after radical prostatectomy. *J Urol* 2010;184:136–42.
- [23] Shah TT, Ahmed H, Kanhabalan A, Lau B, Ghei M, Maraj B, et al. Focal cryotherapy of localized prostate cancer: a systematic review of the literature. *Expert Rev Anticancer Ther* 2014;14:1337–47.
- [24] Marguet C, Raj GV, Brashears JH, Anscher MS, Ludwig K, Mouraviev V, et al. Rectourethral fistula after combination radiotherapy for prostate cancer. *Urology* 2007;69:898–901.
- [25] Heidenreich A, Richter S, Thuer D, Pfister D. Prognostic parameters, complications, and oncologic and functional outcome of salvage radical prostatectomy for locally recurrent prostate cancer after 21st-century radiotherapy. *Eur Urol* 2010;57:437–43.
- [26] Stephenson AJ, Scardino PT, Bianco FJ, DiBlasio CJ, Fearn PA, Eastham JA. Morbidity and functional outcomes of salvage radical prostatectomy for locally recurrent prostate cancer after radiation therapy. *J Urol* 2004;172:2239–43.
- [27] Amling CL, Lerner SE, Martin SK, Slezak JM, Blute ML, Zincke H. Deoxyribonucleic acid ploidy and serum prostate specific antigen predict outcome following salvage prostatectomy for radiation refractory prostate cancer. *J Urol* 1999; 161:857–63.
- [28] Pisansky TM, Kozelsky TF, Myers RP, Hillman DW, Blute ML, Buskirk SJ, et al. Radiotherapy for isolated serum prostate specific antigen elevation after prostatectomy for prostate cancer. *J Urol* 2000;163:845–50.
- [29] Sanchez De Badajoz E, Jimenez Garrido A. Gunshot wound with a bullet lodged in the prostate. *Arch Esp Urol* 2007;60: 117–9.
- [30] A'Court J, Yiannoullou P, Pearce L, Hill J, Donnelly D, Murray D. Rectourethral fistula secondary to a bowel management system. *Intensive Crit Care Nurs* 2014;30:226–30.
- [31] Beatty JD, Witherow R. Diagnostic lessons learnt from a series of enterovesical fistulae. *Colorectal Dis* 2005;7:196.
- [32] Thomas C, Jones J, Jager W, Hampel C, Thuroff JW, Gillitzer R. Incidence, clinical symptoms and management of rectourethral fistulas after radical prostatectomy. *J Urol* 2010; 183:608–12.
- [33] Ghoniem G, Elmissiry M, Weiss E, Langford C, Abdelwahab H, Wexner S. Transperineal repair of complex rectourethral fistula using gracilis muscle flap interposition—can urinary and bowel functions be preserved? *J Urol* 2008;179:1882–6.
- [34] Shin PR, Foley E, Steers WD. Surgical management of rectourinary fistulae. *J Am Coll Surg* 2000;191:547–53.
- [35] Gaston CD, Lee AB. Recto-Urethral fistula: an operation for its cure. *Am J Dig Dis* 1935;2:744–6.
- [36] Crestani A, Dal Moro F. Surgical treatment of rectourinary fistulas: review of the literature. *Urologia* 2015;82:30–5.
- [37] Singla N, Morey AF. Rectourethral fistula reconstruction in elderly patients. *Curr Opin Urol* 2016;26:171–6.
- [38] Keller DS, Aboseif SR, Lesser T, Abbass MA, Tsay AT, Abbas MA. Algorithm-based multidisciplinary treatment approach for rectourethral fistula. *Int J Colorectal Dis* 2015;30:631–8.
- [39] Thompson IM, Marx AC. Conservative therapy of rectourethral fistula: five-year follow-up. *Urology* 1990;35:533–6.
- [40] Topazio L, Perugia C, Finazzi-Agro E. Conservative treatment of a recto-urethral fistula due to salvage HIFU for local

- recurrence of prostate cancer, 5 years after radical prostatectomy and external beam radiotherapy. *BMJ Case Rep* 2012; 2012.
- [41] Mundy AR, Andrich DE. Urorectal fistulae following the treatment of prostate cancer. *BJU Int* 2011;107:1298–303.
- [42] Venkatesan K, Zacharakis E, Andrich DE, Mundy AR. Conservative management of urorectal fistulae. *Urology* 2013;81:1352–6.
- [43] Noldus J, Fernandez S, Huland H. Rectourinary fistula repair using the Latzko technique. *J Urol* 1999;161:1518–20.
- [44] Kilpatrick FR, Mason AY. Post-operative recto-prostatic fistula. *Br J Urol* 1969;41:649–54.
- [45] Hanna JM, Turley R, Castleberry A, Hopkins T, Peterson AC, Mantyh C, et al. Surgical management of complex rectourethral fistulas in irradiated and nonirradiated patients. *Dis Colon Rectum* 2014;57:1105–12.
- [46] Vidal SJ, Reig RC. Urodigestive fistulae: the diagnosis and treatment of 76 cases. *Arch Esp Urol* 1995;48:241–6.
- [47] Kasraeian A, Rozet F, Cathelineau X, Barret E, Galiano M, Vallancien G. Modified York-Mason technique for repair of iatrogenic rectourinary fistula: the montsouris experience. *J Urol* 2009;181:1178–83.
- [48] Lydston VIII GF. A case of enormous prostatic calculus: secondary to traumatic stricture of the perineal urethra; Suppuration about the stone; Secondary abscess in the pelvis; Extensive urethrorectal fistula following perineal section for the calculus; Perineal rectoplasty for the closure of the fistula; Recovery. *Ann Surg* 1904;39:391–5.
- [49] Samplaski MK, Wood HM, Lane BR, Remzi FH, Lucas A, Angermeier KW. Functional and quality-of-life outcomes in patients undergoing transperineal repair with gracilis muscle interposition for complex rectourethral fistula. *Urology* 2011; 77:736–41.
- [50] Voelzke BB, McAninch JW, Breyer BN, Glass AS, Garcia-Aguilar J. Transperineal management for postoperative and radiation rectourethral fistulas. *J Urol* 2013;189:966–71.
- [51] Vanni AJ, Buckley JC, Zinman LN. Management of surgical and radiation induced rectourethral fistulas with an interposition muscle flap and selective buccal mucosal onlay graft. *J Urol* 2010;184:2400–4.
- [52] Harris CR, McAninch JW, Mundy AR, Zinman LN, Jordan GH, Andrich D, et al. Rectourethral fistulas secondary to prostate cancer treatment: management and outcomes from a multi-institutional combined experience. *J Urol* 2017;197:191–4.
- [53] Sotelo R, Mirandolino M, Trujillo G, Garcia A, de Andrade R, Carmona O, et al. Laparoscopic repair of rectourethral fistulas after prostate surgery. *Urology* 2007;70:515–8.
- [54] Linder BJ, Frank I, Dozois EJ, Elliott DS. Robotic transvesical rectourethral fistula repair after a robotic radical prostatectomy. *J Urol* 2013;189:e164–5.
- [55] Jones IT, Fazio VW, Jagelman DG. The use of transanal rectal advancement flaps in the management of fistulas involving the anorectum. *Dis Colon Rectum* 1987;30:919–23.
- [56] Wilbert DM, Buess G, Bichler KH. Combined endoscopic closure of rectourethral fistula. *J Urol* 1996;155:256–8.
- [57] Quinlan M, Cahill R, Keane F, Grainger R, Butler M. Transanal endoscopic microsurgical repair of iatrogenic recto-urethral fistula. *Surgeon* 2005;3:416–7.
- [58] Bochove-Overgaauw DM, Beerlage HP, Bosscha K, Gelderman WA. Transanal endoscopic microsurgery for correction of rectourethral fistulae. *J Endourol* 2006;20:1087–90.
- [59] Atallah SB, DeBeche-Adams TC, Larach S. Transanal minimally invasive surgery for repair of rectourethral fistula. *Dis Colon Rectum* 2014;57:899.
- [60] Dolay K, Aras B, Tuğcu V, Özbay B, Aygün E, Taşçı AI. Combined treatment of Iatrogenic rectourethral fistula with endoscopic fibrin glue application and clipping. *J Endourol* 2007;21:433–6.
- [61] Lee TG, Park SS, Lee SJ. Treatment of a recurrent rectourethral fistula by using transanal rectal flap advancement and fibrin glue: a case report. *J Korean Soc Coloproctol* 2012;28: 165–9.