

CASE REPORT

Metastasis to the breast from colonic adenocarcinoma

Kyoung Tae Noh, Boyoung Oh, Sun Hee Sung¹, Ryung-Ah Lee, Soon Sup Chung, Byung In Moon, Kwang Ho Kim

Departments of Surgery and ¹Pathology, Ewha Womans University School of Medicine, Seoul, Korea

A 63-year-old woman was referred to a breast surgeon with a breast mass discovered incidentally during follow-up study after colon cancer surgery. Invasive adenocarcinoma was revealed on core needle biopsy. Wide excision of the breast including the tumor was performed. On standard histological examination the tumor showed features of moderately differentiated adenocarcinoma. The immunohistochemistry study revealed positive results for cytokeratin (CK)20 and CDX2, but negative for CK7. These are typical characteristics for colon cancer. Considering her history of subtotal colectomy for sigmoid colon cancer, it is presumable that the mass in the breast was of colonic origin, and it was an extremely rare case of metastasis to the breast from primary colorectal neoplasm. Although the instance is rare, clinicians should keep the possibility of breast metastasis from colorectal cancer in mind for early and correct diagnosis.

Key Words: Breast, Neoplasm metastasis, Colon cancer

INTRODUCTION

Metastases to the breast from extramammary malignancies are rare and account for 0.43% of all breast malignancies [1]. Lymphoma, melanoma, sarcoma, lung carcinoma and ovarian tumor are common extramammary primary malignancies that metastasize to the breast [1-3]. Cases of metastasis from primary colorectal neoplasm to the breast is extremely rare. In searching MEDLINE and EMBASE including non-English literature, and hand-searching the references, only 22 cases were identified. We describe the features of metastatic breast cancer from adenocarcinoma of the colon in a 63-year-old woman.

CASE REPORT

A 63-year-old woman was referred to a breast surgeon due to a mass with suspicious metastatic axillary lymph node discovered incidentally on positron emission tomography-computed tomography for follow-up study after colon cancer surgery without other metastatic lesion (Fig. 1). Four years ago, she underwent a subtotal colectomy for stage T3N1M0 sigmoid colon cancer with colonic obstruction and subsequent chemotherapy with 5-fluorouracil and leucovorine. Two years after the operation, a 2.8 cm sized solitary metastatic lung nodule on the right middle lobe was identified on chest computed tomography for follow-up study for which she underwent pulmonary wedge resection, followed by chemotherapy with ox-

Received May 6, 2011, Revised July 28, 2011, Accepted August 9, 2011

Correspondence to: Kwang Ho Kim
Department of Surgery, Ewha Womans University School of Medicine, 911-1 Mok-dong, Yangcheon-gu, Seoul 158-710, Korea
Tel: +82-2-2650-0513, Fax: +82-2-2644-7984, E-mail: eastgate@ewha.ac.kr

© Journal of the Korean Surgical Society is an Open Access Journal. All articles are distributed under the terms of the Creative Commons Attribution Non-Commercial License (<http://creativecommons.org/licenses/by-nc/3.0/>) which permits unrestricted non-commercial use, distribution, and reproduction in any medium, provided the original work is properly cited.

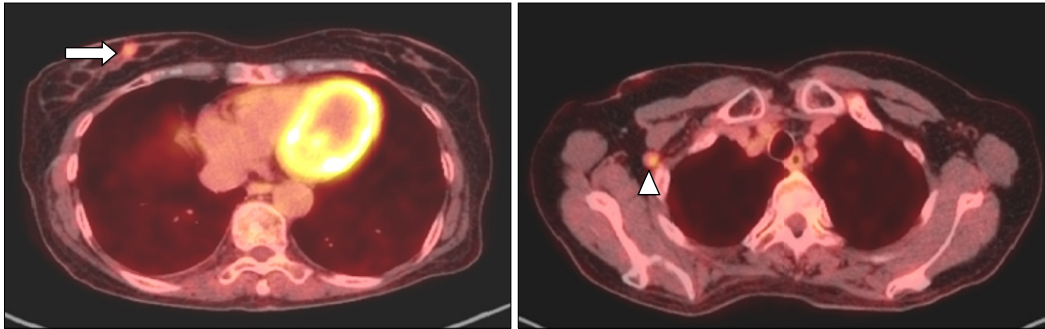


Fig. 1. Mild hypermetabolic lesion was seen in lower inner quadrant of right breast (arrow) and focal hypermetabolic lymph node was seen in right axillary area (arrow head).



Fig. 2. 1.7 cm sized irregular, whitish-gray, firm mass was identified in lower inner portion of right breast, 3.5 cm apart from nipple.

aliplatin and 5-fluorouracil.

Physical examination revealed a 2 cm sized firm nodule in the lower inner quadrant of the right breast without evidence of axillary or supraclavicular lymphadenopathy. The contralateral breast and axilla were normal.

The mass was not identified on mammography, but ultrasonography showed 1.1 cm sized mass in the lower inner quadrant of the right breast without enlarged lymph node in the ipsilateral axilla. Sonography guided core needle biopsy of the breast mass revealed invasive adenocarcinoma. Serum tumor markers were all in normal ranges (carcinoembryonic antigen 4.2 ng/mL, carbohydrate antigen 15-3 6.2 U/mL). Subsequent magnetic resonance imaging showed 1.8 cm sized ill-defined irregular shaped enhancing mass in the lower inner quadrant of the right breast and enlarged lymph node at the ipsilateral axilla compatible with a nodule suspicious for metastasis. Breast specific gamma imaging using ^{99m}Tc -MIBI showed a lesion with increased uptake in the lower inner portion of the right breast with no lesion uptake in the axilla.

Wide excision of the tumor and sentinel lymph node biopsy was performed (Fig. 2).

On histopathological examination, the tumor cells in

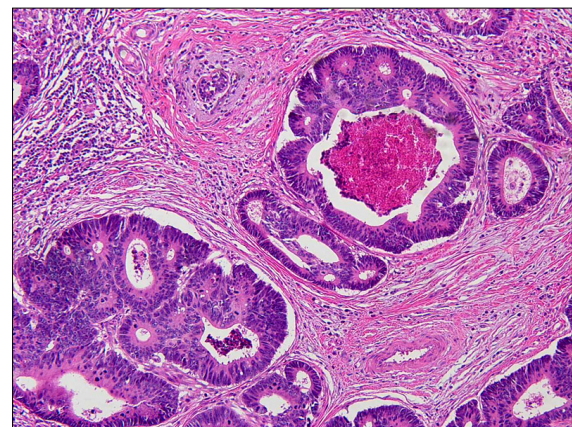


Fig. 3. Cuboidal to columnar tumor cells with eosinophilic cytoplasm and pseudostratification were seen on hematoxylin-eosin stain ($\times 100$).

the breast mass were cuboidal to columnar with eosinophilic cytoplasm and pseudostratification, compatible with the features of adenocarcinoma of colorectal origin (Fig. 3). The harvested sentinel lymph node did not contain tumor cells.

Immunohistochemical study revealed the following results: tumor cells were strongly positive for CDX2, cytokeratin (CK)20 and negative for CK7, thyroid tran-

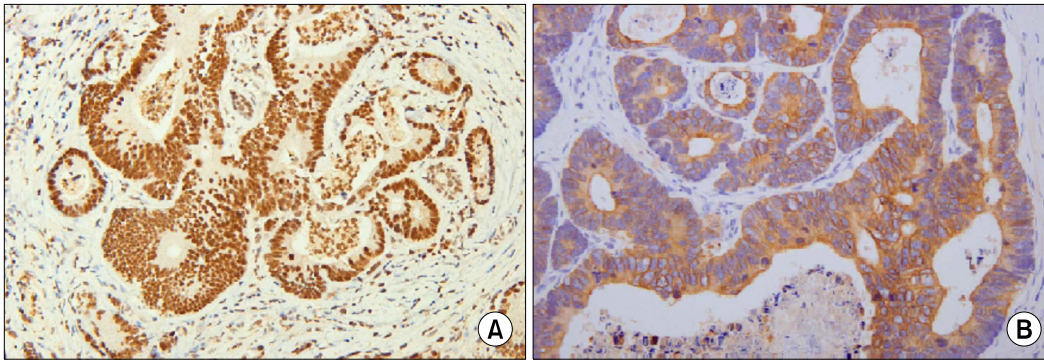


Fig. 4. Immunohistochemistry showed neoplastic cells were positive for CDX2 immunostaining (A, $\times 200$) and cytokeratin 20 immunostaining (B, $\times 200$).

scription factor-1, estrogen receptor, progesterone receptor, c-erbB2 (Fig. 4). These findings are consistent with metastatic adenocarcinoma of the colon or rectum.

Currently, she is receiving systemic chemotherapy with irinotecan and 5-fluorouracil.

DISCUSSION

Primary breast cancer is one of the most common malignancies and leading cause of death from malignant disease in women. A malignant mass in the breast can easily be misinterpreted as breast cancer and inappropriate surgical intervention could be carried out. Although there are few instances of breast metastasis from colorectal malignancy, correct diagnosis is crucial to avoid unnecessary surgical intervention.

Generally, metastases to the breast from extramammary malignancies are characterized by rapidly growing, mobile masses that are easily palpable but do not cause overlying skin or nipple retraction, or bloody nipple discharge [4,5]. Core biopsy allows histological assessment of the tissue, helping in identifying the origin of the carcinoma. On the histologic finding, the periductal and perilobular location of the tumor with the absence of *in situ* ductal carcinoma in the surrounding breast specimen favor a metastasis [4,5]. Immunohistochemistry enables a more confident differentiation between a primary breast adenocarcinoma and a colorectal adenocarcinoma metastasis to the breast. For our patient, diagnosis was finally reached after immunohistochemistry finding. The majority of colorectal carcinomas are usually CK7-negative and CK20-positive,

while the majority of primary breast carcinomas is CK7-positive and CK20-negative [6]. And the positive immunostaining for CDX2 is a highly sensitive and specific marker of colorectal carcinoma [7]. Our case showed these findings as well; tumor cells were positive for CDX2, CK20 and negative for CK7. Recently, some authors have suggested that the expression of CK20 can be identified in primary breast cancer in contrast to the conventional immunohistochemistry results. So, clinicians and pathologists should examine multiple immunohistochemistry markers and combine them as an approach for final diagnosis [8].

According to recent reports, the management of metastatic breast mass from colorectal adenocarcinoma should be diagnostic and palliative. Barthelmes et al. [9] advocated that surgical excision should be avoided in the view of short life expectancy and risk of seeding to the skin. Fernández de Bobadilla et al. [10] suggested that excisional biopsy was usually appropriate and provided adequate local control. If the diagnosis for the breast mass is unclear, unnecessary intervention, for example mastectomy or lymph node dissection of axilla, can be performed. Therefore, when breast mass is identified incidentally on radiologic study during follow-up after operation for colorectal carcinoma, clinicians should keep the possibility of breast metastasis from colorectal adenocarcinoma in mind. Additionally, periodical examination of the breast after colorectal cancer surgery may be helpful to detect the metastasis early.

CONFLICTS OF INTEREST

No potential conflict of interest relevant to this article was reported.

REFERENCES

1. Georgiannos SN, Chin J, Goode AW, Sheaff M. Secondary neoplasms of the breast: a survey of the 20th Century. *Cancer* 2001;92:2259-66.
2. Williams SA, Ehlers RA 2nd, Hunt KK, Yi M, Kuerer HM, Singletary SE, et al. Metastases to the breast from non-breast solid neoplasms: presentation and determinants of survival. *Cancer* 2007;110:731-7.
3. Vizcaíno I, Torregrosa A, Higuera V, Morote V, Cremades A, Torres V, et al. Metastasis to the breast from extramammary malignancies: a report of four cases and a review of literature. *Eur Radiol* 2001;11:1659-65.
4. Vergier B, Trojani M, de Mascarel I, Coindre JM, Le Treut A. Metastases to the breast: differential diagnosis from primary breast carcinoma. *J Surg Oncol* 1991;48:112-6.
5. Hajdu SI, Urban JA. Cancers metastatic to the breast. *Cancer* 1972;29:1691-6.
6. Kende AI, Carr NJ, Sobin LH. Expression of cytokeratins 7 and 20 in carcinomas of the gastrointestinal tract. *Histopathology* 2003;42:137-40.
7. Werling RW, Yaziji H, Bacchi CE, Gown AM. CDX2, a highly sensitive and specific marker of adenocarcinomas of intestinal origin: an immunohistochemical survey of 476 primary and metastatic carcinomas. *Am J Surg Pathol* 2003; 27:303-10.
8. Wang SM, Huang DM, Li B, Ruan JD. Association of CK20 expression with the progression, metastasis and prognosis of breast cancer. *Xi Bao Yu Fen Zi Mian Yi Xue Za Zhi* 2009;25:706-7.
9. Barthelmes L, Simpson JS, Douglas-Jones AG, Sweetland HM. Metastasis of primary colon cancer to the breast-leave well alone. *Breast Care* 2010;5:23-5.
10. Fernández de Bobadilla L, García Villanueva A, Collado M, de Juan A, Rojo R, Pérez J, et al. Breast metastasis of primary colon cancer. *Rev Esp Enferm Dig* 2004;96:415-9.