

Collision tumor in form of primary adenocarcinoma and neuroendocrine carcinoma of the duodenum

Lan Peng,¹ Roderich E. Schwarz²

¹Department of Pathology and

²Department of Surgery, Division of Surgical Oncology, UT Southwestern Medical Center, Dallas, Texas, USA

Abstract

Collision tumor is a rare phenomenon characterized by coexistence of completely distinct and independent tumors at the same body location. Collision tumors have been reported in different sites. However, they are extremely uncommon in the duodenum. We report the case of a 52-year old man with a collision tumor in the third portion of the duodenum with two distinct tumors of primary adenocarcinoma and neuroendocrine carcinoma, and both tumors coexisting within a single metastatic lymph node. Immunohistochemistry studies were performed to conclude that this was a case of collision cancer. To the best of our knowledge, this is the first collision tumor case reported to date at this location, and the first report of lymph node with a collision metastasis from a collision tumor. Such tumor is very rare and may thus provide diagnostic challenges. This report also provides a review of other cases on duodenal collision tumors.

Introduction

Collision tumor is a well documented but uncommon phenomenon characterized by coexistence of two completely distinct and independent tumors at the same site. The two morphologically separate tumors are sharply demarcated from each other in the same site. This entity is distinct from neoplasms demonstrating heterologous or mixed elements.

Various collision tumors have been documented in different organs of the body. Previously documented cases of collision tumor in the gastrointestinal tract include gastric collision tumor such as an unusual combination of adenocarcinoma and immature neuroepitheliomatous teratoma¹ in the stomach, collision of Epstein-Barr virus-associated gastric carcinoma and primary gastric extranodal marginal zone lymphoma,² gastrointestinal stromal tumor and gastric adenocarcinoma collision tumors,³ gastric collision tumor of large cell neuroendocrine carcinoma and adenocarcinoma,⁴ and mixed

adenocarcinoma-carcinoid in the appendix,⁵ a rare combination of an adenocarcinoma and small cell neuroendocrine tumor in the ileum,⁶ adenoma-carcinoid tumors of the colon,⁷ and collision tumor of the ampulla of Vater with carcinoid and adenocarcinoma components.^{8,9}

Duodenal adenocarcinoma in a site other than around the ampulla of Vater is uncommon, and the presence of a collision tumor in this location is rather rare. No collision tumor from the duodenum other than the ampulla of Vater has been reported to date. Our case involves a patient with distinct adenocarcinoma and neuroendocrine carcinoma located in the third portion of the duodenum 4.5 cm distal to the ampulla of Vater. Grossly, the duodenal mass was a 3 cm-sized ulcerative fungating lesion. Microscopically, two separated tumors were recognized. The lineages of both tumors were confirmed by immunohistochemistry. Such collision tumor is very rare and may thus provide diagnostic challenges. Clinicians and pathologists should be aware of such an association in order to make a correct diagnosis and initiate the proper treatment.

Case Report

A previously healthy 52 year-old man with a family history of pancreatic cancer developed progressive daily vomiting over six months prior to presentation. He had a normal appetite and could tolerate a regular diet, but reported increasing postprandial vomiting. He has also noted a 125-lb weight loss over the past 9 months. On endoscopy he was found to have a near-complete obstructing mass at the third portion of the duodenum, but biopsies failed to confirm a neoplastic condition. Computed tomography scan demonstrated duodenal obstruction and abnormal para-duodenal lymph nodes (Figure 1A). Intraoperatively the findings were consistent with a mass of approximately 3 cm in size, but it was somewhat unclear whether this was an extra-duodenal mass involving the duodenum secondarily, or a duodenal mass involving the uncinate process of the pancreas. The mass was completely resected via pylorus-sparing pancreatoduodenectomy. On pathological examination, this 3 cm ulcerated tumor (Figure 1B) was located in the third portion of duodenum 4.5 cm distal to ampulla of Vater, deeper located to it is an independent 1 cm distinctive nodule (Figure 1C).

Microscopically, the main tumor showed poorly differentiated adenocarcinoma morphology (Figure 2A) that had infiltrated into subserosal adipose tissue; the other lesion in the same location located deeper from the adenocarcinoma described above showed neuroendocrine morphology, such as nests and trabeculae with variable amounts of eosinophilic cytoplasm, indicat-

Correspondence: Lan Peng, Department of pathology, UT Southwestern Medical Center, 5909 Harry Hines Boulevard, Dallas TX, USA.
Tel. +1.214.645.3711 - Fax: +1.214.645.3537.
E-mail: lan.peng@utsouthwestern.edu

Key words: collision tumor, collision metastasis, the third portion of duodenum.

Conflict of interests: the authors report no conflicts of interest.

Received for publication: 16 December 2011.

Accepted for publication: 23 January 2012.

This work is licensed under a Creative Commons Attribution NonCommercial 3.0 License (CC BY-NC 3.0).

©Copyright L. Peng et al., 2012
Licensee PAGEPress, Italy
Rare Tumors 2012; 4:e20
doi:10.4081/rt.2012.e20

ing a completely distinct and independent neuroendocrine carcinoma (Figure 3A). Histologically, the pancreas was not involved with either tumor. Three positive lymph nodes were identified out of a total of forty. One of them demonstrated coexistent metastatic adenocarcinoma and neuroendocrine carcinoma (Figure 4A). The immunohistochemical characteristics were analyzed to determine whether the origins of the 2 cancers were different or not. The adenocarcinoma neoplastic cells revealed expression of CK7, CK20 and Cd \times 2 but no expression of neuroendocrine markers such as CD56, chromogranin and synaptophysin (Figure 2B, C, D). The tumor cells in the independent 1 cm tumor nodule show strong neuroendocrine marker expression including CD56, chromogranin and synaptophysin, but negativity for CK7, CK20 and Cd \times 2 (Figure 3B,C,D). The immunostains were also done on the involved lymph node which confirmed the double metastasis (Figure 4B,C). This phenomenon is very rare and can be referred to as *collision metastasis*. The other two lymph nodes were positive for neuroendocrine carcinoma. As a result, it was concluded that this was a case of collision cancer of primary duodenal adenocarcinoma and neuroendocrine carcinoma with collision metastasis into one lymph node. The patient has recovered well from his operation, and is currently symptom-free.

Discussion

Before the present case, a total of four reported cases of duodenal collision tumor were found in the MedLine-listed literature. Our literature review has purposely been limit-

ed to collision tumors of duodenum excluding those from colorectal, gastric, appendiceal and other parts of the gastrointestinal tracts. The clinicopathologic features of these cases are summarized in Table 1.⁸⁻¹¹

Conventional explorations usually do not confirm the coexistence of both tumors, as these findings are frequently made incidentally during histopathologic examination of the specimen. Given their extreme rarity in this location and the nature of collision tumors, it is of certain diagnostic benefit to extensively examine and section the tumor for histologic evaluation, and distinguish collision tumor from the more commonly encountered neoplasms demonstrating heterologous differentiated elements or mixed elements.

Indeed, this case could easily have been mis-considered as an *adenocarcinoma with neuroendocrine features* given the rarity of collision tumors in this location, and one may even completely miss the concurrent distinct and independent neuroendocrine tumor component, especially if only a limited examination and sectioning of the tumor are performed for histologic evaluation.

Two main features that are important in the diagnosis of collision tumor rather than neoplasms demonstrating mixed elements include: i) two distinctive and spatially independent tumor components macroscopically in the same location, and ii) demarcated morphology and immuno-expression patterns among the two tumors microscopically. Morphological and immunohistochemical examinations will show that the two components have a clear-cut distinction, and they have no intervening intermediate cell population.

Clinical implications of this condition and the mechanism responsible for the tumor formation of such an unusual constellation remain unclear. Mutual factors of carcinogenic initiation or progression for either tumor component can be speculated upon, but are unknown. In addition, the collision tumor encountered provided us with the curiosity finding of simultaneous and apparently independent lymphatic metastatic progression mechanisms, too. Since this is apparently the first such case of collision tumor arising in the third portion of duodenum, further study of additional cases and additional

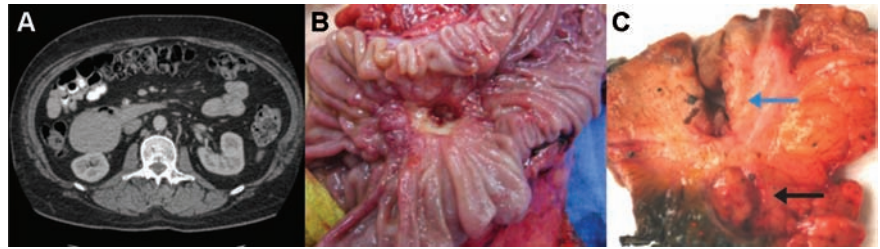

Figure 1. A) Computed tomography scan showing the level of duodenal obstruction, and an abnormal paraduodenal lymph node; B) Macroscopic findings: an ulcerated tumor (3.0×2.5×1.4 cm) is located in the third portion of duodenum about 4.5 cm distal from ampulla of Vater of duodenum; C) Macroscopic findings: cross-section of the ulcerated tumor (blue arrow) and in the same location deeper from the tumor above, a completely distinct and independent 1 cm tumor (black arrow) deep in subserosa.

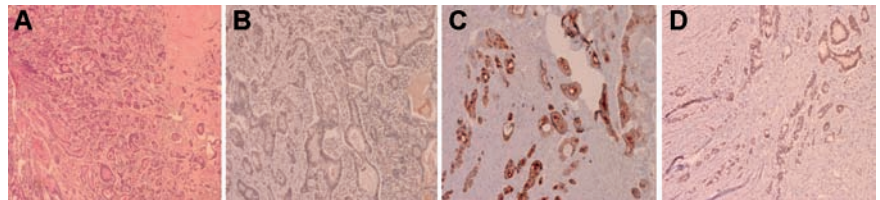


Figure 2. Histological photomicrograph of the main tumor showing adenocarcinoma morphology (A), and immunohistochemically tumor cells with complete negativity for synaptophysin (B), but with strong cytoplasmic and membrane reactivity for CK7 (C) and nuclear stain for cdx2 (D).

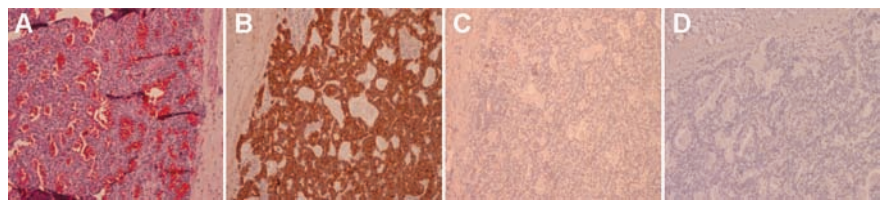


Figure 3. Histological photomicrograph of the independent 1 cm tumor composed of nests of small cells with uniform round nuclei. The nuclei of the neoplastic cells have classic salt and pepper chromatin (A), immunohistochemically the tumor cells are diffuse and strong positivity for synaptophysin (B), negative for CK7 (C) and cdx2 (D).

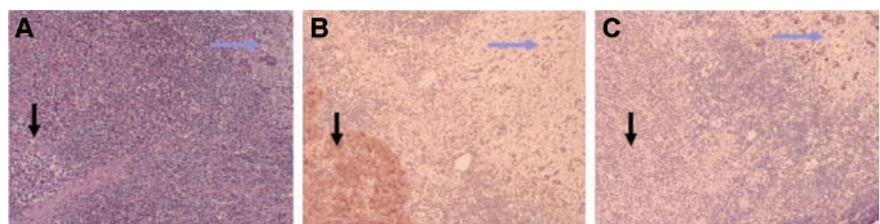


Figure 4. A) Collision metastasis in a single lymph node: Black arrow points to neuroendocrine carcinoma; blue arrow marks adenocarcinoma; B) Immunohistochemical study for synaptophysin: positive for metastatic neuroendocrine tumor; negative for the adenocarcinoma metastasis; C) Immunohistochemical study for cdx2: negative for metastatic neuroendocrine, positive for the adenocarcinoma metastasis.

Table 1. Clinicopathologic features of current and previous reported collision tumor in duodenum.

Author and year	Age/Sex	Location/size	Histopathology
Marco <i>et al.</i> 2007	64/M	Duodenal wall and head of pancreas ⁸	Duodenal carcinoid (1 cm) and adenocarcinoma of head of pancreas (3 cm)
Williams <i>et al.</i> 1997	58/M	Ampulla of Vater ⁹	Carcinoid tumor (0.6 cm) and adenocarcinoma (0.6 cm)
Varikatt <i>et al.</i> 2006	37/F	Ampulla of Vater ¹⁰	Somatostatinoma (3.5 cm) and neurofibroma (2.0 cm)
Hirono <i>et al.</i> 2008	75/M	Ampulla of Vater and proximal bile duct ¹¹	The ampulla of Vater shows a papillo-tubular carcinoma with a marked production of mucin suggesting an intestinal type of ampullary adenocarcinoma, and well differentiated carcinoma of bile duct
Present case	52/M	Third portion of duodenum	Primary adenocarcinoma (3.0 cm) and neuroendocrine carcinoma of duodenum (1 cm)

long-term follow-up will likely be necessary to better understand the clinical behavior of such tumors occurring in this unusual location. We suspect that the recurrence risk of the tumor encountered will most likely be primarily influenced by the biologic behavior of the more aggressive component, *i.e.* the duodenal adenocarcinoma. Nevertheless, having identified two separate invasive neoplastic processes will have an influence on postoperative treatment and follow-up decisions.

References

1. Govender D, Serra S, Chetty R. Collision tumor of the stomach : an unusual combination of adenocarcinoma and immature “neuroepitheliomatous” teratoma. *Int J Surg Pathol* 2011 Dec 5. [Epub ahead of print].
2. Akiba J, Nakane T, Arakawa F, et al. Collision of EBV-associated gastric carcinoma and primary gastric extranodal marginal zone lymphoma of mucosa-associated lymphoid tissue in the remnant stomach. *Pathol Int* 2010;60:102-6.
3. Kleist B, Lasota J, Miettinen M. Gastrointestinal stromal tumor and gastric adenocarcinoma collision tumors. *Hum Pathol* 2010;41:1034-9.
4. Jang KY, Moon WS, Lee H, et al. Gastric collision tumor of large cell neuroendocrine carcinoma and adenocarcinoma-a case report. *Pathol Res Pract* 2010;206:387-90.
5. Singh NG, Mannan AA, Kahvic M. Mixed adenocarcinoma-carcinoid (collision tumor) of the appendix. *Nur AM Med Princ Pract* 2011;20:384-6.
6. Van Kerkhóve F, Coenegrachts K, Steyaert L, et al. Collision tumor in the ileum: a rare combination of an adenocarcinoma and small cell neuroendocrine tumor. *JBR-BTR* 2006;89:258-60.
7. Lyda MH, Fenoglio-Preiser CM. Adenocarcinoid tumors of the colon. *Arch Pathol Lab Med* 1998;122:262-5.
8. Ferrando Marco J, Pallas Regueira A, Moro Valdezate D, Fernández Martínez C. Collision tumor of the ampulla of Vater: carcinoid and adenocarcinoma. *Rev Esp Enferm Dig* 2007;99:235-8.
9. Williams IM, Williams NW, Stock D, Foster ME. Collision tumour of the ampulla of Vater: carcinoid and adenocarcinoma. *HPB Surg* 1997;10:241-4.
10. Varikatt W, Yong JL, Killingsworth MC. Somatostatinoma: collision with neurofibroma and ultrastructural features. *Histol Histopathol* 2006;21:1171-80.
11. Hirono S, Tani M, Terasawa H, et al. A collision tumor composed of cancers of the bile duct and ampulla of Vater-immunohistochemical analysis of a rare entity of double cancer. *Hepatogastroenterology* 2008;55:861-4.