

Frugal model for scleral fixated intraocular lens simulation

Dear Editor,

Scleral fixated intraocular lens (SFIOL) has been the mode of optical rehabilitation in cases of aphakia without adequate capsular support. The results of scleral fixated IOLs have been encouraging in both adult and pediatric populations.^[1,2] There are numerous surgical techniques for SFIOL surgery, a simulator for the same is rarely available for residents/surgeons to practice. Here we introduce a simple model simulator for practicing the basic steps in SFIOL.

Materials required

1. Ping pong ball
2. 2 mm*2 mm rubber pads (cut out from rubber tube)
3. Staple Pin-(No 10.) crown width 9.3 mm, leg -4 mm.

A Ping-Pong ball (Table tennis) made of plastic material is taken. A 10 mm hole is made in the ball using a knife. This hole acts as the anterior chamber. The 2 rubber cubes are pasted using superglue at a distance of 1.5 mm from the limbus on diametrically opposite points. A staple pin with a length of 9 mm is pinned 2 mm away from the limbus. The whole apparatus is mounted on a holder (thermocool with space cut to fit the ball) [Fig. 1a].

Surgical simulation

Materials required for surgical simulation include 6.5 mm rigid PMMA lens, 23G needle with a syringe, 26-G needle with the syringe for haptic exteriorization, 23 G forceps, IOL holding forceps. Refer attached video 1 for surgical steps.

Steps

Fig. 1 shows the intraoperative steps while Fig. 2 shows the major steps as seen from outside.

1. Scleral pockets are made in the rubber pads using a 23 G trocar. Also adjacent to the scleral pocket 23 G sclerotomy is made [Fig. 1b]
2. The lens is held using forceps and advanced to pupillary

area through the staple pin which acts as the scleral tunnel [Fig. 1c]

3. The leading haptic is exteriorized using a forceps [Figs. 1d and 2a] or by threading into a 26 G needle [Figs. 1e and 2b]
4. The trailing haptic is exteriorized using a forceps [Figs. 1f, 1g, and 2d]
5. The haptics are tucked into the created scleral pockets [Fig. 1h], to obtain a centered scleral fixated IOL [Fig. 1i].

This technique can be repeated multiple times using the same model.

Gabor and Pallavidis described the original surgical technique used for creating this simulator.^[3] In this technique, the scleral tunnels have been demonstrated to be leak free even without glue.^[4] Also since the haptics are inside the sclera there is lesser chances of conjunctival erosion due to the haptics.

This model enables the surgeon to practice insertion of IOL, grasping the leading haptic, exteriorizing it via sclerotomy. This will also enhance hand-eye coordination and improve bidextrous surgical maneuvers. The needle assisted exteriorization can also be practiced with this model.^[5] The externalizing leading haptic may be stabilized using a rubber stopper, to prevent inadvertent slippage while manipulating the trailing haptic [Fig. 2c]. After this step the trailing haptic is exteriorized directly using a forceps. The lens haptics are tucked into the rubber pads and adjusted accordingly for centration. The lens centration in this technique is adjusted by titrating the amount of intrascleral haptic length. The Yamane technique of SFIOL, where haptics are cauterized and left sub conjunctival may also be performed using the same model.^[6]

The limitations include the absence of corneal tissue, which could have given more originality for the model. Also it would have enabled formation of a closed anterior chamber. There is also lack of orbital adnexal structures which can limit the hand movements of the surgeon. However, this drawback can be overcome by placing the model over a mannequin head.

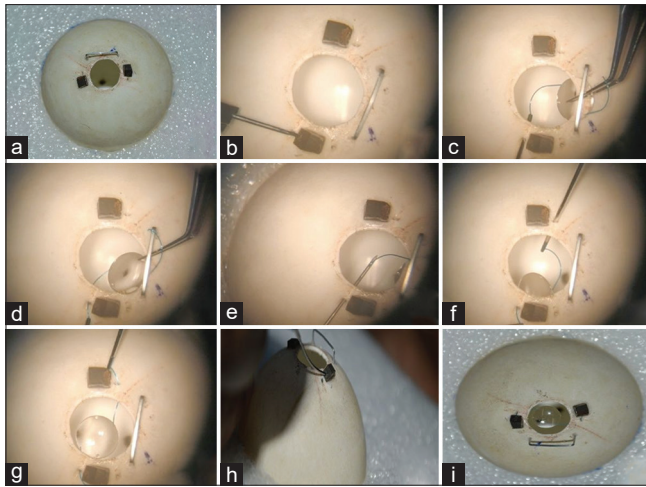


Figure 1: Microscope view of cardinal surgical steps: (a) SFIOL simulator model, (b) making scleral pockets, (c) inserting the lens, (d) externalizing the leading haptic, (e) 26-G needle assisted externalization, (f) grasping the trailing haptic, (g) externalizing the trailing haptic, (h) haptic tucking, and (i) Final scleral fixated IOL

Even though, this simple model can enable surgeon to practice cardinal steps of intrascleral fixation of IOL. It can fasten the acquiring of surgical skills among the trainees.

Financial support and sponsorship

Nil.

Conflicts of interest

There are no conflicts of interest.

*Sourav Damodaran, Naresh Babu, Sagnik Sen,
Dhipak Arthur, Kim Ramasamy*

Department of Vitreoretina Services, Aravind Eye Hospital and Postgraduate Institute of Ophthalmology, Madurai, Tamil Nadu, India

Correspondence to: Dr. Sourav Damodaran,
Aravind Eye Hospital and Postgraduate Institute of Ophthalmology,
Anna Nagar, Madurai, Tamil Nadu - 625 020, India.
E-mail: sou.sight@gmail.com

References

1. Vote BJ, Tranos P, Bunce C, Charteris DG, Da Cruz L. Long-term outcome of combined pars plana vitrectomy and scleral fixated sutured posterior chamber intraocular lens implantation. *Am J Ophthalmol* 2006;141:308-12.
2. NB K, Kohli P, Pangtey BPS, Ramasamy K. Evaluation of sutureless, glueless, flapless, intrascleral fixated posterior chamber intraocular lens in children with ectopia lentis. *J Ophthalmol* 2018;2018:3212740.
3. Gabor SG, Pavlidis MM. Sutureless intrascleral posterior chamber intraocular lens fixation. *J Cataract Refract Surg* 2007;33:1851-4.

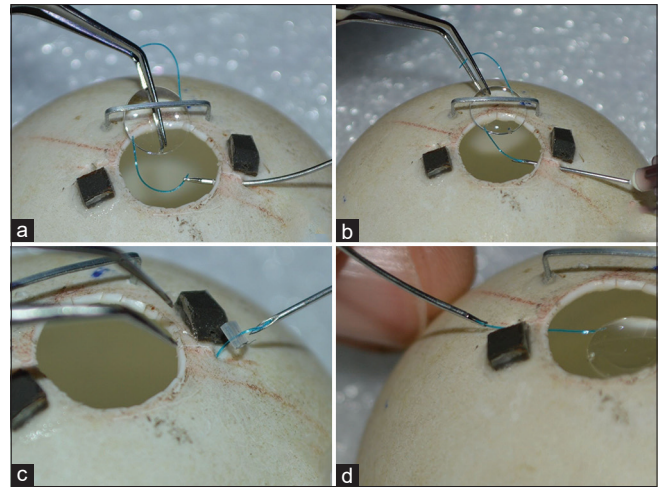


Figure 2: Surgical steps viewed from outside: (a) inserting lens and grasping the leading haptic, (b) needle assisted externalization of leading haptic, (c) using a rubber stopper to prevent haptic slippage, (d) externalization of trailing haptic

4. Scharioth GB, Prasad S, Georgalas I, Tataru C, Pavlidis M. Intermediate results of sutureless intrascleral posterior chamber intraocular lens fixation. *J Cataract Refract Surg* 2010;36:254-9.
5. Baskaran P, Ganne P, Bhandari S, Ramakrishnan S, Venkatesh R, Gireesh P. Extraocular needle- guided haptic insertion technique of scleral fixation intraocular lens surgeries (X-NIT). *Indian J Ophthalmol* 2017;65:747-50.
6. Yamane S, Sato S, Maruyama-Inoue M, Kadonosono K. Flanged intrascleral intraocular lens fixation with double-needle technique. *Ophthalmology* 2017;124:1136-42.

This is an open access journal, and articles are distributed under the terms of the Creative Commons Attribution-NonCommercial-ShareAlike 4.0 License, which allows others to remix, tweak, and build upon the work non-commercially, as long as appropriate credit is given and the new creations are licensed under the identical terms.

Video Available on: www.ijo.in

Access this article online

Quick Response Code:



Website:

www.ijo.in

DOI:

10.4103/ijo.IJO_2524_20

Cite this article as: Damodaran S, Babu N, Sen S, Arthur D, Ramasamy K. Frugal model for SFIOL simulation. *Indian J Ophthalmol* 2021;69:463-4.

© 2021 Indian Journal of Ophthalmology | Published by Wolters Kluwer -Medknow