

Dual mobility cups for preventing early hip arthroplasty dislocation in patients at risk: experience in a county hospital

Sebastian S. Mukka, Sarwar S. Mahmood, Göran O. Sjärdén, Arkan S. Sayed-Noor

Department of Orthopaedics, Sundsvall Teaching Hospital; Department of Surgical and Perioperative Science, Umeå University, Sweden

Abstract

Dislocation remains a major concern after hip arthroplasty. We asked whether dual mobility cups (DMC) would improve early hip stability in patients with high risk of dislocation. We followed 34 patients (21 females, 13 males) treated between 2009 and 2012 with cemented DMC for hip revisions caused recurrent hip prosthetic dislocation or as a primary procedure in patients with high risk of instability. Functional outcome and quality of life were evaluated using Harris Hip Score and EQ-5D respectively. We found that the cemented DMC gave stability in 94%. Seven patients (20%) were re-operated due to infection. One patient sustained a periprosthetic fracture. At follow-up (6 to 36 months, mean 18), the mean Harris hip score was 67 (standard deviation: 14) and mean EQ-5D was 0.76 (standard deviation: 0.12). We concluded that treating patients with high risk of dislocation with DMC can give good stability. However, complications such as postoperative infection can be frequent and should be managed carefully.

Introduction

Hip arthroplasty is associated with improved function and quality of life. However, implant dislocation, periprosthetic infection and aseptic loosening remain major concerns. Early recurrent dislocation may lead to revision surgery and is associated with high risk of complications. The etiology of implant instability is multifactorial. Old age, female gender, previous hip surgery, malpositioned implant components, postero-lateral surgical approach and limited caseload volume are all associated with increased risk for instability. Another important factor is the indication for arthroplasty *i.e.* the incidence of dislocation after femoral neck fracture is between 2% and 22% and after primary arthroplasty 1.7% and 3.9%.¹⁻⁴ After revision

surgery the incidence of dislocation increases up to 35%.^{5,6}

Several techniques have been advocated to address the issue of early instability. Trochanteric advancement, modular components, large prosthetic heads, constrained liners, constrained and unconstrained dual mobility (tri-polar) components are some modalities used to reduce the dislocation rate.⁷ The unconstrained dual mobility cups (DMCs) have been used to prevent dislocations in patients at risk, such as in prosthetic revision surgery or in primary procedures for osteoarthritis or fracture of femoral neck in patients with dementia or neuromuscular diseases.⁸⁻¹³ These studies have shown encouraging results. Nevertheless, most of these outcome reports come from university hospitals with high caseloads or by authors associated with the originating centers.^{9,12-14}

The aim of the present study was to evaluate the early results and complications mainly dislocation rate in a group of high-risk patients treated with DMCs. We would like to report our county hospital experience with relatively low caseload.

Materials and Methods

Settings and location

Thirty-four consecutive patients (21 females, 13 males) with ages ranged from 58 to 90 years (mean: 75.7) were operated with DMCs between January 2009 and May 2012 at our hospital. Indications for surgery are listed in Table 1. Figure 1A and B show one of the cases of a total hip prosthesis which was presented with recurrent dislocation.

The American Society of Anesthesiology (ASA) score of the treated patients was I in 3%, II in 47%, III in 47% and IV in 3%.¹⁵

Our hospital is a county hospital with a catchment area of approximately 150,000 inhabitants. Annually, we perform about 150-200 primary hip replacements for primary or secondary osteoarthritis (10 surgeons), 40-50 hip revisions (3 surgeons) and 80-100 hip replacements for femoral neck fractures (12 surgeons). The rate of dislocation after hip replacement for primary and secondary osteoarthritis is about 2-3% while after femoral neck fracture is about 10%. The overall risk of infection after hip replacement in our unit is about 2-3%.

Surgical procedure

All procedures were performed using a cemented dual mobility acetabular component Advantage® (Biomet, Valence, France) (Figure 2) and a cemented SP II Lubinus stem (Link, Warsaw, Germany). At the operating theatre

Correspondence: Arkan S. Sayed-Noor, Department of Orthopaedics, Sundsvall Teaching Hospital; Department of Surgical and Perioperative Science, Umeå University, 901 85 Umeå, Sweden. Tel. +46.739688466 - Fax: +46.60181751 E-mail: arkansam@yahoo.com

Key words: dual mobility cup, hip arthroplasty, dislocation, stability, outcome, complications.

Contributions: SSMu, data collection and analysis, literature search, writing manuscript; SSMa, literature search, writing manuscript; GOS, study design, supervising and reviewing manuscript; ASSN, study design, data analysis, supervising and reviewing manuscript.

Acknowledgements: Registration: Clinicaltrials.gov: NCT01644227.

Conflict of interests: the authors declare no potential conflict of interests.

Received for publication: 18 January 2013.

Revision received: 19 April 2013.

Accepted for publication: 21 April 2013.

This work is licensed under a Creative Commons Attribution NonCommercial 3.0 License (CC BY-NC 3.0).

©Copyright S.S. Mukka et al., 2013

Licensee PAGEPress, Italy

Orthopedic Reviews 2013; 5:e10

doi:10.4081/or.2013.e10

surgery was performed under laminar airflow with sterile disposable draping and plastic adhesive coverings over the incisional area. The postero-lateral approach with repair of the short external rotators and capsule was used in all patients.¹⁶ Thrombo-prophylaxis with subcutaneous high molecular weight heparin (Fragmin® Pfizer AB, Sweden) 5000 IU daily was given for 7 days postoperatively. Antibiotic prophylaxis with three doses of 2 grams Cloxacillin intravenously (Ekvacillin® Meda AB, Sweden) is given according to the routine of the department starting with doses at 0.5 hours before and 1.5 and 9.5 hours after the start of surgery. Under the supervision of a physiotherapist, all patients were mobilized to full weight bearing on the first post-operative week.

Follow-up

Follow-up of patients was conducted 6-36 months (mean 18 months) postoperatively by a colleague who did not participate in the management of any of the patients included.

Primary end point

The primary end point was the incidence of early postoperative dislocation.

We identified re-operations for postoperative dislocations (minimal of 6 months follow-

up) such as closed or open reduction. We also used the Swedish Hip Arthroplasty Register to search for patients who had undergone re-operation elsewhere.

Secondary end points

The secondary end points were postoperative complications other than dislocation such as infections and periprosthetic fractures, the functional outcome evaluated with Harris hip score and quality of life evaluated with EQ-5D. For the postoperative complications, we reviewed re-operations for superficial and deep infections and periprosthetic fractures. Furthermore, postoperative visits for other complications such as wound infection were reported. We used a unique Swedish civic registration number for all patients to verify mortality in the Swedish Death Register.

Ethics

The study was conducted in accordance with the ethical principles of the Helsinki declaration. The regional ethical committee at Umeå University approved this study (Dnr: 2012-260-31M).

Results

The postoperative radiographs of the operated DMCs showed a mean cup inclination of 47 degrees (SD 9) and an anteversion of 22 degrees (SD 10).

Primary end point

Two patients (6%) were re-operated with open reduction for dislocation that occurred between the metal cup and polyethylene head. One patient had both the cup and stem positioned with extreme anteversion (Figure 3A, B) and the implant dislocated anteriorly. The other patient dislocated after a fall.

Secondary end points

Eight hips (24%) required re-operation secondary to postoperative complications other than dislocation. Seven hips (20%) were operated with soft-tissue debridement due to superficial infection (n=3) or with soft-tissue debridement and exchange of the modular parts of the implant due to deep periprosthetic infection (n=3). The bacterial cultures secured intraoperatively indicated growth of *staph. aureus* sensitive to Cloxacillin in 4 of the seven hips, 2 hips infected with coagulase negative staph. and one with MRSA.

One patient (3%) was re-operated with open reduction and internal fixation due to a periprosthetic fracture.

The mean Harris hip score was 67 (SD=14, median=74) while the mean hip pain numer-

Table 1. The indications of dual mobility cup use in our patients.

Indications for surgery	Patients
Recurrent dislocation after total or hemi-arthroplasty	12
Primary or secondary surgery after failed Internal fixation due to a fractured neck of femur in patients at high risk for dislocation.	13
Vertigo/postural instability (n=5), dementia (n=2), CVA (n=3), schizophrenia (n=2), Parkinson's disease (n=1).	
Primary surgery due to osteoarthritis in patients at risk for postoperative dislocations.	9
Vertigo/postural instability (n=2), CVA (n=2), rheumatoid arthritis (n=1), Parkinson's disease (n=3), mental retardation (n=1).	
Total	34

CVA, cerebro-vascular accident.

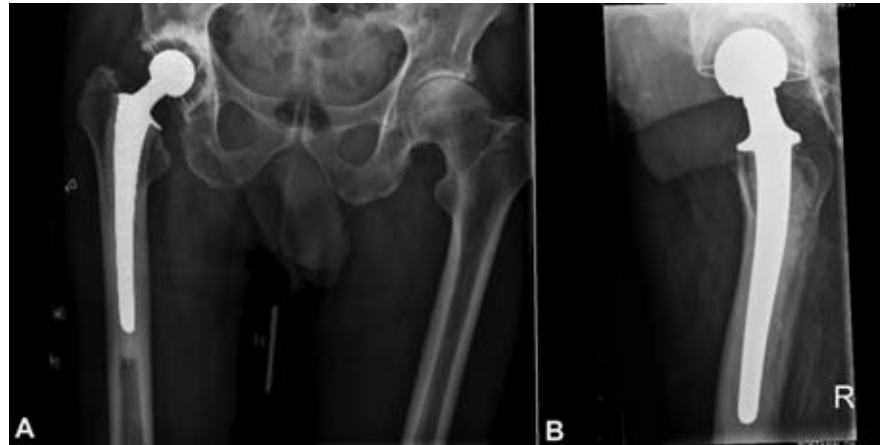

Figure 1. A) and B) the cup of this total hip prosthesis was revised to dual mobility cup due to recurrent dislocation. The antero-posterior view shows a decreased global offset of the operated side compared to the contra-lateral side while the lateral view shows inadequate anteversion of the cup. These two factors contribute to instability, especially in patients with good range of motion in the operated hip.

ating scale was 2.5 (SD=1.1). The mean EQ-5D index was 0.76 (SD=0.12, median=0.81) while the mean quality of life on a visual analogue scale was 70 (SD=21, median=76.5).

Discussion

The success of hip arthroplasty depends in part on the biomaterials used in bearing surfaces. The traditional hard-on-hard and hard-on-soft articulations such as ceramic on ceramic and metal on polyethylene respectively proved to be durable with low rate of wear. The introduction of DMCs, where the bearing surfaces included soft-on-hard articulation, created some concerns. Adam *et al.*, for instance, demonstrated a volumetric polyethylene wear of 54.3 mm³ annually in uncemented DMCs, which is comparable to conventional metal-on-polyethylene bearings with 22 mm heads.¹⁷ Furthermore, reports of long-term survival of these cups are sparse and mainly come from centers of origin in France.¹⁸ The first genera-



Figure 2. The Avantage® dual mobility cup. The metal head ranges from 22 mm to 28 mm in diameter depending on the cup size and it is pressed into the polyethylene liner with a special instrument. The liner articulates with the cylindro-spherical metal cup. This figure is the property of Biomet Inc of its affiliates, which have granted their permission for usage only on this publication and solely for educational and scientific purposes.

tions DMCs used in primary arthroplasty were evaluated by Vielpeau *et al.* who reported 84.4% survival with mean follow up of 16.5 years.¹³ After revision arthroplasty, on the other hand, Leiber-Wackenheim *et al.* found a survival rate of 98% after mean follow up of 8 years.¹¹ Further studies are needed to address the issue of long-term survival of the new generations of DMCs.

In the present study, the dislocation rate of 6% (2/34) was a little bit higher compared to other studies.¹⁸ The rate of early dislocation in patients receiving a hemiarthroplasty due to a fractured neck of femur was 9% at our department during 2011. While the positioning of components in other patients was within the safe zone for the acetabular cup and femoral stem, in one patient both the cup and stem were positioned with extreme anteversion (Figure 3A, B) and the implant dislocated anteriorly. This reflects the importance of accurate positioning of the components even with the DMCs, since relying on the intrinsic stability of these cups seemed to be insufficient. Apart from this we think the DMCs gave the early stability we anticipated for this high-risk group of patients. At our department, we use DMCs as the first choice for patients at risk for dislocation (severe dementia, neuromuscular disorders, muscle weakness, psychiatric disorders) and revision surgery due to recurrent dislocation. However, the evaluation of unstable hip prostheses is not an easy task and should include a thorough analysis of the patient and implant. Factors such as local soft-tissue defects or interposition, implant malposition or malsizing such as cup retroversion, decreased offset or improper inclination should all be considered and managed.

Table 2 list some of the commonly used DMCs in clinical practice. As shown, the minimal available diameter is 42 mm. This should be kept in mind when planning to operate patients with small acetabula, for instance dysplastic hips. In these case, DMCs might not be the proper choice.

Beside DMCs in the management of early hip instability, other options include constrained devices and large diameter femoral heads. Constrained devices are mainly used as salvage procedures for recurrent dislocation.¹⁹ Limitation of this modality is the limited range of motion and an increased rate of long time failure secondary to aseptic loosening.¹⁹ Large diameter femoral heads (36-40 mm) are used both as a primary procedure and revision surgery to gain increased stability. Previous studies have reported low dislocation rate as primary procedure in patients at risk but with an increased risk of revision surgery in comparison to conventional implants.^{20,21} This may be linked with the release of polyethylene particles from the liner, which eventually gives rise to aseptic loosening.²¹ Using large heads in revision surgery due to recurrent dislocation was associated with dislocation rates of 13.7%.²²

According to our routine, all patients received prophylactic pre- and postoperative antibiotics; despite this, the rate of superficial and deep infections in the present study was higher than the usual rate of 2-3%. Seven patients (20%) were operated with debridement with or without exchange of the modular parts of the implant. The treatment was effective in all patients and no implant revision was needed. We think the high infection rate in this study was mainly due to the selection of patients with different co-morbidities (mainly psychiatric, CVL, diabetes mellitus and heart failure). Of those 7 patients who had infections, 4 had ASA score of III and 5 were secondary procedures. This emphasizes the importance of perioperative care to optimize the medical condition pre-operatively and wound care postoperatively.

The functional outcome evaluated by HHS and quality of life evaluated with EQ-5D in the present study were comparable with those found by Götze *et al.* when presented their results of revision arthroplasty with DMCs.²³ On the other hand, Liber-Wackenheim *et al.* and Guyen *et al.* reported better functional outcome than in our patients.^{11,24} An explanation for this difference could be our high rate of postoperative infections.

Conclusions

The authors recommend the use of DMCs in risk patients. These cups could give the needed early hip stability (minimal of 6 months fol-

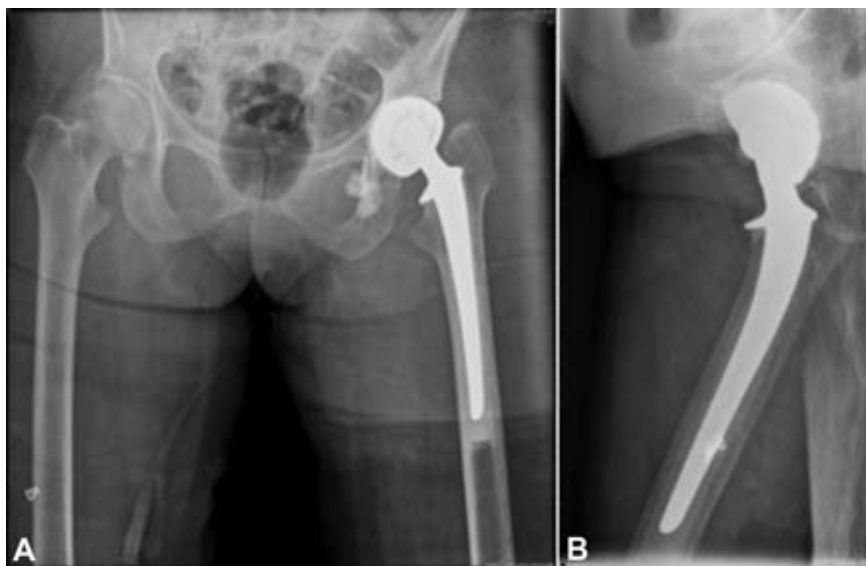


Figure 3. The antero-posterior (A) and lateral (B) views of the radiographs for the Avantagè dual mobility cup that dislocated. Note the extreme anteversion of the cup and the stem.

Table 2. Some of the commonly used dual mobility cups showing the available sizes and mode of fixation.

Name	Company	Available sizes (outer shell in mm)	Type of fixation
Restoration (ADM X3)	Stryker	46-64	Non-cemented
Trident (DMD X3)		44-72	Non-cemented
Active Articulation	Biomet	44-66	Non-cemented
Avantage		44-64	Non-cemented
		44-60	Cemented
Polarcup	Smith & Nephew	43-67	Non-cemented
		43-63	Cemented
Novae Sunfit	Orthodynamic	43-69	Non-cemented
Novae Stick		43-63	Cemented
Saturne	Amplitude	50-66	Non-cemented
Dual mobility cup	Tornier	42-68	Non-cemented
		42-60	Cemented

low-up), even when these operations are performed in a county hospital with a relatively low caseload for such procedures. We believe this could be of interest to orthopaedic surgeons working with a comparable sized departments and caseloads as ours, even if previous studies have shown the importance of large caseload volume, which has been associated with a lowered risk for complications and mortality.²⁵ Furthermore, postoperative complications such as superficial and deep infections are a concern in these patients and must be managed carefully.

References

- Hedbeck CJ, Enocson A, Lapidus G, et al. Comparison of bipolar hemiarthroplasty with total hip arthroplasty for displaced femoral neck fractures: a concise four-year follow-up of a randomized trial. *J Bone Joint Surg Am* 2011;9:445-50.
- Johansson T, Jacobsson SA, Ivarsson I, et al. Internal fixation versus total hip arthroplasty in the treatment of displaced femoral neck fractures: a prospective randomized study of 100 hips. *Acta Orthop Scand* 2000;71:597-602.
- Sköldenberg O, Ekman A, Salemyr M, Bodén H. Reduced dislocation rate after hip arthroplasty for femoral neck fractures when changing from posterolateral to anterolateral approach. *Acta Orthop* 2010;81:583-7.
- Phillips CB, Barrett JA, Losina E, et al. Incidence rates of dislocation, pulmonary embolism, and deep infection during the first six months after elective total hip replacement. *J Bone Joint Surg Am* 2003;85A:20-6.
- Carter AH, Sheehan EC, Mortazavi SM, et al. Revision for recurrent instability: what are the predictors of failure? *J Arthroplasty* 2011;26:46-52.
- Springer BD, Fehring TK, Griffin WL, et al. Why revision total hip arthroplasty fails. *Clin Orthop Relat Res* 2009;467:166-73.
- Bourne RB, Mehin R. The dislocating hip: what to do, what to do. *J Arthroplasty* 2004;19:111-4.
- Adam P, Philippe R, Ehlinger M, et al. Dual mobility cups hip arthroplasty as a treatment for displaced fracture of the femoral neck in the elderly. A prospective, systematic, multicenter study with specific focus on postoperative dislocation. *Orthop Traumatol Surg Res* 2012;98:296-300.
- Hamadouche M, Biau DJ, Hutten D, et al. The use of a cemented dual mobility socket to treat recurrent dislocation. *Clin Orthop Relat Res* 2010;468:3248-54.
- Langlais FL, Ropars M, Gaucher F, et al. Dual mobility cemented cups have low dislocation rates in THA revisions. *Clin Orthop Relat Res* 2008;466:389-95.
- Leiber-Wackenheim F, Brunschweiler B, Ehlinger M, et al. Treatment of recurrent THR dislocation using of a cementless dual-mobility cup: a 59 cases series with a mean 8 years' follow-up. *Orthop Traumatol Surg Res* 2011;97:8-13.
- Levine BR, Della Valle CJ, Deirmengian CA, et al. The use of a tripolar articulation in revision total hip arthroplasty: a minimum of 24 months' follow-up. *J Arthroplasty* 2008;23:1182-8.
- Vielpeau C, Lebel B, Ardouin L, et al. The dual mobility socket concept: experience with 668 cases. *Int Orthop* 2011;35:225-30.
- Guyen O, Pibarot V, Vaz G, et al. Unconstrained tripolar implants for primary total hip arthroplasty in patients at risk for dislocation. *J Arthroplasty* 2007;22:849-58.
- Owens WD, Felts JA, Spitznagel EL Jr. ASA physical status classifications: a study of consistency of ratings. *Anesthesiology* 1978;49:239-43.
- ATM. The Moore self-locking vitallium prosthesis in fresh femoral neck fractures: a new low posterior approach (the southern exposure). In: American Academy of Orthopaedic Surgeons. *Instructional Course Lectures*. St Louis: CV Mosby; 1959.
- Adam P, Farizon F, Fessy MH. Dual articulation retentive acetabular liners and wear: surface analysis of 40 retrieved polyethylene implants. *Rev Chir Orthop Reparatrice Appar Mot* 2005;91:627-36.
- Stroh A, Naziri Q, Johnson AJ, Mont MA. Dual-mobility bearings: a review of the literature. *Expert Rev Med Devices* 2012;9:23-31.
- Williams JT, Ragland PS, Clarke S. Constrained components for the unstable hip following total hip arthroplasty: a literature review. *Int Orthop* 2007;31:273-7.
- Geller JA, Malchau H, Bragdon C, et al. Large diameter femoral heads on highly cross-linked polyethylene: minimum 3-year results. *Clin Orthop Relat Res* 2006;447:53-9.
- Tarasevicius S, Kesteris U, Robertsson O, Wingstrand H. Femoral head diameter affects the revision rate in total hip arthroplasty: an analysis of 1,720 hip replacements with 9-21 years of follow-up. *Acta Orthop* 2006;77:706-9.
- Amstutz HC, Le Duff MJ, Beaulé E. Prevention and treatment of dislocation after total hip replacement using large diameter balls. *Clin Orthop Relat Res* 2004;429:108-16.
- Götze C, Glosemeyer D, Ahrens J, et al. [The bipolar cup Avantage in hip revision surgery]. *Z Orthop Unfall* 148:420-5, 2010. [Article in German].
- Guyen O, Pibarot V, Vaz G, et al. Use of a dual mobility socket to manage total hip arthroplasty instability. *Clin Orthop Relat Res* 2005;467:465-72.
- Shervin N, Rubash HE, Katz JN. Orthopaedic procedure volume and patient outcomes: a systematic literature review. *Clin Orthop Relat Res* 2007;457:35-41.