

case report

D-penicillamine-induced pseudo-pseudoxanthoma elasticum and extensive elastosis perforans serpiginosa with excellent response to acitretin

Muzamil Amin Chisti,^a Yousef Binamer,^a Abdullah Alfadley,^a Abdulmonem Almutawa^b

From the ^aDepartment of Dermatology, King Faisal Specialist Hospital and Research Centre, Riyadh, Saudi Arabia; ^bDepartment of Pathology and Laboratory Medicine, King Faisal Specialist Hospital and Research Centre, Jeddah, Saudi Arabia

Correspondence: Dr. Muzamil Amin Chisti · MBC 46 Department of Dermatology, King Faisal Specialist Hospital and Research Centre, PO Box 3354, Riyadh 11211, Saudi Arabia · T: +966114424608 · jan-phiny@gmail.com · ORCID: <http://orcid.org/0000-0002-6877-2715>

Citation: Chisti MA, Binamer Y, Alfadley A, Almutawa A. D-penicillamine-induced pseudo-pseudoxanthoma elasticum and extensive elastosis perforans serpiginosa with excellent response to acitretin. *Ann Saudi Med* 2019; 39(1): 56-60. DOI: 10.5144/0256-4947.2019.56

Received: January 4, 2018

Accepted: March 6, 2018

Published: January 31, 2019

Copyright: Copyright © 2018, *Annals of Saudi Medicine*, Saudi Arabia. This is an open access article under the Creative Commons Attribution-NonCommercial-NoDerivatives 4.0 International License (CC BY-NC-ND). The details of which can be accessed at <http://creativecommons.org/licenses/by-nc-nd/4.0/>

Funding: None.

D-penicillamine (DPA)-induced pseudo-pseudoxanthoma elasticum (PXE) and elastosis perforans serpiginosa (EPS) has been reported in the past, but most of the treatment modalities used before have a sub-optimal response. We report a case of DPA-induced pseudo-PXE with extensive EPS who had an excellent rapid response to acitretin. To the best of our knowledge no such report has been published in the past, even though there is a single report of effectiveness of isotretinoin in elastosis perforans serpiginosa.

SIMILAR CASES PUBLISHED: One similar case but with a different medication (reference 13).

D-penicillamine (DPA) is a copper chelator used primarily for treating Wilson's disease and cystinuria besides other indications. The cutaneous side effects of DPA include acute hypersensitivity reactions and abnormalities of elastic fibers—elastosis perforans serpiginosa (EPS) and pseudo-pseudoxanthoma elasticum (pseudo-PXE), autoimmune disorders (pemphigus and penicillamine-induced lupus erythematosus-like syndrome) and other dermatoses resulting from unknown mechanisms.¹ Guilaine et al reported the first case of DPA-induced EPS in a patient treated for Wilson's disease.² Later other elastic fiber alterations were reported including pseudo-PXE, which has PXE-like clinical features without any family history and mostly without any visceral involvement.³ Different treatment modalities have been tried for EPS with variable results. However, the treatment still remains a challenge as none of the modalities has consistent outcomes. We treated a case of DPA-induced pseudo-PXE and EPS who received acitretin with an excellent, rapid improvement of the lesions of EPS. To our knowledge, this response to treatment with acitretin has not been reported in the past.

CASE

A 37-year-old male with Wilson's disease and a positive family history (sister) with Wilson's disease, had been taking DPA for approximately 22 years when he was seen in our clinic in 2007 with a 3-month history of itchy skin lesions over the front of the neck. Examination revealed multiple excoriated skin-colored papules with fresh umbilicated erythematous papules over the right side of the neck. The skin over both the axillae was wrinkled, yellowish, waxy and hyperextensible, resembling plucked chicken skin with similar

findings over the back of his neck (**Figure 1 and 2**).

Skin biopsies from both sites (the wrinkled right axillary fold and from the neck papules) showed relatively similar histopathologic changes, with some differences. In the skin biopsy from the right axillary fold, some faintly basophilic fibres were noted scattered in the reticular dermis. Elastic-Van Gieson (EVG) stain revealed clumped and fragmented elastic fibers throughout the reticular dermis, many of which exhibited a frayed pattern with a serrated border (bramble-bush) (**Figure 3A and 3B**). These changes were consistent with PXE. A calcium stain was negative.

In the biopsy from the neck papules, short and fragmented eosinophilic fibers were observed in the dermis, focally aggregating and associated with multinucleated histiocytic giant cell inflammatory reaction, (**Figure 4A**). EVG stain demonstrated altered elastic fibres in a pattern similar to that seen in the right axillary fold biopsy, but in addition, focal transepidermal elimination of elastic fibres was observed (**Figure 4B**). These changes were consistent with EPS.

Certain features noted in these two biopsies (the extension of significant elastic fibre alteration into the deep dermis, the characteristic serrated lateral border, and the lack of calcium deposition), were all in keeping with a penicillamine-induced nature form rather than the

idiopathic/inherited forms. The patient was also evaluated for ABCC6 (ATP-binding cassette sub-family C member 6) mutation and it was negative. So a diagnosis of penicillamine induced pseudo-PXE and EPS was made.

DPA was stopped and replaced by trientine. The patient was given symptomatic treatment for itching and topical adapalene 0.1% cream. However, he did not improve and continued to develop fresh papular lesions over the arms, elbows and axillae. He also received intralesional triamcinolone, pulse dye laser (PDL), and cryotherapy with no significant improvement. He progressed and developed extensive severely pruritic lesions within two years of stopping DPA, particularly over both buttocks. Examination at that time showed multiple erythematous to brownish umbilicated papules coalescing into annular and arciform plaques over the axillae, neck, elbows and buttocks (**Figure 1 and 2**). Considering the failure of other treatment modalities and the clinical condition of the patient, he was started on acitretin 25 mg/day after discussing the treatment options and providing written informed consent. The dose of acitretin was increased to 50 mg/day after two weeks. He started improving within three weeks of starting the treatment and at nine weeks he had >95% improvement with almost total clearance of his lesions (**Figures 1 and 2**) and the dose was decreased to 25mg/

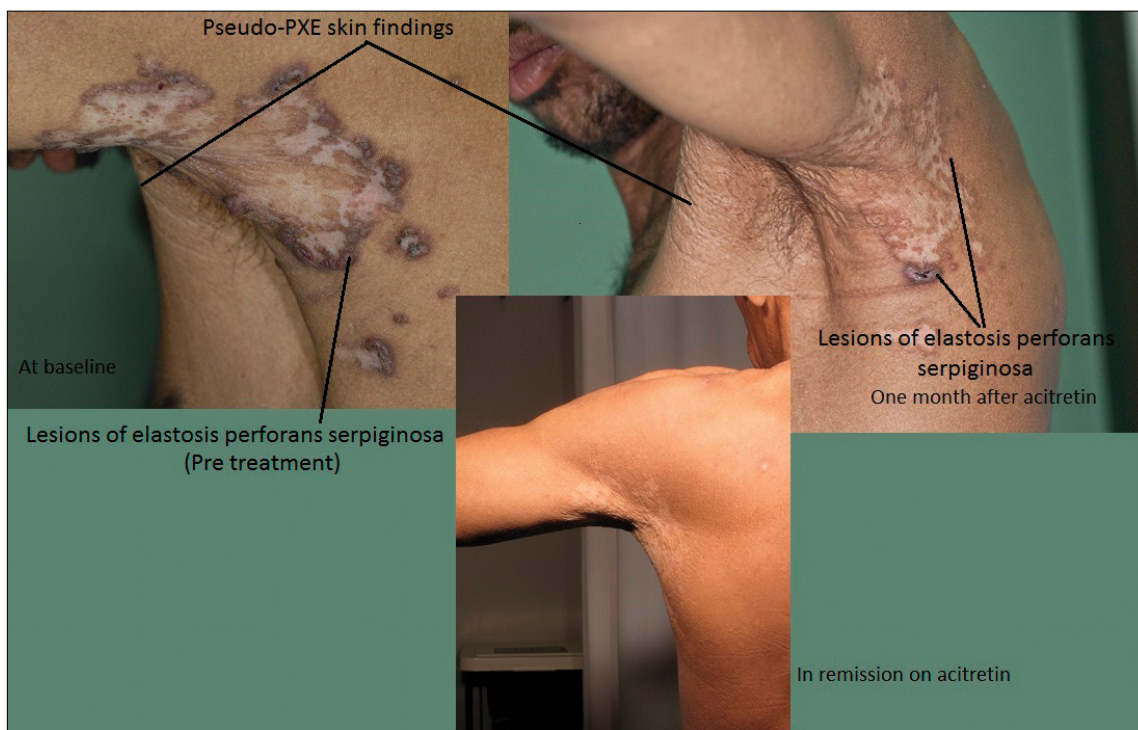

Figure 1. Pre- and post-treatment photos of elastosis perforans serpiginosa (axilla)

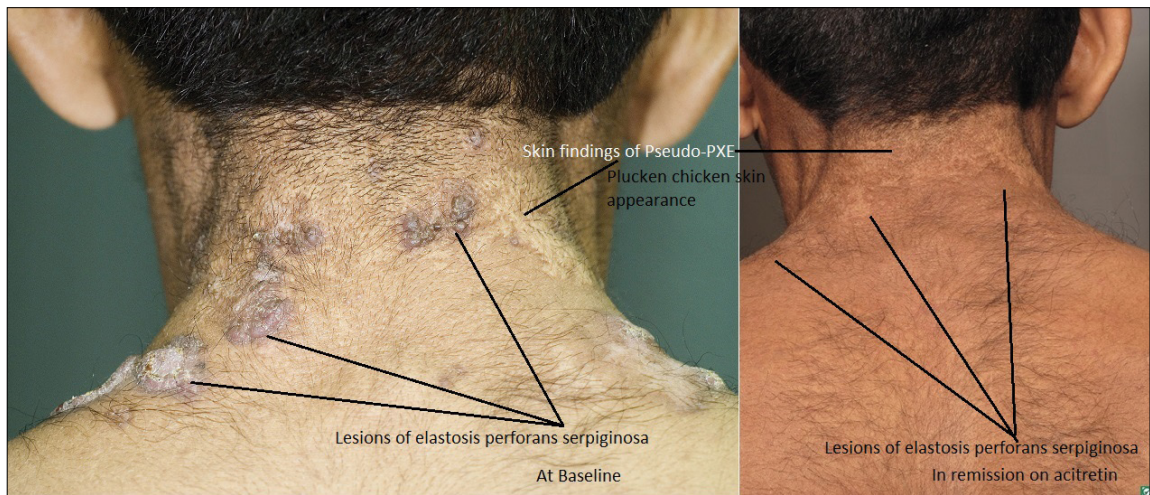


Figure 2. Pre- and post-treatment photos of elastosis perforans serpiginosa (neck).

day. He has been followed in our clinic for the last eight years and has maintained the clinical benefit while on treatment (25 mg every other day), which flares up on stopping the treatment.

DISCUSSION

Abraham et al in 1943 first recognized penicillamine (D-b, b-dimethyl cysteine) as a degradation product of penicillin.⁴ DPA-induced EPS has been described as hyperkeratotic papular lesions usually arranged in an annular or serpiginous configuration over any body surface including the lips,⁵ oral mucosa,⁶ and the glans penis.¹ These lesions cannot be distinguished from lesions of idiopathic EPS. Histologically, the lesions showed perforating canals extending from the dermis with transepidermal extension. These contain a mixture of degenerated eosinophilic fibers of elastin, basophilic debris and inflammatory cells.³ It might be possible to differentiate penicillamine-induced EPS from other acquired EPS forms by demonstrating the characteristic “bramble-bush” appearance of elastic fibers or the presence of serrated elastic fibers on microscopy in both involved and uninvolved skin.⁷

The lesions can resolve spontaneously after cessation of therapy.³ Discontinuation of penicillamine therapy does not necessarily result in the disappearance of the lesions and new EPS lesions have been reported even after five years of discontinuation,⁵ and in the case of our patient up to ten years. There is no clear explanation for the appearance of these lesions for such a prolonged period.

The clinical appearance of PXE, classically due to a ABCC6 gene mutation, consists of small, well circumscribed, yellowish papules on the flexures and sides of

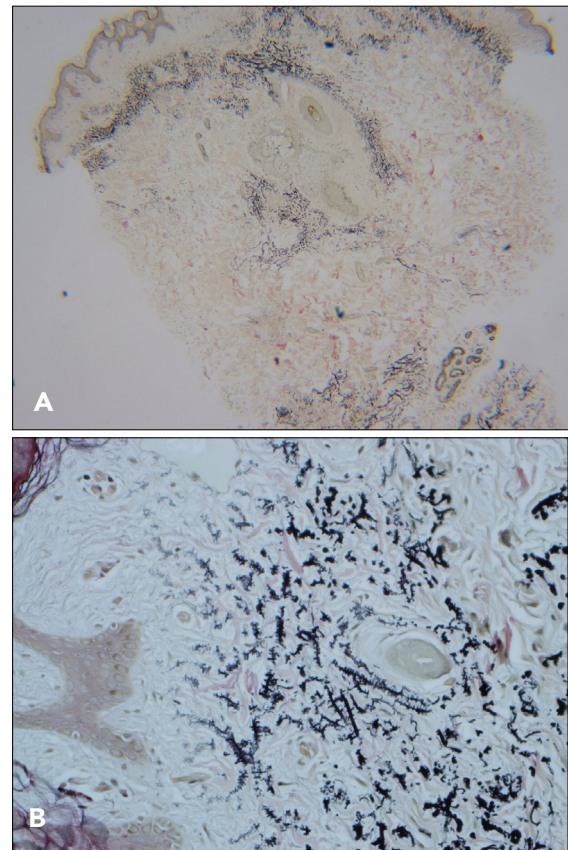


Figure 3. Elastic-Van Gieson stain of the skin biopsy from the right axillary fold. A) clumped and fragmented elastic fibers throughout the reticular dermis (50×). B) high magnification with a frayed pattern and serrated border (400×).

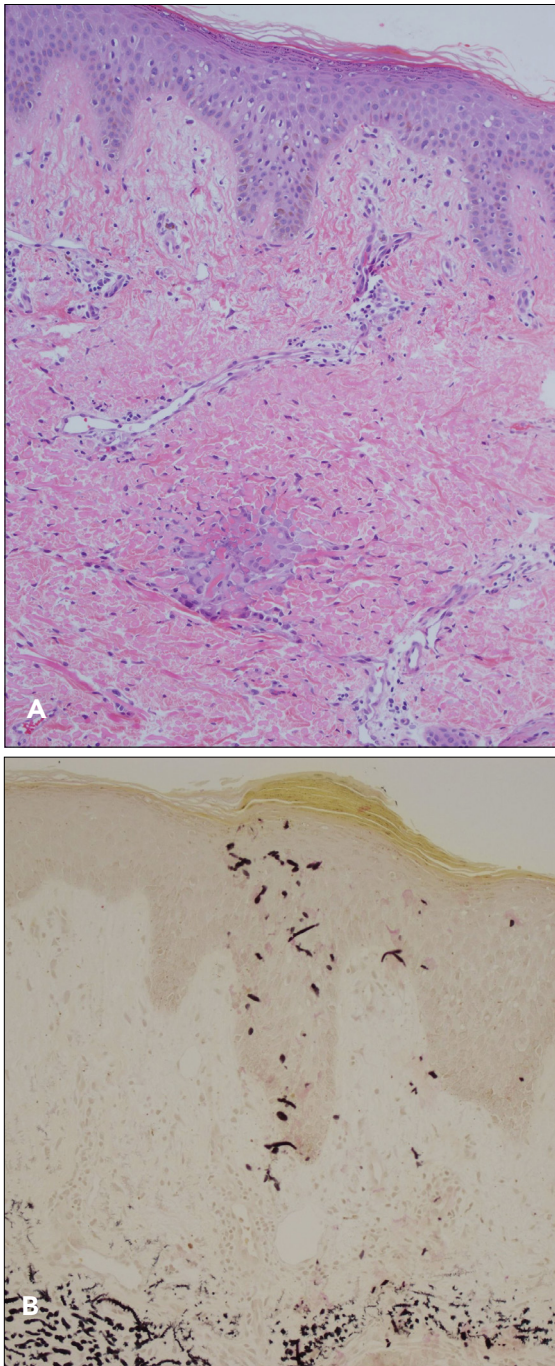


Figure 4. Skin biopsy from the neck papules. A) aggregating short and fragmented eosinophilic elastic fibers, associated with multinucleated histiocytic giant cell inflammatory reaction (200×). B) Elastic-Van Gieson stain revealing focal transepidermal elimination of elastic fibres (200×).

the neck, which have been described as 'plucked chicken skin'.³ Histology of the skin shows disorganization and fragmentation of the elastic fibers, with aberrant calcification of the elastic tissue being the main pathologic finding. Similar findings have been described in the cardiovascular system, retina, lungs, joint capsules and esophagus.⁵ Pseudo-PXE and PXE have a different etiology and structural abnormalities even though they look clinically similar in terms of skin findings. In pseudo-PXE, there is no role for calcium in fiber instability and it is the penicillamine that makes the cross linkage unstable,³ and as such the calcium stain (Von Kossa) is often negative.⁸ Pseudo-PXE usually results in a localized disease with sparing of the face. Electron microscopic features of pseudo-PXE include a core of electron dense microfibrils and protrusions of electron-lucent lumps of elastin matrix.³ There are many reports of penicillamine-induced pseudo-PXE, but penicillamine has also been implicated in causing EPS and pseudo-PXE in a same patient as is the case with our patient.^{3,9} Different modalities of treatment have been tried for EPS induced by penicillamine with variable results including cryotherapy, electrocautery, photodynamic therapy, imiquimod, tazarotene gel, intralesional steroids, curettage and laser.¹⁰ However, for pseudo-PXE, there is no medical treatment to expedite the resolution of the skin lesions and recover the elasticity.¹¹

Jan V et al has reported the use of acitretin in a girl with vitamin A deficiency-associated EPS, but the medication had to be stopped after two months because of hepatotoxicity despite clinical improvement.¹² Ratnavel et al used isotretinoin successfully for treatment of DPA-induced EPS.¹³ However, there was no mention of the follow-up period in that report after the initial improvement within 6 weeks. After consultation with a hepatologist, we decided to give acitretin to our patient as it is longer acting than isotretinoin.

Acitretin is a second-generation oral retinoid mainly used for the treatment of psoriasis. All systemic retinoids are potent teratogens. The worst effects of acitretin are mucocutaneous effects such as cheilitis and hair loss, which are dose-dependent. Besides these, elevated liver enzymes and hypertriglyceridemia are also common with acitretin.¹⁴ Our patient improved rapidly but he needed maintenance treatment with acitretin at a low dose of 25 mg every other day and developed a flare on discontinuing therapy. Although he has stopped penicillamine for a long period of time, he still needs maintenance therapy. A possible explanation for these recurrent recurrences is that penicillamine triggered the abnormal maturation and synthesis process of collagen and elastin which continues even after stopping the offending medication.

REFERENCES

1. Ishak R, Abbas O. Penicillamine revisited: historic overview and review of the clinical uses and cutaneous adverse effects. *Am J Clin Dermatol.* 2013 Jun; 14(3):223-33.
2. Guilaïne J, Benhamou JP, Molas G. Veruciform perforating elastoma in a patient treated by penicillamine for Wilson's disease. *Bull Soc Fr Dermatol Syphiligr.* 1972; 79(5):450-3.
3. Bécuwe C, Dalle S, Ronger-Savlé S, Skowron F, Balme B, Kanitakis J, Thomas L. Elastosis perforans serpiginosa associated with pseudo-pseudoxanthoma elasticum during treatment of Wilson's disease with penicillamine. *Dermatology.* 2005; 210(1):60-3.
4. Abraham EPC, Baker W, Robinson R. Penicillamine, a characteristic degradation product of penicillin. *Nature.* 1943; 151: 107-10.
5. Lewis BK, Chern PL, Stone MS. Penicillamine-induced elastosis of the mucosal lip. *J Am Acad Dermatol.* 2009; 60(4):700-3.
6. Tovar S, Parlatescu I, Dumitriu AS, et al. Oral complications associated with D-penicillamine treatment for Wilson disease: a clinicopathologic report. *J Periodontol.* 2010; 81(8):1231-6.
7. Bergman R, Friedman-Birbaum R, Ludatscher R, et al. An ultrastructural study of the reactive type of elastosis perforans serpiginosa. *Arch Dermatol.* 1987; 123(9):1127-9.
8. Rayatt S, Pandey U, Khanna A. Familial pseudo pseudoxanthoma elasticum. *J Plast Reconstr Aesthet Surg.* 2006; 59(10): 1127-9.
9. Namita Rath, Amit Bhardwaj, Hemant Kumar Kar, PK Sharma, Meenakshi Bhardwaj, SC Bharija. Penicillamine induced pseudoxanthoma elasticum with elastosis perforans serpiginosa. *Indian J Dermatol Venereol Leprol* 2005;71:182-5.
10. Kelly SC, Purcell SM. Imiquimod therapy for elastosis perforans serpiginosa. *Arch Dermatol.* 2006 Jul; 142(7):829-30.
11. Ibáñez-Samaniego L, Ochoa-Palominos A, Catalina-Rodríguez MV, Salcedo-Plaza M, Clemente-Ricote G. Penicillamine induced pseudopseudoxanthoma elasticum in a patient with Wilson's disease, which role plays the hepatologist? *Rev Esp Enferm Dig* 2015; 107 (3): 190-191.
12. Jan V, Saugier J, Arbeille B, Maurage C, Callens A, Lorette G. Elastosis perforans serpiginosa with vitamin A deficiency in a child with trisomy 21. *Ann Dermatol Venerol.* 1996;123(3):188-90. (Article in French)
13. Ratnavel RC, Norris PG. Penicillamine-induced elastosis perforans serpiginosa treated successfully with isotretinoin. *Dermatology.* 1994; 189: 81-83.
14. Hai Suee Le, John Koo. A review of acitretin, a systemic retinoid for the treatment of psoriasis. *Expert Opinion on Pharmacotherapy* 2005;6(10): 1725-34.