



Contents lists available at ScienceDirect

International Journal of Surgery Case Reports

journal homepage: www.casereports.com

Conservative management of an unusual bilioduodenal fistula post laparoscopic Duodeno-Ileal Switch (SADI-S) case report



E. Chelala*, E. Adam, A. Rizk, E. Makhoul

University Hospital of Notre Dame des Secours, Affiliated To FMSM at USEK, Université St Esprit Kaslik, Byblos, Lebanon

ARTICLE INFO

Article history:

Received 4 November 2016
 Received in revised form 27 February 2017
 Accepted 27 February 2017
 Available online 6 March 2017

Keywords:

Bilioduodenal fistula
 SADI-S
 Laparoscopic duodenal switch
 Internal biliodigestive fistula
 Choledocoduodenal fistula

ABSTRACT

INTRODUCTION: Single anastomosis duodeno-ileal bypass with sleeve gastrectomy (SADI-S) is an advanced operation for morbid obesity. To our knowledge, no internal Biliodigestive Fistula has yet been reported as specific complication in the field of metabolic and bariatric Biliopancreatic diversion.

CASE PRESENTATION: In this case report, we detail the case of a 57-year-old man who underwent a Single Anastomosis Duodeno-Ileal Switch (SADI-S) bariatric procedure for morbid obesity.

Upon admission 3 weeks after the SADI-S procedure acute sepsis caused by a delayed choledocoduodenal Fistula was diagnosed.

A conservative management of this rare complication was successful.

DISCUSSION: We highlight the differential diagnosis and optional treatment in such a rare complication, and how we succeeded in its conservative management, without any need for endoscopic nor surgical intervention.

A review of the literature on different types of Internal Biliodigestive Fistulae and their appropriate management are reported and briefly discussed.

CONCLUSION: The aim of this case report is to highlight the existence of such a rare complication, and its successful multidisciplinary conservative medical management.

© 2017 The Author(s). Published by Elsevier Ltd on behalf of IJS Publishing Group Ltd. This is an open access article under the CC BY-NC-ND license (<http://creativecommons.org/licenses/by-nc-nd/4.0/>).

1. Introduction

Single Anastomosis Duodenal Bypass with Sleeve gastrectomy (SADI-S) is a new operation for morbid obesity based on the biliopancreatic diversion in which a sleeve gastrectomy is followed by an end-to-side duodeno-ileal diversion. The preservation of the pylorus with Bilroth II reconstruction in one loop reduces operating time and surgically related complications.

Literature reports on complications after Bilio Pancreatic Diversion (BPD) or Duodenal Switch (DS) or SADI-S include description of anastomotic or external fistulae from the stapled line [1]. To our knowledge, no internal Biliodigestive Fistula has yet been reported as specific complication in the field of metabolic and bariatric BPD.

2. Case presentation

In this case report, all information was reported in line with the SCARE criteria [2].

A 57-year-old male smoker was referred to the academic Bariatric and Metabolic Surgery Unit. His BMI was 45 kg/m², he suffered from pre-diabetes and had a sweets-eating and nibbling

eating disorder. His medical history was significant for, treated arterial hypertension, two prior cerebrovascular accidents, treated by Plavix, dyslipidemia, laparotomy for incisional hernia, right Lung Lobectomy. He had no history of smoking or alcohol abuse.

After a multidisciplinary team discussion, a Malabsorptive Procedure was selected. The patient underwent a Laparoscopic Single anastomosis Biliopancreatic Diversion, (SADI-S). The procedure was performed using 4 trocars (2 × 5 mm – 2 × 12 mm). Gastrolysis was initiated at 4 cm from the pylorus going cephalad and a sleeve gastrectomy was carried out up to the left crus. Adhesiolysis was performed and the duodenum was transected 3 cm distal to the pylorus, using a linear stapler with 2.8 mm cartridge (EndoGIA, Covidien, Norwalk, and Ct). A latero-lateral, tension free, antecolic, 3-layer manual anastomosis was performed with V-lock Maxon 3/0 between the proximal duodenal section plane and the distal jejunum, some 300 cm proximal to the ileocaecal valve. After conclusion of the anastomosis a Methylene Blue test was performed that showed no leakage.

The patient had an uneventful early recovery. Gastrographin® swallow on the 2nd post-operative day revealed no leakage and swift passage of the dye in both limbs was documented. The patient was authorized to start a liquid diet on the 2nd postoperative day, and because he did not suffer dysphagia he was advanced to a semiliquid diet. On the third postoperative day the patient was discharged home on a soft diet. On the 14th post-operative day the

* Corresponding author at: University Hospital of NDS, Byblos, PO Box 3, Lebanon.
 E-mail address: cheli@skynet.be (E. Chelala).

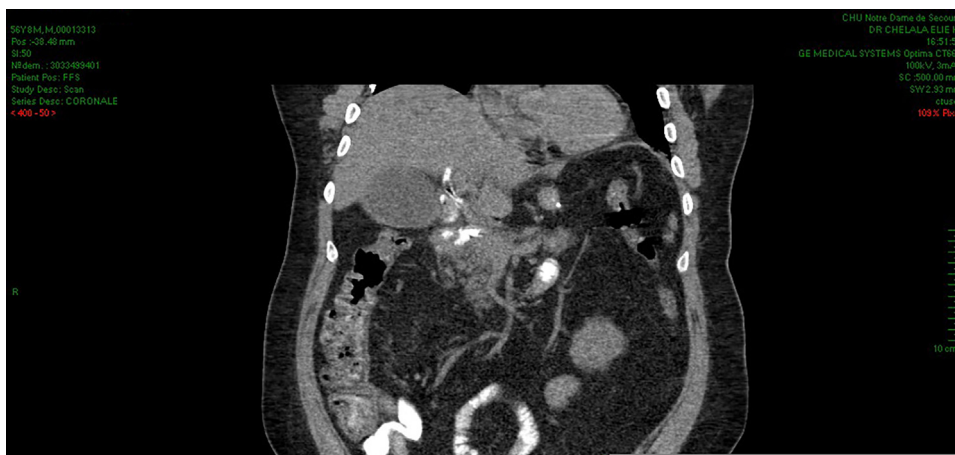

Fig. 1. Posterior duodenobiliary fistula with aerobilia without intra-abdominal liquid.

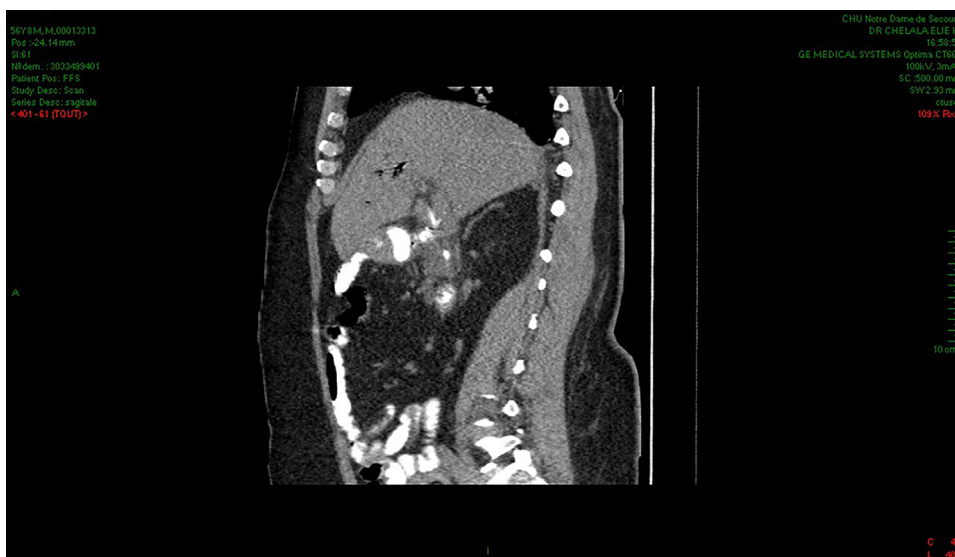


Fig. 2. Gall bladder & Biliary tract opacified.

patient was seen in the outpatient clinic. Weight loss was 9 kg. Food intake was correct and the patient denied diarrhea, jaundice, nausea, vomiting, or fever. The skin stitches were removed and good wound healing was noted.

The patient was readmitted on the 22nd day post-op for abdominal pain and fever at 39°C. A physical exam revealed a hemodynamically stable and comfortable individual in no acute distress but with mild epigastric tenderness. Blood work revealed an inflammatory syndrome: WBC 10,500 10³/uL and CRP 158 mg/L, Hemoglobin 13 g/dl and normal Liver function tests. A workup with oral contrast CT demonstrated a Retro-Duodenal Collection with opacification of the hepatic and common bile duct (CBD). Diagnosis of posterior duodenobiliary fistula with aerobilia but without intra-abdominal liquid was made (Figs. 1 and 2).

The management was collegially decided to be conservative: Plavix^o was discontinued and total parenteral nutrition (TPN) initiated. Broad spectrum antibiotics (Tienam[®]) were given intravenously for 15 days. Reevaluation was done after 48 hours for possible Endoscopy or Laparoscopic Exploration.

However, during the first week there appeared to be daily improvement of the patient's condition. The patient became afebrile and pain free and the inflammatory syndrome regressed. The gastro-intestinal transit improved and nausea was easily con-

tained with Zofran/Ondansetron[®] and Motilium/dompéridone[®]. Oral liquid feedings, followed by jellow were reauthorized after 7 days. The clinical and biological improvement (CRP 11 mg/L) continued, allowing the discontinuation of TPN and antibiotics 15 days after readmission.

An Oral contrast CT scan check 15 days after admission showed no leakage, partial resorption of the collection, and reduced size of the Bilio digestive fistula. The patient was discharged on day 15 under mixed diet, and oral antibiotic coverage for 15 more days.

He was followed-up at 3 and 9 months and found to be in excellent health with a weight loss of 29 kg and 40 kg, respectively. CT scan + contrast study were fully normalized.

3. Discussion

In the literature, internal biliodigestive fistula consist of abnormal connections between the biliary tree and the duodenum, colon and stomach [3,4], that might be easily misdiagnosed.

In 10% of cases they occur spontaneously as a Cholecystoduodenal Fistula following acute or chronic cholecystitis or neoplastic disease. In 90% of the cases the internal fistula is part of Bouveret's syndrome or gallstone ileus.

As to the exact location, in a majority of cases (62%) the fistula affects common bile duct (CBD) and duodenum (choledochoduodenal fistula after cholecystitis or iatrogenic perforation), followed by gallbladder and duodenum (cholecystoduodenal fistula), in 19%, stomach in 11%, colon in 8%, and jejunum in 3% of the cases [5].

The pathophysiologic mechanism involves pressure necrosis from calculi on an inflamed gallbladder wall, and secondary perforation resulting in internal fistula formation. An early diagnosis with consequent reduction of lag time between potential ileus or abscess to treatment, is of paramount importance. Early diagnosis is however impaired by the absence of specific pathognomonic signs and diagnosis hence appropriate treatment is often delayed for weeks.

Diagnostic signs include the radiological Rigler's Triade present in 1/3 of Gallstone Ileus cases and consisting of (Distended small bowel/Pneumobilia/Ectopic Calcified Gallstone), or the specific findings on Cholangio MRI.

The treatment of internal fistula depends on the type, location, extension and communication of the fistula.

A majority of Cholecystoduodenal or Cholecystocolonic fistulae can be managed by Laparoscopic cholecystectomy combined to a closure of the bowel defect [6,7].

Conversely, difficult cases such as fistulae with the CBD are technically more challenging to repair laparoscopically, and even in skilled hands, carry a high risk of damage to CBD, with consequent bile or fecal spillage into abdominal cavity leading to peritonitis.

Therefore, in selected cases open surgery is still highly recommended, to allow adhesiolysis of fibrotic tissue and exclusion with potential Roux-en-Y Biliodigestive derivation [8].

In case of bilio-biliary or bilio-duodenal fistula, as in our case, non-operative management such as endoscopic drainage by ERCP and placement of a self-expandable metallic stent to reduce bilio-duodenal pressure can be contemplated [9].

In this particular case of postoperative local inflammatory spontaneous connection between duodenum and CBD, we opted for a medical conservative management to avoid the potential risk of more damage to the biliary tree with success.

4. Conclusion

Unusual post-operative complications such as biliodigestive fistulas may occur after BPD or SADI-S. They demand accurate multidisciplinary early diagnosis, staging by Cholangio Scan, and appropriate treatment.

Literature data on Biliodigestive fistula post BPD or SADI-S are scarce. However, in absence of intraabdominal abscess or acute abdomen, a conservative treatment including feeding and prolonged antibiotic treatment may salvage a jeopardized operation.

Conflicts of interest

All authors disclose that there are no conflicts of interest related to this work.

Sources of funding

None.

Open Access

This article is published Open Access at sciedirect.com. It is distributed under the [IJSCR Supplemental terms and conditions](#), which permits unrestricted non commercial use, distribution, and reproduction in any medium, provided the original authors and source are credited.

Ethical approval

Not Needed for this case report.

Consent

Patient's name and data are anonymous.

Author contributions

Study concepts: E. Chelala – E. Makhoul.

Study design E. Chelala – E. Makhoul.

Data acquisition: E. Chelala – E. Makhoul.

Quality control of data and algorithms: E. Chelala – E. Makhoul.

Data analysis and interpretation: –

Statistical analysis: –

Manuscript preparation: E. Chelala – E. Makhoul.

Manuscript editing: E. Chelala – E. Makhoul.

Manuscript review: E. Chelala – E. Makhoul.

Registration of research studies

Not needed for a case report.

Guarantor

Dr Elie Chelala.

Acknowledgment

The authors would like to acknowledge and thank Pr. J. Himpens for his support in managing and editing this case report.

References

- [1] Lars Nelson, Rena C. Moon, Andre F. Teixeira, Manoel Galvão, Almino Ramos, Muhammad A. Jawad, Safety and effectiveness of single anastomosis duodenal switch procedure: preliminary result from a single institution, *Arq. Bras. Cir. Dig.* 29 (Suppl. 1) (2016) 80–84, <http://dx.doi.org/10.1590/0102-6720201600510020>.
- [2] R.A. Agha, A.J. Fowler, A. Saetta, I. Barai, S. Rajmohan, D.P. Orgill, the SCARE Group, The SCARE statement: consensus-based surgical case report guidelines, *Int. J. Surg.* 34 (2016) 180–186.
- [3] Heljä Oikarinen, M. Päivänsalo, T. Tikkakoski, A. Saarela, Radiological findings in biliary fistula and gallstone ileus, *Acta Radiol.* 37 (November (6)) (1996) 917–922.
- [4] Steven F. O'Dell, Michael L. McCann, Laparoscopic repair of cholecystenteric fistula in a 45-Year-Old, ambulatory woman, *Hosp. Physician (March)* (2000).
- [5] H. Yamashita, K. Chijiwa, Y. Ogawa, et al., The internal biliary fistula: reappraisal of incidence, type, diagnosis, and management of 33 consecutive cases, *HPB Surg.* 10 (1997) 143–147.
- [6] A. Sharma, M. Sullivan, H. English, R. Foley, Laparoscopic repair of cholecystoduodenal fistulae, *Surg. Laparosc. Endosc.* 4 (1994) 433–435.
- [7] S.J. Nixon, M.M. Mirghani, Laparoscopic management of cholecystenteric fistula, *Br. J. Surg.* 82 (1995) 675–676.
- [8] M. Ludmil Veltchev, A. Manol Kalnieve, A. Todor Todorov Mirizzi, Syndrome-rare cause of major biliary complications. Case report, *J. IMAB-Annu. Proc. (Scientific Papers)* (2009) 92–94, Book 1.
- [9] S. Shibata, J. Tanaka, Y. Asanuma, H. Andoh, T. Yoshioka, K. Koyama, T. Ebina, R. Koizumi, A case of bilioduodenal fistula treated with a self-expandable metallic stent, *Hepatogastroenterology* 46 (July–August (28)) (1999) 2196–2198.