

Postoperative Headache after Undergoing Acoustic Neuroma Surgery via the Retrosigmoid Approach

Noritaka AIHARA,¹ Hiroshi YAMADA,¹ Mariko TAKAHASHI,² Akira INAGAKI,²
Shingo MURAKAMI,² and Mitsuhiro MASE¹

¹Department of Neurosurgery, Nagoya City University Medical School,
Nagoya, Aichi, Japan;

²Department of Otorhinolaryngology, Nagoya City University Medical School,
Nagoya, Aichi, Japan

Abstract

To estimate the duration of postoperative headache after surgery for acoustic neuroma and the effects of age, sex, tumor size, extent of tumor resection, type of skin incision, surgical duration, hearing preservation, and postoperative facial nerve palsy. This retrospective review analyzed clinical data from 97 patients who had undergone surgery for unilateral acoustic neuroma via the retrosigmoid approach >1 year previously. We investigated whether patients had headache at hospital discharge and during attendance at outpatient clinics. We classified postoperative headache as grade 0 (no headache), 1 (tolerable headache without medication), or 2 (headache requiring medication). The period of headache was defined as the interval in days between surgery and achievement of grade 0. The period of medication for headache was defined as the interval in days between surgery and achievement of grade 0 or 1. Kaplan-Meier analysis revealed median durations of medication and headache of 81 and 641 days, respectively. Headache was cured significantly earlier in patients who underwent surgery using a *C-type* skin incision ($P < 0.001$). Headache persisted significantly longer among patients who underwent a shorter surgical procedure ($P < 0.02$). Multivariate analysis confirmed the type of skin incision as a factor independently associated with duration of postoperative headache. Postoperative headache was cured in the majority of patients within about 2 years after surgery. The *C-type* skin incision is likely beneficial for reducing the duration of postoperative headache, although headache persisted in a small number of patients.

Key words: acoustic neuroma, postoperative headache, retrosigmoid approach, skin incision

Introduction

Postoperative headache after suboccipital craniotomy is not rare, with a reported incidence of 25–75%.^{1–5)} This complication is common after acoustic neuroma surgery, typically extending from the occiput to the neck as with tension-type headache, but occasionally mimicking migraine.^{3,6,7)} How long postoperative headache continues after surgery remains unclear. If the duration could be clarified, useful information could be provided to patients considering or scheduled to undergo acoustic neuroma surgery. We therefore investigated the duration of postoperative headache for acoustic neuroma in our cases and examined factors potentially affecting the duration.

Materials and Methods

Institutional review board approval was obtained for this study.

Patients

Data were analyzed for patients who underwent resection of unilateral acoustic neuroma using a retrosigmoid approach at Nagoya City University Hospital between July 2006 and March 2014. We excluded patients who: presented with headache on admission; had previously been treated for headache; had received additional surgical treatments for cerebrospinal fluid leakage or wound infection; or had previously undergone surgery for acoustic neuroma.

Duration of headache

We investigated whether patients had headache at hospital discharge and during attendance at

Received May 16, 2017; Accepted July 21, 2017

Copyright© 2017 by The Japan Neurosurgical Society
This work is licensed under a Creative Commons Attribution-NonCommercial-NoDerivatives International License.

outpatient clinics. Patients completed the following brief questionnaire both at hospital discharge and on follow-up at outpatient clinics: *Question 1) Have you been experiencing headache or wound pain since the surgery (regardless of severity)?*; and *Question 2) Do you need medication for headache or wound pain (regardless of frequency)?* Patients answered either “Yes” or “No” to each question. Patients repeatedly received this questionnaire on the day of consultation. We then classified postoperative headaches as grade 0 (no headache), 1 (tolerable headache without medication), or 2 (headache requiring medication). The period of medication for headache was defined as the number of elapsed days between the date of surgery and the date on which the patient first achieved grade 0 or 1 (i.e., no longer required medication for headache). The period of headache was defined as the number of days between the date of surgery and the date on which the patient first achieved grade 0 (i.e., no longer experienced headache). If the patient received stereotactic radiosurgery after tumor resection, the last observation day was defined as the day of consultation on which stereotactic radiosurgery was recommended.

Outpatient clinic

Usually patients visited the outpatient clinic in our hospital about 3 weeks after discharge, then again at 3 months, 6 months, and 1 year after surgery.

Thereafter, the patient visited once or twice a year, according to their individual condition. If a patient was followed-up at another institution, the last observation day was defined as the day on which the patient last visited our hospital.

Surgical procedure for retrosigmoid approach

The head was secured in a 3-point fixation in a Mayfield headholder. The patient was placed in the park-bench position. Degree of neck flexion was not modified according to tumor size.

Procedures for skin incision with muscle dissection were classified into 2 patterns: *lazy S* or *C-type*.

The *lazy S incision* was started 4 cm above the superior nuchal line, passing through the point halfway between theinion and mastoid process, and descending along the midline of the cervical spine (Fig. 1A). The sternocleidomastoid, semispinalis capitis, and splenius capitis muscles were divided along the skin incision and retracted bilaterally. The rectus capitis posterior major and inferior oblique muscles were detached from the skull bone and retracted caudally.

The *C-type incision* was a semicircular skin incision starting 2 cm above the superior nuchal line, passing through a point about 2 cm inside the *asterion*, and descending 2 cm behind the mastoid process (inside the hairline of the neck) (Fig. 1B). The sternocleidomastoid muscle was reflected laterally,

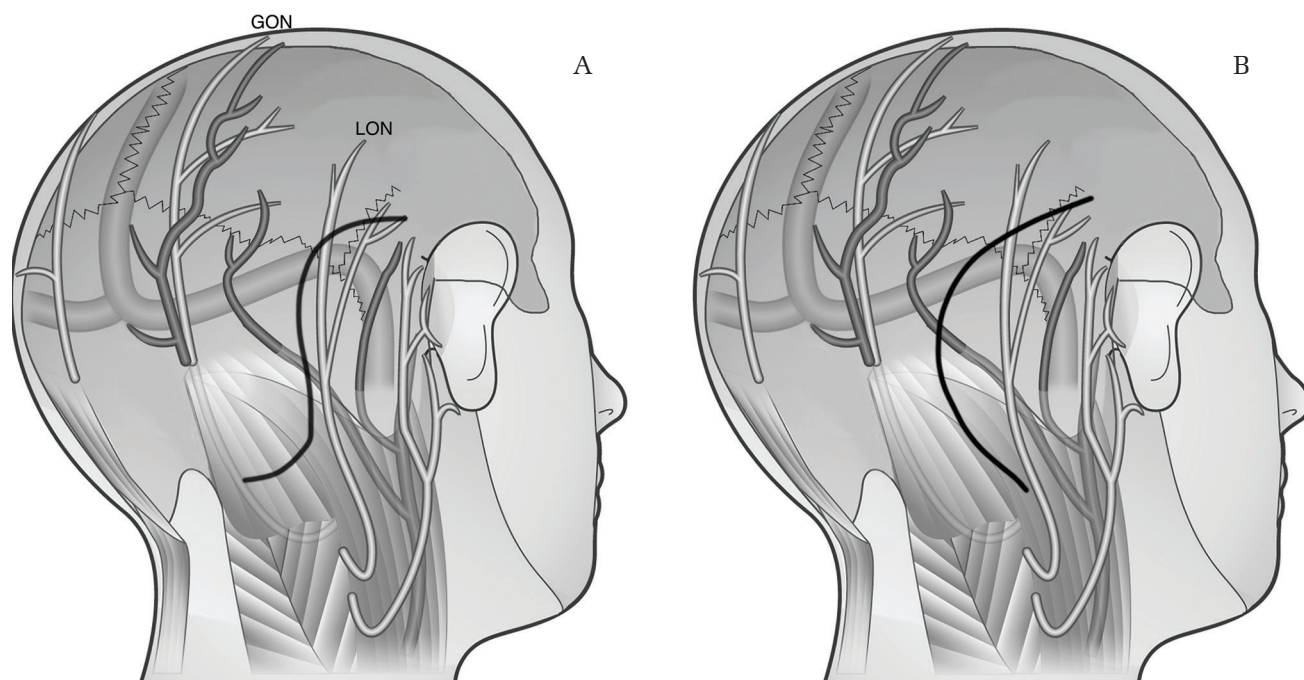


Fig. 1 The 2 types of skin incision used in this study. (A) *lazy S* skin incision, (B) *C-type* skin incision. Retraction and stretching of the GON are likely to occur in lazy-S skin incision. GON: greater occipital nerve; LON: lesser occipital nerve.

while the other suboccipital muscles (semispinalis capitis, splenius capitis, rectus capitis posterior major, and inferior oblique muscles) were detached and folded back.

With both of these incisions, two burr holes were then made and an osteoplastic craniotomy approximately 4 cm wide was created.

We generally aimed for total removal of the tumor, but some parts of the tumor were intentionally left to preserve neurological function, depending on the intraoperative condition.

After closure of the dura, the bone flap was replaced and secured with titanium plates and screws. The muscles and skin incisions were then rejoined and sutured together. No drainage tube was placed.

Factor analysis for postoperative headache

We examined whether the duration of headache could be affected by age, sex, tumor size, type of skin incision, extent of tumor resection, surgical duration, hearing preservation, or postoperative facial nerve palsy.

Age

Patient age at surgery was classified into 3 groups. Patients <40 years old were classified as *young*, those between 40 and 64 years old as *middle-aged*, and those ≥65 years old as *aged*.

Tumor size

Maximal extrameatal diameter of the tumor was estimated on T1-weighted axial contrast-enhanced magnetic resonance imaging. Tumor size was classified into 3 groups. Tumors ≤15 mm were classified as *small*, those 16–30 mm as *medium*, and those >30 mm as *large*.

Type of skin incision

The *lazy S* and *C-type* skin incisions described above were applied in this series.

Extent of tumor resection

Extent of tumor resection was estimated from intraoperative microscopic findings and postoperative magnetic resonance imaging (MRI). Three groups were classified. *Total or near-total resection* was defined as total tumor clearance or only tumor capsule remaining. Cases in which a small tumor remnant was left on the facial nerve, other cranial nerves or brainstem were considered to represent *subtotal resection*. *Partial resection* was defined as >5% of the tumor left behind.

Surgical duration

Mean surgical time for all patients was calculated according to the surgical records at our hospital.

Surgical duration was classified into 2 groups: less than or equal to the mean surgical time was classified as *short* and over the mean surgical time as *long*.

Hearing preservation

Pure-tone average and speech discrimination scores were determined 1–7 days before surgery and approximately 2 weeks after surgery. Pre- and postoperative hearing results were classified according to the Gardner-Robertson criteria.⁸⁾ A preoperative result of Class 5 was classified as *preoperative deafness*. A postoperative result of Class 4 or better was classified as *preserved*. A preoperative result of Class 4 or better and postoperative result of Class 5 was classified as *not preserved*.

Postoperative facial nerve palsy

Facial nerve outcomes were estimated according to the House-Brackmann system⁹⁾ at the time of hospital discharge. Grade III and over was classified as *postoperative facial nerve palsy*.

Statistical analyses

Statistical analysis was performed using R-2.14.0 software (R Foundation, Vienna, Austria). Kaplan-Meier curves were used to estimate the durations of medication and postoperative headache. Analyses of differences were performed using the log-rank test. Multivariate analysis was performed to identify independent predictors for the duration of postoperative headache with Cox proportional hazards model. Statistical significance was set at the level of $P < 0.05$.

Results

Ninety-seven patients (57 women, 40 men) were investigated in this study. Six patients received stereotactic radiosurgery after tumor removal during the observation period. Mean age at surgery was 51.7 years (range, 23–81 years).

According to the Kaplan-Meier curves, median duration of medication for headache was 81 days and median duration of headache was 641 days (Fig. 2).

[Age] Nineteen patients were classified as *young*, 62 patients as *middle-aged*, and 16 patients as *aged*. **[Tumor size]** Twenty-one patients were classified as showing *small* tumors, 65 as showing *medium* tumors, and 11 as showing *large* tumors. **[Type of skin incision]** Sixty-seven patients underwent surgery using a *lazy S* incision and 30 using a *C-type* incision. **[Extent of tumor resection]** *Total or near-total resection* was achieved in 48 patients, *subtotal resection* in 35 patients, and *partial resection*

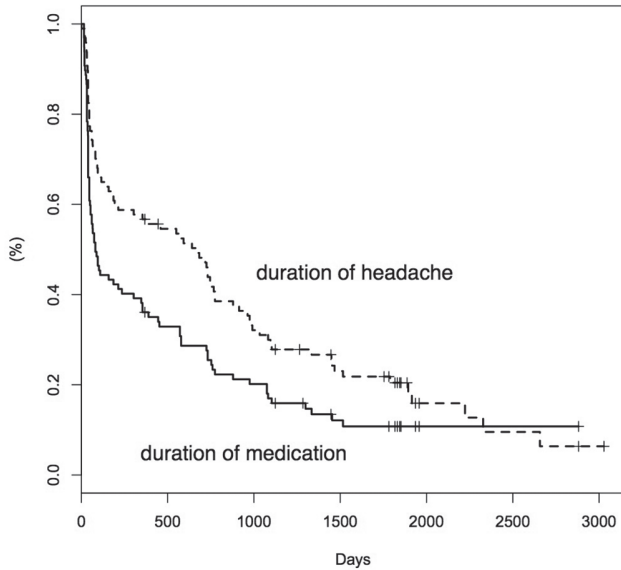


Fig. 2 Kaplan-Meier curve estimating the duration of medication for headache (solid line) and the duration of headache (dashed line).

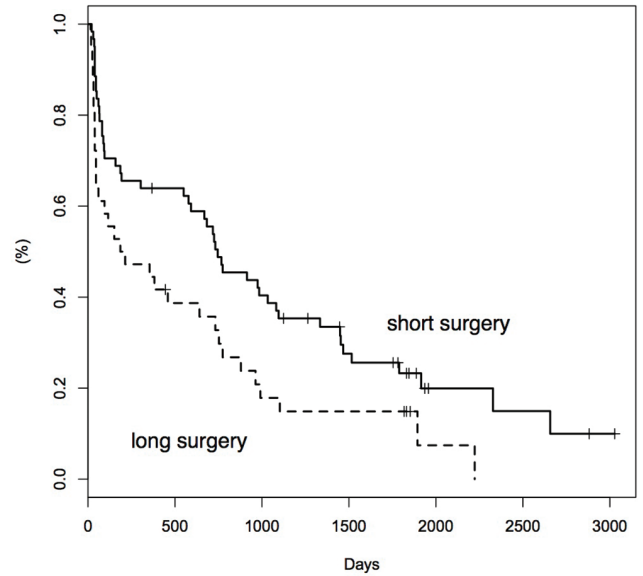


Fig. 4 Kaplan-Meier curve for estimating the duration of headache according to surgical duration. Solid line: short surgery; dashed line: long surgery. Log-rank testing revealed that postoperative headache persisted significantly longer among patients who underwent a short surgical procedure ($P < 0.02$).

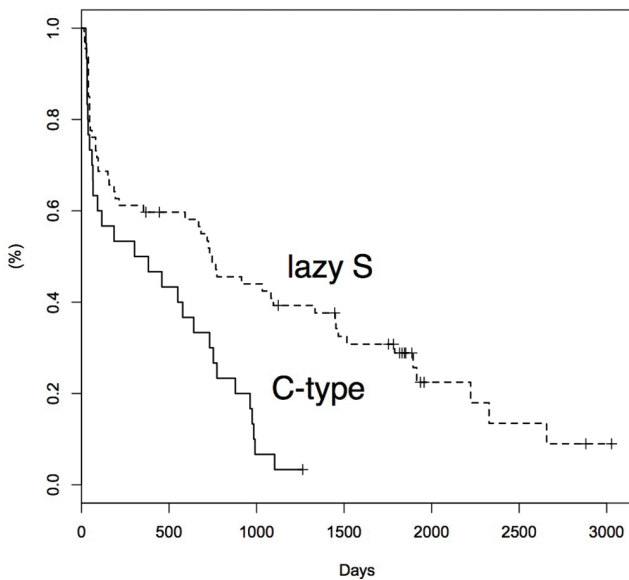


Fig. 3 Kaplan-Meier curve for estimating the duration of headache according to the type of skin incision. Solid line: C-type; dashed line: lazy S. Log-rank testing revealed that headache ended significantly earlier in patients who underwent surgery involving a C-type skin incision ($P < 0.001$).

in 14 patients. **[Surgical duration]** Mean duration of surgery for all patients was 486 min. Sixty-one patients were classified as undergoing short surgery and 36 patients as undergoing long surgery. **[Postoperative facial nerve palsy]** According to the House-Brackmann system at hospital discharge, 10 patients

displayed postoperative facial nerve palsy. **[Hearing preservation]** Forty-two patients were classified as showing preserved hearing, 44 patients as showing not preserved hearing, and 11 patients as showing preoperative deafness.

Log-rank testing revealed that headache ended significantly earlier in patients who underwent surgery involving a C-type skin incision ($P < 0.001$) (Fig. 3). Postoperative headache persisted significantly longer among patients who underwent a short surgical procedure ($P < 0.02$) (Fig. 4). No significant differences in duration of headache were seen for sex, age, tumor size, extent of tumor resection, hearing preservation, or postoperative facial nerve palsy. Multivariate analysis confirmed type of skin incision as a factor independently associated with duration of postoperative headache (Table 1).

Discussion

Postoperative headache after suboccipital craniotomy is a problem with surgery for acoustic neuroma. A previous report found that 32% of patients complained of persisting headache syndrome with a severity of at least 6/10 on the nominal analogue scale at 6 months after surgery.¹⁰⁾ The occurrence of postoperative headache and the failure of patients to return to preoperative levels of activity were associated with each other, and correlated significantly with the risk

Table 1 Multivariate analysis for the duration of postoperative headache

Variable	RR	95% CI	P-value
Age	1.10	0.74–1.65	0.63
Sex	1.23	0.76–1.98	0.39
Tumor size	1.07	0.66–1.73	0.77
Type of skin incision	0.52	0.29–0.95	0.03*
Extent of tumor resection	1.28	0.93–1.77	0.13
Surgical duration	1.31	0.73–2.34	0.37
Hearing preservation	1.27	0.86–1.88	0.24
Postoperative facial nerve palsy	0.85	0.39–1.83	0.68

CI: confidence interval, RR: relative risk, *P-value < 0.05 considered statistically significant.

of postoperative retirement, indicating an important socioeconomic impact of headache in these patients.¹⁰⁾ Surgeons should thus be well acquainted with issues around the duration of postoperative headache. Kaplan-Meier analysis in the present study revealed median durations of medication and headache of 81 and 641 days, respectively. The postoperative headache in this study was distributed at the occiput (98%), forehead, (3%) temple (2%) and eye (2%) ($n = 64$). Fifty-five of 64 patients (91%) complained of symptoms (pressing or tightening quality) similar to tension-type headache and it has been previously reported that this type of headache is prevalent.^{3,6,7)} Headaches such as occipital neuralgia (shooting, stabbing or sharp quality) were also common (19 of 64 cases: 30%), as previously reported.^{10,11)} Two patients complained of unilateral pulsating pain like migraine. During the follow-up period, we classified postoperative headache into only 3 grades, so the severity of headache was differed among individual patients. Types of headache might have changed. Therefore, we cannot determine which type of headache continued for a long period in this study. Patients with grade 2 headache are commonly treated using nonsteroidal anti-inflammatory drugs, and some require anxiolytic drugs. It has been previously reported that local anesthetic blockade of the occipital sensory nerves is effective.¹¹⁾ We also could reduce headache with local anesthetic blockade in 3 cases. Given the median duration of medication of 81 days, the majority of patients did not require any medication within 3 months. The present study defined the period of headache as the number of days between surgery and first achieving a state of no headache at discharge or at the outpatient clinic. The possibility thus remains that postoperative headache may have already been cured before

visiting our hospital. This means that the actual duration of headache was probably shorter than the estimated duration of headache in this study. Postoperative headache would thus have been cured in the majority of patients within 2 years. The information derived from this study should prove of value to both surgeons and patients undergoing surgery. The possibility that headache grade will deteriorate after classification as grade 0 or 1 must be considered. In fact, no cases in this series showed deterioration.

We applied 2 types of skin incision in this series. Selection of skin incision did not depend on preventing postoperative headache. We preferred to use the *lazy S* incision at the beginning of this series. Because the divided skin and muscles occasionally built something like a bank that deepened the operative field, we have more recently preferred to make skin flaps. The *C-type* skin incision has thus recently been applied. A key limitation of this study was thus that the type of skin incision was not randomly selected. Surgical duration of the *C-type* skin incision was longer than the *lazy S* skin incision (Table 2). The reason for

Table 2 Comparison of characteristics between *lazy S* and *C-type* skin incisions

	<i>Lazy S</i> ($n = 67$)	<i>C-type</i> ($n = 30$)
Mean age (years)	52.8	49.1
Sex, n (%)		
Female	38 (57)	19 (63)
Male	29 (43)	11(37)
Tumor size, n (%)		
Small	19 (28)	2 (7)
Medium	45 (67)	20 (67)
Large	3 (4)	8 (27)
Extent of tumor resection, n (%)		
Total or near-total	39 (58)	9 (30)
Subtotal	19 (28)	16 (53)
Partial	9 (13)	5 (17)
Surgical duration, n (%)		
Short	50 (75)	11 (37)
Long	17 (25)	19 (63)
Mean (min)	457	551
Hearing preservation, n (%)		
Preserved	32 (48)	10 (33)
Not preserved	29 (43)	15 (50)
Preoperative deaf	6 (9)	5 (17)
Postoperative facial nerve palsy, n (%)	7 (10)	3 (10)

this must be that many patients having a large tumor underwent using a *C-type* skin incision and that the surgical procedure of the *C-type* skin incision is more complicated than *lazy S* skin incision. The lesser occipital nerve (LON) was transected among these two incisions. On the other hand, handling of the greater occipital nerve (GON) varied, although some variations are seen in the intramuscular course of the GON.¹²⁾ The GON was rarely transected and usually preserved during division of the splenius capitis muscle with the *lazy S* skin incision. However, the GON was retracted and stretched by the self-retaining retractors regardless of preservation. With a *C-type* skin incision, the GON was neither transected nor stretched. Preservation of the GON has previously been reported as independently associated with postoperative headache.¹³⁾ In that report, the *lazy S* skin incision had been applied and the GON had been transected in 66 of 280 patients during the surgery. The incidence of postoperative headache in the GON transected group was significantly lower than the GON preserved group. The authors suggested that retraction and stretching of the GON for preservation might have led to nerve injury and postoperative pain. Other reports have revealed that postoperative headache appeared directly related to the presence of occipital nerve injury.^{11,14)} Considering the fold and stretch of the GON, the *C-type* skin incision barely injures the GON. This seems a likely reason why postoperative headache resolved significantly earlier in patients who underwent surgery involving a *C-type* skin incision. Postoperative muscle atrophy has been previously reported to be significantly reduced with the *C-type* skin incision compared with the *lazy S* skin incision.¹⁵⁾ Although the dissection of muscles in that report differed somewhat compared to our procedure, this may mean that occipital nerve entrapment in the injured muscles is unlikely with the *C-type* skin incision. However, further studies, for example a randomized controlled trial, are needed to find the reason why the *C-type* skin incision is beneficial for reducing the duration of postoperative headache, because the characteristics between *lazy S* and *C-type* skin incisions in our study were very different (Table 2). Other etiologies in addition to injury of the GON have been suggested to involve dural adhesions^{3,16)} and aseptic meningitis.¹⁷⁾ We replaced the bone flap to prevent dural adhesion in all cases in the present study. We irrigated the operative field with artificial cerebrospinal fluid to prevent aseptic meningitis in all cases, regardless of the type of skin incision. Of course, the handling of the GON differs markedly if the muscles are dissected layer by layer through a *lazy S* incision. In that case, the duration of postoperative headache may differ from our results.

Headache persisted longer among patients who underwent a shorter surgical procedure. Surgical duration was not a factor independently associated with duration of postoperative headache. It may be because the group of *lazy S* skin incision included many patients undergoing *short* surgery (Table 2). In general, the longer the duration of surgery, the greater the degree of physiological stress. The result in this study means that physiological stress from surgery is clearly not the sole determinant of postoperative headache. Stress and mental tension have been reported as the most common factors causing tension-type headache.¹⁸⁾ We suggest that patient who undergo long surgeries can easily appreciate the severity of surgery. On the other hand, some patients who undergo short surgeries may underrate the severity of surgery. Tumor size was not a factor associated with the duration of postoperative headache in our study. Small tumor size has been reported to predict postoperative problems with headache.¹⁹⁾ Patients who had a smaller tumor may have underrated the surgery. Discordance between the perceived acceptability of the surgery and subsequent experience would presumably contribute to stress and mental tension, which in turn would contribute to postoperative headache. A clear comprehension of the scheduled surgery may thus be an important factor in postoperative headache, although the mechanisms remain unclear.

The occurrence of postoperative headache correlated significantly with preoperative headache and the number of perioperative complications.^{10,19)} We excluded patients having preoperative headache. Some of the preoperative headaches are probably unrelated to the tumor. The purpose of this study is to estimate duration of postoperative headache, or surgery-related headache. If we confuse non surgery-related headache for postoperative headache, we cannot correctly analyze the duration of postoperative headache. Low intracranial pressure condition by postoperative cerebrospinal fluid leakage may affect postoperative headache. Our study excluded patients who had received additional surgical treatments for cerebrospinal fluid leakage or wound infection. There was no case with cerebrospinal fluid retention under the skin at hospital discharge. Therefore, we suspect that low intracranial pressure condition by cerebrospinal fluid leakage did not affect postoperative headache for a long time. Postoperative facial nerve palsy and hearing preservation were not independently associated with duration of postoperative headache. We cannot say for certain whether preoperative headache and the number of perioperative complications can help predict the duration of postoperative headache. There was no case treated for cervical spondylosis in this study. Before the surgery, we checked whether all patients have any symptom

under the same degree neck flexion as during surgery. There was no case having any symptom. However, further studies are needed to estimate other possible factors including cervical spine alignment, tinnitus, postoperative muscle atrophy and so on. In any case, multiple factors are probably involved in postoperative headache. Our study revealed that the *C-type* skin incision is likely beneficial for reducing the duration of postoperative headache.

Conclusion

Postoperative headache after suboccipital craniotomy is a problem for acoustic neuroma surgery. Kaplan-Meier analysis in this study revealed median durations of medication and headache as 81 and 641 days, respectively. Headache resolved significantly earlier in patients who underwent surgery using a *C-type* skin incision. Multivariate analysis confirmed type of skin incision as a factor independently associated with duration of postoperative headache. Thus, the *C-type* skin incision seems beneficial for reducing the duration of postoperative headache although headache persisted in a small number of patients.

Conflicts of Interest Disclosure

All authors have no conflicts of interest with regard to the manuscript submitted. All authors who are members of the Japan Neurosurgical Society (JNS) have registered online Self-reported COI Disclosure Statement Forms through the website for JNS members.

References

- 1) Hanson MB, Glasscock ME, Brandes JL, Jackson CG: Medical treatment of headache after suboccipital acoustic tumor removal. *Laryngoscope* 108: 1111–1114, 1998
- 2) Harner SG, Beatty CW, Ebersold MJ: Headache after acoustic neuroma excision. *Am J Otol* 14: 552–555, 1993
- 3) Schessel DA, Rowed DW, Nedzelski JM, Feghali JG: Postoperative pain following excision of acoustic neuroma by the suboccipital approach: observations on possible cause and potential amelioration. *Am J Otol* 14: 491–494, 1993
- 4) Silverstein H, Norrell H, Haberkamp T: A comparison of retrosigmoid IAC, retrolabyrinthine, and middle fossa vestibular neurectomy for treatment of vertigo. *Laryngoscope* 97: 165–173, 1987
- 5) Silverstein H, Norrell H, Smouha E, Jones R, Rosenberg S: An evolution of approach in vestibular neurectomy. *Otolaryngol Head Neck Surg* 102: 374–381, 1990
- 6) Pedrosa CA, Ahern DK, McKenna MJ, Ojemann RG, Acquadro MA: Determinants and impact of headache after acoustic neuroma surgery. *Am J Otol* 15: 793–797, 1994
- 7) Ryzenman JM, Pensak ML, Tew JM Jr: Headache: a quality of life analysis in a cohort of 1,657 patients undergoing acoustic neuroma surgery, results from the acoustic neuroma association. *Laryngoscope* 115: 703–711, 2005
- 8) Gardner G, Robertson JH: Hearing preservation in unilateral acoustic neuroma surgery. *Ann Otol Rhinol Laryngol* 97: 55–66, 1988
- 9) House JW, Brackmann DE: Facial nerve grading system. *Otolaryngol Head Neck Surg* 93: 146–147, 1985
- 10) Schankin CJ, Gall C, Straube A: Headache syndromes after acoustic neuroma surgery and their implications for quality of life. *Cephalalgia* 29: 760–771, 2009
- 11) Ducic I, Felder JM III, Endara M: Postoperative headache following acoustic neuroma resection: occipital nerve injuries are associated with a treatable occipital neuralgia. *Headache* 52: 1136–1145, 2012
- 12) Tubbs RS, Watanabe K, Loukas M, Cohen-Gadol AA: The intramuscular course of the greater occipital nerve: novel findings with potential implications for operative interventions and occipital neuralgia. *Surg Neurol Int* 5: 155, 2014
- 13) Garzon-Muvdi T, Jackson C, See AP, Woodworth GF, Tamargo RJ: Preservation of the greater occipital nerve during suboccipital craniectomy results in a paradoxical increase in postoperative headaches. *Neurosurgery* 76: 435–440; discussion 440, 2015
- 14) Silverman DA, Hughes GB, Kinney SE, Lee JH: Technical modifications of suboccipital craniectomy for prevention of postoperative headache. *Skull Base* 14: 77–84, 2004
- 15) Ogiwara T, Goto T, Aoyama T, et al.: Relationship between muscle dissection method and postoperative muscle atrophy in the lateral suboccipital approach to vestibular schwannoma surgery. *World Neurosurg* 94: 426–431, 2016
- 16) Catalano PJ, Jacobowitz O, Post KD: Prevention of headache after retrosigmoid removal of acoustic tumors. *Am J Otol* 17: 904–908, 1996
- 17) Schaller B, Baumann A: Headache after removal of vestibular schwannoma via the retrosigmoid approach: a long-term follow-up-study. *Otolaryngol Head Neck Surg* 128: 387–395, 2003
- 18) Torelli P, Abrignani G, Castellini P, Lambro G, Manzoni GC: Human psyche and headache: tension-type headache. *Neurol Sci* 29 Suppl 1: S93–S95, 2008
- 19) Levo H, Pyykkö I, Blomstedt G: Postoperative headache after surgery for vestibular schwannoma. *Ann Otol Rhinol Laryngol* 109: 853–858, 2000

Address correspondence to: Noritaka Aihara, MD, Department of Neurosurgery, Nagoya City University Medical School, Kawasumi 1, Mizuho-cho, Mizuho-ku, Nagoya, Aichi 467-8601, Japan.
e-mail: aihara@med.nagoya-cu.ac.jp