

Research Article

Five Years Follow-Up of Acrysof Cachet® Angle-Supported Phakic Intraocular Lens Implantation for Myopia Correction

Aytan Musayeva ^{1,2}, Jana C. Riedl ¹, Adrian Gericke ¹ and Urs Vossmerbaeumer ¹

¹Department of Ophthalmology, University Medical Center, Johannes Gutenberg-University Mainz, Langenbeckstr. 1, Mainz 55131, Germany

²Schepens Eye Research Institute, Massachusetts Eye and Ear, Department of Ophthalmology, Harvard Medical School, Boston, MA 02114, USA

Correspondence should be addressed to Aytan Musayeva; ayten.musayeva@yahoo.com

Received 7 April 2021; Revised 4 November 2021; Accepted 13 December 2021; Published 26 March 2022

Academic Editor: In s Contreras

Copyright © 2022 Aytan Musayeva et al. This is an open access article distributed under the Creative Commons Attribution License, which permits unrestricted use, distribution, and reproduction in any medium, provided the original work is properly cited.

Purpose. The Acrysof Cachet® angle-supported phakic intraocular lens (pIOL) (Alcon Laboratories, Inc., Fort Worth, TX) is designed to correct high refractive errors in human eyes. The aim of this study was to evaluate the outcome of AcrySof Cachet® angle-supported pIOL implantation with particular regard to efficacy and safety of the implant over a 60-month follow-up period. **Design.** Retrospective consecutive clinical case study. **Methods.** Prior to pIOL implantation, patients had a complete ophthalmologic examination including objective and subjective refraction, uncorrected visual acuity (UCVA) and corrected distance visual acuity (CDVA), endothelial cells density (ECD), slit lamp photography, optical coherence tomography (OCT), Scheimpflug digital videokeratometry, optical biometry, slit lamp examination, intraocular pressure (IOP) measurement, and pupillometry. Postoperatively, patients received yearly a complete eye examination. **Results.** Thirty-one eyes of 16 patients were included in this study. The mean age was 36.2 ± 8.1 years. UCVA (logMAR) improved from 1.33 ± 0.20 before surgery to 0.08 ± 0.14 one year after surgery and was 0.20 ± 0.20 five years after surgery. CDVA (logMAR) improved from 0.10 ± 0.10 before surgery to 0.05 ± 0.13 one year after surgery and was 0.04 ± 0.14 five years postoperatively. The mean percentage of endothelial cells loss (ECL) was 11.51% over the first year and 15.95% five years after surgery. There were no intraoperative complications in any of the eyes. **Conclusions.** Our results up to five years after implantation of the AcrySof Cachet® angle-supported pIOL demonstrated very good outcomes in all above shown measurements, including CDVA, UCVA, and ECD. However, since major endothelial cell loss may occur in some patients with this type of pIOL, regular follow-up visits are required.

1. Introduction

Phakic intraocular lenses (pIOLs) have been used for more than 60 years for correction of moderate to high ametropia [1, 2]. However, most of the clinically tested models had to be withdrawn from the market due to complications in the medium- or long-term, especially due to loss of corneal endothelial cells and only a few are still used today [3–10]. Two types of pIOLs differing with regard to their level of placement within the eye may be distinguished. First, there are posterior chamber pIOLs, which are placed in the ciliary sulcus, such as the Phakic Refractive Lens (PRL®, Carl Zeiss Meditec, Jena, Germany), no longer available [11–13], and

the implantable collamer lens (ICL®, Staar Surgical AG, Nidau, Switzerland) [14]. Second, anterior chamber intraocular lenses are also in use, of which some are fixed in the iris (Artisan®, Artiflex®, Verisyse®, Veriflex®, Ophtec BV, The Netherlands) while other are angle-supported (AcrySof Cachet®, Alcon, Fort Worth, TX, USA), no longer available [15, 16].

The AcrySof Cachet® angle-supported pIOL (Alcon Laboratories) is a single-piece, foldable, soft acrylic lens (acrylate/methacrylate copolymer) with a 6.00 mm diameter optic and with an overall length of 12.5 to 14.0 mm and a dioptric range of -6.00 to -16.50 D in 0.5 D steps [17, 18]. Made from foldable hydrophobic acrylate, the haptics are

easily foldable and the IOL can be inserted through a 2.6 mm incision, which reduces the risk of damage to angle structures and pupil ovalization [19]. A good level of refractive stability, predictability, and safety has previously been reported for the pIOL [17, 19–21]. Compared to other surgical possibilities to correct high refractive errors, the implantation of a pIOL has several advantages [22–32]. First, the crystalline lens retains its function, and vitreoretinal complications are less likely to occur [33, 34]. Second, the pIOL is removable, which allows for reversibility of the preoperative condition [35, 36]. Furthermore, refraction is stable and the method is adjustable with complementary corneal refractive procedures [37–39]. Despite many advantages, pIOL surgery has a wide spectrum of potential long-term complications, such as endothelial cell loss, intraocular inflammation, pupil distortion, cataract formation, and secondary glaucoma. Due to concerns about endothelial cells loss in a group of 1323 eyes implanted, Alcon voluntarily discontinued the production of this intraocular lens in 2014. This study aims to critically evaluate the performance of the Cachet® pIOL, notably concerning predictability and stability of the refractive results, the risk profile (safety), and patient satisfaction on a long-term follow-up basis.

2. Methods

Thirty-one eyes of 16 patients, who required surgical correction of high myopia to achieve spectacle independence between June 2010 and July 2012 at the Department of Ophthalmology, University Medical Center Mainz, were included in this study. The mean age of the patients was 36.19 ± 8.093 years, with a range from 23 to 50 years. The mean preoperative value of refraction, spherical equivalent, was -9.669 ± 2.730 D (min. -5.500 D, max. -16.000 D). The mean lens power of implanted IOLs was -10.240 ± 2.422 D, ranging from -6.000 to -15.500 D.

The inclusion criteria were age ≥ 18 years, stable refraction for at least 1 year, endothelial cells density (ECD) >2200 cells/mm², mesopic pupil size <7.5 mm, anterior chamber depth (ACD) >3.0 mm, wish of spectacle independence, and ametropia not sufficiently correctable with excimer laser surgery.

Contraindications for implantation included ACD <3.0 mm, insufficient ECD (<2200 /mm²), anomaly of the iris or pupil, active infectious disease, recurrent or chronic uveitis, clinically significant cataract, posterior segment pathologies, such as macular degeneration or other macular and retinal abnormalities, and glaucoma.

Prior to pIOL implantation, patients received a complete ophthalmologic evaluation including

Uncorrected (UCVA) and corrected distance visual Scheimpflug acuity (CDVA)

Subjective and objective refraction

Measurement of ECD (SP-3000 P, Topcon, Willich, Germany)

Scheimpflug digital videokeratometry (Pentacam®, Oculus Wetzlar, Germany) was performed with the measurement of

- (1) Corneal topography and corneal thickness
- (2) ACD
- (3) Angle-to-angle distance.

Axial length and ACD measurement (IOL Master (Carl Zeiss Meditec AG, Jena, Germany)

Slit lamp and a fundus examination (Haag-Streit slit lamp, Bern)

Measurement of IOP (Goldmann applanation tonometry, Haag-Streit AG, Köniz, Switzerland)

Pupillometry (Colvard Pupillometer, Glendora, USA)

Postoperative follow-up visits were scheduled at day 1, week 1, and month 1, 3, 6, 12, 24, 36, 48, and 60 including the following examinations at given points of time:

UCVA and CDVA

Subjective and objective refraction

Measurement of ECD

Anterior segment photography (rotational stability and pupil geometry)

Anterior segment optical coherence tomography (OCT, using OCT Spectralis, Heidelberg Engineering, Heidelberg, Germany) was performed to measure

- (1) Position of the implant in the anterior chamber;
- (2) Position of the haptics in the angle;
- (3) Distance between the posterior surface of the pIOL and the anterior surface of the crystalline lens.

Scheimpflug digital videokeratometry was used to measure

- (1) Distance between the anterior surface of the pIOL and the central corneal endothelium;
- (2) ACD;

Slitlamp assessment and a fundus examination

Measurement of IOP (Goldmann applanation tonometry)

We used a questionnaire developed at our department to assess patient satisfaction after pIOL implantation.

Surgical procedure and postoperative treatment: surgery was performed under topical anesthesia, implanting one pIOL into one eye per session. All surgeries were performed by the same experienced ophthalmic surgeon (UV) following the manufacturer's recommendations. The pIOL was implanted through a 3.2 mm incision using the proprietary shooter system. Pupil constriction was obtained by topical administration of 0.5% pilocarpine eye drops and endothelial protection was ascertained using Viscoat® (Alcon, Ophthalmic Viscosurgical Device). The implantation process followed exactly the scheme as proposed by the manufacturer. Intraoperative viscoelastic removal was performed with bimanual irrigation/aspiration handpieces with low bottle height (infusion pressure approximately 25 mmHg). Complete removal was verified meticulously. Two hours postoperatively, all patients were subject to slit

lamp examination and applanation tonometry of intraocular pressure. In all cases, readings were in physiological range without need of surgical revision or application of IOP-lowering medication. Two hours after surgery, the patient was visited to ensure complete removal of the viscoelastic material by IOP measurement.

Postoperative treatment contained of unpreserved ofloxacin eye drops 4 times daily for 5 days and prednisolone eye drops 3 times daily for 3 weeks. The patients received yearly a complete eye examination including the above given measurements and also a photograph to control position, rotational stability, and pupil geometry (Figure 1).

2.1. Statistical Analysis. Power calculation was conducted for ECL based on previously published data [40]. For the 31 eyes included in the present study, the power was 82% and 97% for comparison of preoperative with one year postoperative and five years preoperative results, respectively (paired *t*-test and $\alpha=0.05$). For comparisons of postoperative values with the preoperative value, a paired *t*-test was used. Since each of the five postoperative time points was compared with the preoperative value, a correction for multiple comparisons was made by the Bonferroni correction, which resulted in a reduction of critical α to 0.01.

3. Results

3.1. Visual Acuity. UCVA (logMAR) improved from 1.33 ± 0.19 before surgery to 0.08 ± 0.14 one year after surgery and was 0.20 ± 0.20 five years after surgery (** $p < 0.0001$ for each year compared to preoperative values, Figure 2(a)). CDVA (logMAR) improved from 0.10 ± 0.10 before surgery to 0.05 ± 0.13 one year after surgery and was 0.04 ± 0.14 five years postoperatively. Respective *p* values were $p = 0.0339$ (one year after surgery versus preoperative), $p = 0.0293$ (two years after surgery versus preoperative), $*p = 0.0014$ (three years after surgery versus preoperative), $*p = 0.0085$ (four years after surgery versus preoperative), and $p = 0.0322$ (five years after surgery versus preoperative) (Figure 2(b)). In none of the patients, a decrease of visual acuity (UCVA and CDVA) has been observed.

3.2. ECD. ECD was 2753 ± 322 cells/mm² preoperatively, 2436 ± 503 cells/mm² one year postoperatively, and 2314 ± 531 cells/mm² five years postoperatively, which corresponds to an endothelial cell loss (ECL) of 11.51% over the first year and of 15.95% after 5 years (Figure 3). Respective *p* values were $p = 0.0159$ (one year after surgery versus preoperative), $*p = 0.0034$ (two years after surgery versus preoperative), $*p = 0.0022$ (three years after surgery versus preoperative), $*p = 0.0064$ (four years after surgery versus preoperative), and $*p = 0.0071$ (five years after surgery versus preoperative). The percentage of the eyes with an ECL of 25% or greater of preoperative ECD was 6.45% (2 of 31 eyes) [41]. In all other cases, total ECL was under 25%. The percentage of eyes with final (at the end of the follow-up period) ECD lower than 1500 cells/mm [2] was 3.23% (1 of

31 eyes). The percentage of eyes with postoperative annual ECL (excluding surgical trauma) higher than the expected physiological maximum (i.e., >1.6% loss of annual ECD) [7] was 22.58% (7 of 31 eyes).

3.3. IOP. The mean IOP was 14.00 ± 2.39 mmHg before surgery, 14.36 ± 2.11 mmHg one year after surgery, and 18.92 ± 3.52 mmHg 5 years postoperatively. No marked IOP changes were observed during the whole postoperative period (Figure 4). Respective *p* values were $p = 0.6454$ (one year after surgery versus preoperative), $p = 0.2247$ (two years after surgery versus preoperative), $p = 0.1509$ (three years after surgery versus preoperative), $p = 0.3523$ (four years after surgery versus preoperative), and $p = 0.0991$ (five years after surgery versus preoperative).

3.4. Complications. There were no intraoperative complications in any of the eyes. However, in the first 24 hours postoperatively, two patients had a slightly elevated IOP of 23 mmHg, which dropped back to normal levels without any therapy within the following days. In one patient (43 years old when operated), there was a profound ECL of 63.82% after 5 years. The anterior chamber situation was normal without any inflammation. The distance between the pIOL and the lens as well as the position of the pIOL in the anterior chamber was stable, and the rotation was $<5^\circ$.

Because of the marked ECL, we decided to explant the Cachet® pIOL with immediate sequential implantation of an ICL®.

Another patient (31 years old when operated), who had undergone Cachet® pIOL implantation in both eyes, experienced an IOP elevation up to 56 mmHg and 35 mmHg on the right and left eye, respectively, in the 5-years follow-up. After topical therapy with timolol/dorzolamide eye drops 2 times daily and clonidine eye drops 3 times daily for both eyes, the IOP values were between 13 mmHg and 20 mmHg in the right eye and between 12 mmHg and 19 mmHg in the left eye. The anterior chamber situation was normal without any inflammation in this patient. Rotation of the Cachet® pIOL in both eyes was $<5^\circ$. The distance between the pIOL and the lens on the left eye was significantly smaller than on the right eye, but gonioscopy showed an open, normally appearing anterior chamber angle (Schaffer grade 3). Fundoscopic exam did not reveal any glaucomatous cupping of the optic nerve head. The patient is in regular outpatient examination, and the IOP is within normal limits with the therapy reported above. One patient (35 years old when operated), who received Cachet® pIOL bilaterally, was not satisfied with the postoperative UCVA. Therefore, we decided to perform femtosecond-assisted laser in-situ keratomileusis (Femto-LASIK) ten months after pIOL implantation in both eyes. The refraction after pIOL implantation, which needed correction was sph. -0.75 D cyl -0.25 D/ 77° on the right eye and sph. -0.5 D cyl. -0.5 D/ 35° on the left eye. In none of the patients signs of pigmentary dispersion (pigmentary Tyndall or Krukenberg spindle) have been found in the follow-up examinations. Acute postoperative anterior uveitis was not observed. Pupil ovalization

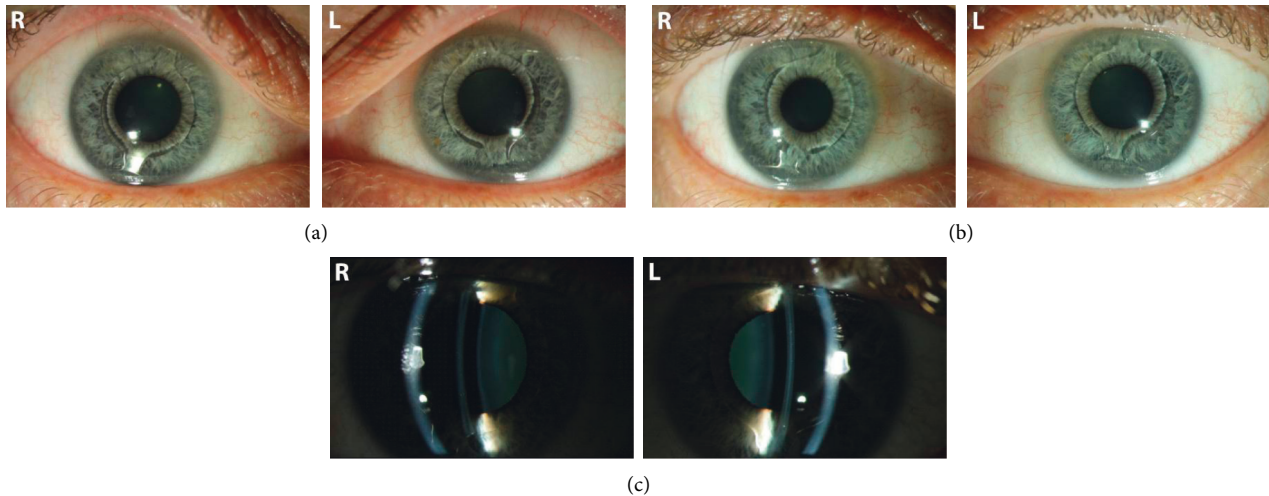


FIGURE 1: Slit lamp images of the AcrySof Cachet angle-supported pIOL in the anterior chamber postoperatively. (a) 1 year, right (left image column) and left (right image column) eye. (b) Five years postoperatively, in the same patient. Note the slight rotation of the IOL especially in the left eye (right image column). (c) Vertical slit lamp image for control and exclusion of any contact between the pIOL, the cornea, or the crystalline lens.

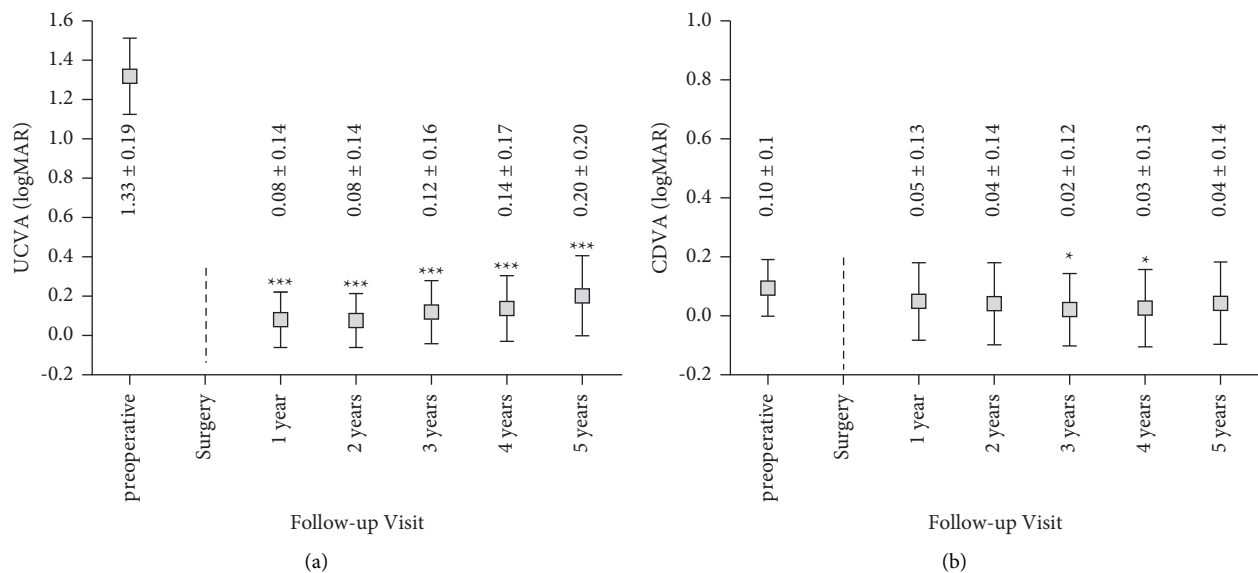


FIGURE 2: (a) UCVA pre- and up to 5 years after pIOL implantation. Values are presented as mean \pm SD (** $p < 0.0001$). (b) CDVA pre- and up to 5 years postoperatively. Values are presented as mean \pm SD (* $p < 0.01$).

was not observed; pupil shape and motility were preserved in all patients. No iris synechiae, transillumination defects, or sphincter erosions were found. No opacities of the crystalline lens or decrease of the crystalline lens transparency could be found in any patient. There was no incidence of retinal detachment.

3.5. Patient Satisfaction. Three patients reported on night halos, two patients on increased light sensitivity at night, and one patient on glare 1 year postoperatively. With time, patients seemed to get used to these symptoms and it was not significant at the 5-year follow-up. As part of a satisfaction questionnaire, patients were asked if they would have the

same pIOL implanted again, and at the 5-year postoperative visit, this question was positively answered by 94% ($n = 15$ of 16, Table 1).

4. Discussion

Our study demonstrated a high efficacy of Cachet® angle-supported pIOL implantation in correction of high refractive errors. We observed an increase in both UCVA and CDVA, which is in line with previous studies [42, 43]. We also compared the results of this study with other reports to point out the reasons of the most common complications.

Damage to the anterior chamber structures, especially to the corneal endothelium by the pIOL is the most specific

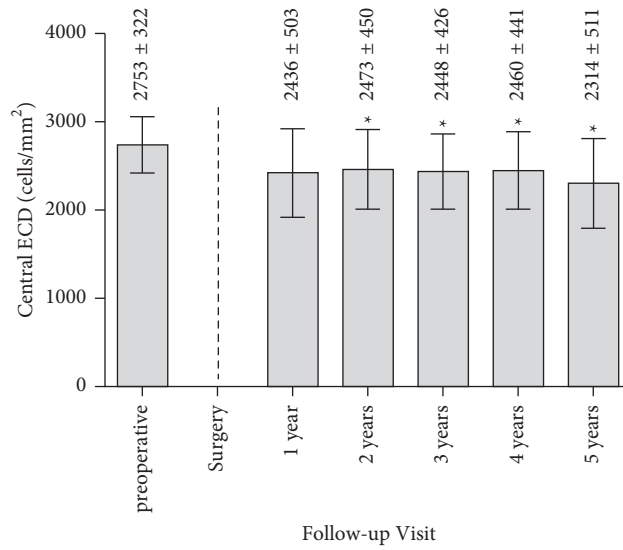


FIGURE 3: Individual ECD pre- and up to 5 years postoperative. Values are presented as mean ± SD (**p* < 0.01).

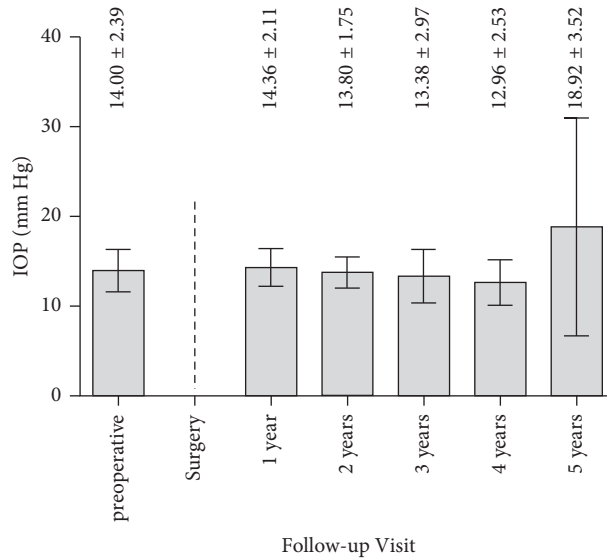


FIGURE 4: IOP pre- and up to 5 years postoperative.

TABLE 1: Results of patient questionnaire.

Questions	Number of patients (<i>n</i>)	Rate (%)
Night halos	3	18
Glare	2	12
Light sensitivity	3	18
Vision satisfaction when driving a car	16	100
Twilight vision satisfaction	15	94
Night vision satisfaction	14	88
Patients, who would recommend this pIOL to others	15	94

complication. In a 7-year follow-up study, Alio et al. revealed an ECL of 3.8% in the first year, but of only 0.5% per year after the second postoperative year [44]. Kohnen et al. also reported on ECL in a 5 year follow-up after Cachet® pIOL implantation [20]. Six months after surgery, mean acute

reduction in central ECL was 3.3%, but only 1.3% between the 6-month and 5-year visits, respectively. In a recently published long-term analysis with the AcrySof Cachet® angle-supported pIOL, an ECL of greater than 30% from the preoperative baseline at any time after implantation affected

8.0% of all eyes and resulted in pIOL explantation in 3.1% of all eyes [21]. In our study, we found an average ECL of 11.51% between the preoperative measurement and the measurement 1 year postoperatively. During the following years, additional ECL was only minor. ECD was reduced by 15.95% five years after surgery compared to the measurement before surgery, suggesting that the surgical procedure was the main cause of ECL, which is in agreement with previous findings [45].

Pupil ovalization is regarded as a result of excessive continuous pressure upon the anterior chamber angle from the haptics. It is not only a cosmetically disturbing problem, but also causes glare. Alio et al. reported on pupil ovalization in 5.9% of patients, two of whom needed pIOL explantation [44]. Perez-Santonja et al. revealed that most eyes (71.1%) with Cachet® pIOL did not show rotation of more than 15° and it was not clinically relevant in any of the cases [46]. Retinal complications following pIOL implantation in patients with extreme myopic eyes [47, 48] due to vitreous instability caused by the surgery have also been reported in previous studies. In our patient group, there was no case of pupil ovalization or of posterior segment changes, such as retinal detachment. Uveitis was also not observed in our study although it has previously been shown to be one of the complications of pIOL implantation [49]. In addition, other adverse events previously associated with pIOLs, including endophthalmitis, hyphema, hypopyon, pIOL dislocation, or pupillary block were not observed in the present study. The crystalline lens remained clear in all patients. Postoperative elevation of IOP, a known complication of pIOL implantation [50], was seen in only one patient in our study. The IOP was in normal limits with topical therapy, and no glaucomatous cupping of the optic nerve was observed. Of the patients that had received the AcrySof Cachet® angle-supported pIOL in our study, 94% became spectacle independent, and this result remained stable for the whole follow-up period.

In conclusion, the AcrySof Cachet® pIOL showed excellent results in our retrospective study. There was only one case of IOL explantation because of marked ECL, which is of similar extent as in the recently published long-term analysis of Kohnen et al. [21]. Our results up to 5 years after implantation of the AcrySof Cachet® angle-supported pIOL demonstrated very good outcomes in all the above shown measurements, including CDVA, UCVA, ECD, and IOP. As already mentioned above, Alcon decided to discontinue the production of this phakic intraocular lens in 2014 due to ECL. Therefore, regular follow-up visits with regular ECD examinations are necessary for those patients, who had this type of pIOL implanted.

Data Availability

The data used to support the findings of this study are available on request.

Conflicts of Interest

The authors declare that they have no conflicts of interest.

References

- [1] C. F. Lovisolio and D. Z. Reinstein, "Phakic intraocular lenses," *Survey of Ophthalmology*, vol. 50, no. 6, pp. 549–587, 2005.
- [2] H. B. Grabow, "Phakic IOL terminology," *Journal of Cataract and Refractive Surgery*, vol. 25, no. 2, pp. 159–160, 1999.
- [3] I. B. Sayman Muslubas, B. Kandemir, A. Y. Aydin Oral, S. Kugu, and M. Dastan, "Long-term vision-threatening complications of phakic intraocular lens implantation for high myopia," *International Journal of Ophthalmology*, vol. 7, pp. 376–380, 2014.
- [4] V. Galvis, A. Tello, N. I. Carreño, R. D. Berrospi, C. A. Niño, and M. O. Cuadros, "Endothelial loss with AcrySof Cachet angle-supported phakic lens," *Archivos de la Sociedad Española de Oftalmología*, vol. 92, no. 9, pp. e53–e54, 2017.
- [5] T. Kohnen, "Phakic intraocular lenses: where are we now?" *Journal of Cataract and Refractive Surgery*, vol. 44, no. 2, pp. 121–123, 2018.
- [6] T. Kohnen, D. Kook, M. Morral, and J. L. Güell, "Phakic intraocular lenses," *Journal of Cataract and Refractive Surgery*, vol. 36, no. 12, pp. 2168–2194, 2010.
- [7] V. Galvis, J. F. Villamil, M. F. Acuña et al., "Long-term endothelial cell loss with the iris-claw intraocular phakic lenses (Artisan®)," *Graefes Archive for Clinical and Experimental Ophthalmology*, vol. 257, no. 12, pp. 2775–2787, 2019.
- [8] J. Pechmėja, J. Guinguet, J. Colin, and P. S. Binder, "Severe endothelial cell loss with anterior chamber phakic intraocular lenses," *Journal of Cataract and Refractive Surgery*, vol. 38, no. 7, pp. 1288–1292, 2012.
- [9] J. L. Alio, A. Abbouda, P. Peña-Garcia, and S. Huseynli, "Follow-up study of more than 15 Years of an angle-supported phakic intraocular lens model (ZB5M) for high myopia," *JAMA Ophthalmology*, vol. 131, no. 12, pp. 1541–1546, 2013.
- [10] J. L. Alió, B. T. Toffaha, P. Peña-Garcia, L. M. Sádaba, and R. I. Barraquer, "Phakic intraocular lens explantation: causes in 240 cases," *Journal of Refractive Surgery*, vol. 31, no. 1, pp. 30–35, 2015.
- [11] R. J. Pérez-Cambrodí, F. J. Blanes-Mompó, S. García-Lázaro, D. P. Piñero, A. Cerviño, and R. Brautaset, "Visual and optical performance and quality of life after implantation of posterior chamber phakic intraocular lens," *Graefes Archive for Clinical and Experimental Ophthalmology*, vol. 251, no. 1, pp. 331–340, 2013.
- [12] R. J. Pérez-Cambrodí, D. P. Piñero, T. Ferrer-Blasco, A. Cerviño, and R. Brautaset, "The posterior chamber phakic refractive lens (PRL): a review," *Eye*, vol. 27, no. 1, pp. 14–21, 2013.
- [13] D. M. Portaliou, G. D. Kymionis, S. I. Panagopoulou, M. I. Kalyvianaki, M. A. Grentzelos, and I. G. Pallikaris, "Long-term results of phakic refractive lens implantation in eyes with high myopia," *Journal of Refractive Surgery*, vol. 27, no. 11, pp. 787–791, 2011.
- [14] G.-L. Liang, J. Wu, J.-T. Shi, J. Liu, F.-Y. He, and W. Xu, "Implantable collamer lens versus iris-fixed phakic intraocular lens implantation to correct myopia: a meta-analysis," *PLoS One*, vol. 9, no. 8, Article ID e104649, 2014.
- [15] S. R. Jonker, T. J. M. Berendschot, I. Y. Saelens, N. C. Bauer, and R. M. A. Nuijts, "Phakic intraocular lenses: an overview," *Indian Journal of Ophthalmology*, vol. 68, no. 12, pp. 2779–2796, 2020.
- [16] J. L. Güell, M. Morral, D. Kook, and T. Kohnen, "Phakic intraocular lenses," *Journal of Cataract and Refractive Surgery*, vol. 36, no. 11, pp. 1976–1993, 2010.

- [17] T. Kohnen, W. A. Maxwell, and S. Holland, "Correction of moderate to high myopia with a foldable, angle-supported phakic intraocular lens," *Ophthalmology*, vol. 123, no. 5, pp. 1027–1035, 2016.
- [18] D. S. Lomoriello, M. Lombardo, L. Gualdi et al., "Stability of casket phakic intraocular lens position during 6-months follow-up," *The Open Ophthalmology Journal*, vol. 7, no. 1, pp. 20–23, 2013.
- [19] J. L. Alió, D. P. Piñero, E. Sala, and F. Amparo, "Intraocular stability of an angle-supported phakic intraocular lens with changes in pupil diameter," *Journal Of Cataract and Refractive Surgery*, vol. 36, no. 9, pp. 1517–1522, 2010.
- [20] T. Kohnen, M. C. Knorz, B. Cochener et al., "AcrySof phakic angle-supported intraocular lens for the correction of moderate-to-high myopia: one-year results of a multicenter European study," *Ophthalmology*, vol. 116, no. 7, pp. 1314–1321, 2009.
- [21] T. Kohnen, L. LaFontaine, R. Andrew, and I. Study, "Long-term safety follow-up of an anterior chamber angle-supported phakic intraocular lens," *Journal Of Cataract and Refractive Surgery*, vol. 43, no. 9, pp. 1163–1170, 2017.
- [22] M. F. Goldberg, "Clear lens extraction for axial myopia," *Ophthalmology*, vol. 94, no. 5, pp. 571–582, 1987.
- [23] R. Montés-Micó and J. L. Alió, "Distance and near contrast sensitivity function after multifocal intraocular lens implantation," *Journal of Cataract and Refractive Surgery*, vol. 29, no. 4, pp. 703–711, 2003.
- [24] J. T. Holladay, J. P. Gills, J. Leidlein, and M. Cherchio, "Achieving emmetropia in extremely short eyes with two piggyback posterior chamber intraocular lenses," *Ophthalmology*, vol. 103, no. 7, pp. 1118–1123, 1996.
- [25] J. T. Holladay, P. A. Piers, G. Koranyi, M. van der Mooren, and N. E. S. Norrby, "A new intraocular lens design to reduce spherical aberration of pseudophakic eyes," *Journal of Refractive Surgery*, vol. 18, no. 6, pp. 683–691, 2002.
- [26] O. Gris, J. L. Güell, F. Manero, and A. Müller, "Clear lens extraction to correct high myopia," *Journal of Cataract and Refractive Surgery*, vol. 22, no. 6, pp. 686–689, 1996.
- [27] R. Donoso and A. Rodríguez, "Piggyback implantation using the AMO array multifocal intraocular lens," *Journal of Cataract and Refractive Surgery*, vol. 27, no. 9, pp. 1506–1510, 2001.
- [28] M. Kühle, B. Seitz, A. Langenbacher, P. Martus, and N. X. Nguyen, "Stability of refraction, accommodation, and lens position after implantation of the 1CU accommodating posterior chamber intraocular lens," *Journal of Cataract and Refractive Surgery*, vol. 29, no. 12, pp. 2324–2329, 2003.
- [29] I. E. Lehrer, M. R. Tetz, K. Dumke, and P. Ruokonen, "Refractive lensectomy and accommodating lens implantation in a case of hyperopia," *Journal of Cataract and Refractive Surgery*, vol. 29, no. 12, pp. 2430–2434, 2003.
- [30] L. Mastropasqua, L. Toto, M. Nubile, G. Falconio, and E. Ballone, "Clinical study of the 1CU accommodating intraocular lens," *Journal of Cataract and Refractive Surgery*, vol. 29, no. 7, pp. 1307–1312, 2003.
- [31] T. Moller-Pedersen, M. Vogel, H. F. Li, W. M. Petroll, H. D. Cavanagh, and J. V. Jester, "Quantification of stromal thinning, epithelial thickness, and corneal haze after photorefractive keratectomy using in vivo confocal microscopy," *Ophthalmology*, vol. 104, pp. 360–368, 1997.
- [32] S. Marcos, "Aberrations and visual performance following standard laser vision correction," *Journal of Refractive Surgery*, vol. 17, pp. S596–S601, 2001.
- [33] J. Colin, F. Mimouni, A. Robinet, H. Conrad, and P. Mader, "The surgical treatment of high myopia: comparison of epikeratoplasty, keratomileusis and minus power anterior chamber lenses," *Journal of Refractive Surgery*, vol. 6, no. 4, pp. 245–251, 1990.
- [34] C. Barraquer, C. Cavelier, and L. F. Mejia, "Incidence of retinal detachment following clear-lens extraction in myopic patients," *Archives of Ophthalmology*, vol. 112, no. 3, pp. 336–339, 1994.
- [35] F. Trindade and F. Pereira, "Exchange of a posterior chamber phakic intraocular lens in a highly myopic eye," *Journal of Cataract and Refractive Surgery*, vol. 26, no. 5, pp. 773–776, 2000.
- [36] O. Ibrahim and G. O. Waring III, "Successful exchange of dislocated phakic intraocular lens," *Journal of Refractive Surgery*, vol. 11, no. 4, pp. 282–283, 1995.
- [37] J. L. Güell, M. Vázquez, and O. Gris, "Adjustable refractive surgery: 6-mm Artisan lens plus laser in situ keratomileusis for the correction of high myopia," *Ophthalmology*, vol. 108, no. 5, pp. 945–952, 2001.
- [38] J. L. Arne, L. C. Lesueur, and H. H. Hulin, "Photorefractive keratectomy or laser in situ keratomileusis for residual refractive error after phakic intraocular lens implantation," *Journal of Cataract and Refractive Surgery*, vol. 29, no. 6, pp. 1167–1173, 2003.
- [39] C. A. Sánchez-Galeana, R. J. Smith, X. Rodríguez, M. Montes, and A. S. Chayet, "Laser in situ keratomileusis and photorefractive keratectomy for residual refractive error after phakic intraocular lens implantation," *Journal of Refractive Surgery*, vol. 17, no. 3, pp. 299–304, 2001.
- [40] M. Doors, T. T. J. M. Berendschot, C. A. B. Webers, and R. M. M. A. Nuijts, "Model to predict endothelial cell loss after iris-fixated phakic intraocular lens implantation," *Investigative Ophthalmology & Visual Science*, vol. 51, no. 2, pp. 811–815, 2010.
- [41] S. MacRae, J. T. Holladay, G. Hilmantel et al., "Special report: American academy of Ophthalmology task force recommendations for specular microscopy for phakic intraocular lenses," *Ophthalmology*, vol. 124, no. 1, pp. 141–142, 2017.
- [42] T. Kohnen and O. K. Klaproth, "Three-year stability of an angle-supported foldable hydrophobic acrylic phakic intraocular lens evaluated by Scheimpflug photography," *Journal of Cataract and Refractive Surgery*, vol. 36, no. 7, pp. 1120–1126, 2010.
- [43] A. Toso and S. Morselli, "Visual and aberrometric outcomes in eyes with an angle-supported phakic intraocular lens," *Journal of Cataract and Refractive Surgery*, vol. 38, no. 9, pp. 1590–1594, 2012.
- [44] J. L. Alió, F. de la Hoz, J. J. Pérez-Santonja, J. M. Ruiz-Moreno, and J. A. Quesada, "Phakic anterior chamber lenses for the correction of myopia," *Ophthalmology*, vol. 106, no. 3, pp. 458–466, 1999.
- [45] J. J. Pérez-Santonja, M. T. Iradier, L. Sanz-Iglesias, J. M. Serrano, and M. A. Zato, "Endothelial changes in phakic eyes with anterior chamber intraocular lenses to correct high myopia," *Journal of Cataract and Refractive Surgery*, vol. 22, no. 8, pp. 1017–1022, 1996.
- [46] J. J. Pérez-Santonja, J. L. Alió, I. Jiménez-Alfaro, and M. A. Zato, "Surgical correction of severe myopia with an angle-supported phakic intraocular lens," *Journal of Cataract and Refractive Surgery*, vol. 26, no. 9, pp. 1288–1302, 2000.
- [47] J. Ma Ruiz-Moreno and J. L. Alió, "Incidence of retinal disease following refractive surgery in 9,239 eyes," *Journal of Refractive Surgery*, vol. 19, no. 5, pp. 534–547, 2003.
- [48] J. M. Ruiz-Moreno, C. de la Vega, O. Ruiz-Moreno, and J. L. Alió, "Choroidal neovascularization in phakic eyes with

anterior chamber intraocular lenses to correct high myopia,” *Journal of Cataract and Refractive Surgery*, vol. 29, no. 2, pp. 270–274, 2003.

- [49] J. J. Pérez-Santonja, M. T. Iradier, J. M. B. del Castillo, J. M. Serrano, and M. A. Zato, “Chronic subclinical inflammation in phakic eyes with intraocular lenses to correct myopia,” *Journal of Cataract and Refractive Surgery*, vol. 22, no. 2, pp. 183–187, 1996.
- [50] M. Ostovic, C. Hofmann, O. K. Klapproth, and T. Kohnen, “Corneal decompensation and angle-closure glaucoma after upside-down implantation of an angle-supported anterior chamber phakic intraocular lens,” *Journal of Cataract and Refractive Surgery*, vol. 39, no. 5, pp. 806–809, 2013.