
A unique late complication of transcatheter atrial septal defect closure

 Gökhan Altunbaş*,  Mehmet Adnan Celkan**,
 Ertan Vuruşkan*,  Murat Sucu*

Departments of *Cardiology, and **Cardiovascular Surgery, Faculty of Medicine, Gaziantep University; Gaziantep-Turkey

Introduction

Secundum type atrial septal defects (ASD) are the most common type of interatrial shunts. Transcatheter closure is widely used in suitable cases. Although transcatheter closure has many advantages over surgical correction, it also has many early and late complications. Here we present a unique late complication of transcatheter closure of secundum type ASD.

Case Report

A 32-year-old female was admitted with atypical chest pain. Her medical history revealed that the patient had undergone transcatheter closure of secundum type ASD 28 months ago. Operation notes were reviewed which stated that the defect size was confirmed with balloon sizing and stop-flow method during cardiac catheterization. The defect was of the dimen-

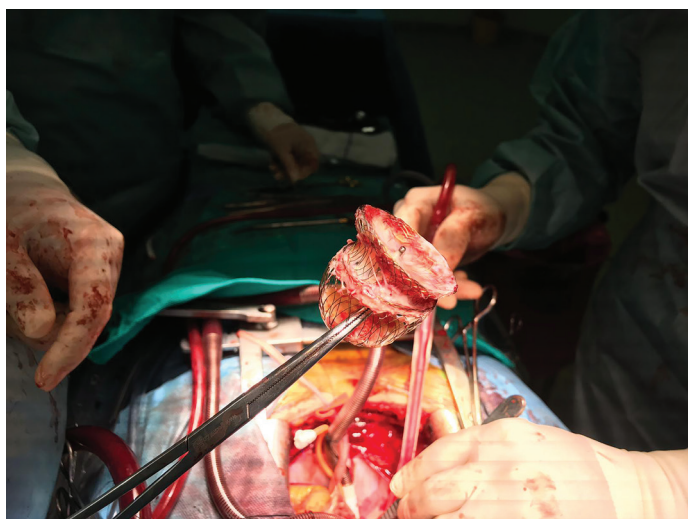


Figure 1. Surgical exploration showing device failure

sions 32×33 mm. Figulla Flex II (Occlutech) was placed under the transesophageal echocardiographic guidance. The procedural details were reviewed, but no extraordinary condition were found. The device was placed using the standard technique and alignment of the device was successful at first attempt. Control echocardiographic examination performed the day after the procedure was normal. Follow-up transthoracic echocardiography examinations one month and one year postprocedure were normal. Electrocardiography showed incomplete right bundle branch block and ST depressions on V1 through V4. ECG findings were similar to ECGs that were recorded prior to ASD closure. Transthoracic echocardiography showed normal left and right ventricular systolic functions and no significant valvular regurgitation. ASD closure device was in place; however, left atrial (LA) disk was opened, ballooned out, and occupied a large area within the left atrium (Video 1). Transesophageal echocardiography was performed that indicated the failure of the LA disk (Video 2). Due to the risk of systemic embolism, surgery was recommended. Because the patient had a family history of premature atherosclerosis, coronary angiography was performed. Coronary arteries were free of atherosclerosis. The device failure was also clearly visible on angiography (Video 3). During surgery, the device was removed and the defect was closed with a pericardial patch. The removed device showed near-complete epithelization and fibrin-rich thrombus, especially within the LA disk (Fig. 1). Post-operative recovery was uneventful, and the patient was discharged four days after the operation.

Discussion

Our case shows a unique late device failure associated with secundum ASD closure. Transcatheter intervention for ASDs has its own early and late complications. Early complications are

usually procedure related: device migration/embolization, pericardial effusion, air embolism, and conduction defects.

Late complications are much more diverse. The most frightening complication is cardiac erosion. After the first report by Amin et al. (1) in 2004 and similar cases reported thereafter, Amplatzer Septal Occluder instructions for use now has a caution regarding its use in patients with deficient aortic rim.

Figulla Flex II (Occlutech) is a relatively new device for the treatment of secundum type ASD closure. Since initial CE marking in 2007, there have been two generations with design modifications that lead to a softer device aiming at reducing the risk of device erosion. The major feature of Figulla Flex II is that the LA disk does not contain a microscrew, resulting in a softer disk. Kenny et al. (2) compared Amplatzer Septal Occluder with Figulla Flex II in pediatric patients with secundum ASD and revealed that Figulla Flex II was not inferior to Amplatzer Septal Occluder and also had greater efficacy and less complications compared with the former.

A wide range of late complications have been reported in the literature including very late aortic erosion (12 months to 13 years postprocedure), mitral valve perforation, and late device embolization (3-6).

Our case was a quite unusual late device failure. The device was in place and there were no signs of erosion; however, the LA disk was ballooned out. Figulla device lacks LA disk screw and reduced meshwork and is, therefore, more flexible. This feature adds flexibility to the device compared with the Amplatzer devices, but this may be responsible for reduced long-term durability. We need more data to confirm this hypothesis.

Conclusion

In conclusion, despite being safe and effective, transcatheter closure of ASD involves various reported and unreported late-term complications; thus, close follow-up and early evaluation of even atypical symptoms must be performed with caution.

Informed consent: Written informed consent was obtained from the patient for the publication of the case report.

Video 1. Transthoracic apical 4-chamber view demonstrating failure of the LA disk

Video 2. Transesophageal aortic short axis view showing normal localization of the device but an “opened” LA disc

Video 3. Right coronary angiogram showing normal right coronary artery and also a ballooned out LA disc

References

1. Amin Z, Hijazi ZM, Bass JL, Cheatham JP, Hellenbrand WE, Kleinman CS. Erosion of Amplatzer septal occlude device after closure of secundum atrial septal defects: review of registry of complications

- and recommendations to minimize future risk. *Catheter Cardiovasc Interv* 2004; 63: 496-502.
2. Kenny D, Eicken A, Dähnert I, Boudjemline Y, Sievert H, Schneider MB, et al. A randomized, controlled, multi-center trial of the efficacy and safety of the Occlutech Figulla Flex-II Occluder compared to the Amplatzer Septal Occluder for transcatheter closure of secundum atrial septal defects. *Catheter Cardiovasc Interv* 2019; 93: 316-21.
 3. Werner RS, Prêtre R, Maisano F, Wilhelm MJ. Fracture of a Transcatheter Atrial Septal Defect Occluder Device Causing Mitral Valve Perforation. *Ann Thorac Surg* 2019; 108: e29-e30.
 4. Kim JS, Yeom SY, Kim SH, Choi JW, Kim KH. Delayed left atrial perforation associated with erosion after device closure of an atrial septal defect. *Korean J Thorac Cardiovasc Surg* 2017; 50: 110-3.
 5. Kim HH, Yi GJ, Song SW. Late migration of Amplatzer septal occluder device to the descending thoracic aorta. *Korean J Thorac Cardiovasc Surg* 2017; 50: 47-9.
 6. Scognamiglio G, Barracano R, Colonna D, Materalaco A, Santoro G, Spadafora A, et al. A very late life-threatening complication after percutaneous closure of an atrial septal defect. *Can J Cardiol* 2017; 33: 293.e1-293.e2

Address for Correspondence: Dr. Gökhan Altunbaş,

Gaziantep Üniversitesi,
Tıp Fakültesi Hastanesi,
Kardiyoloji Anabilim Dalı,
27310, Şehitkamil,
Gaziantep-Türkiye

Phone: +90 342 360 60 60

E-mail: drgokhanaltun@gmail.com

©Copyright 2019 by Turkish Society of Cardiology - Available online
at www.anatoljcardiol.com

DOI:10.14744/AnatolJCardiol.2019.30388

