

Case Report

Therapeutic Potential of a Vasopressin V2 Receptor Antagonist for Calcium Channel Blocker-Associated Edema with Vasospastic Angina

Kojiro Toda, Masashi Fujino , Kota Murai , and Teruo Noguchi

Department of Cardiovascular Medicine, National Cerebral and Cardiovascular Centre, Suita, Japan

Correspondence should be addressed to Masashi Fujino; fujinom@ncvc.go.jp

Received 7 December 2021; Revised 21 April 2022; Accepted 22 June 2022; Published 8 July 2022

Academic Editor: Manabu Shirotani

Copyright © 2022 Kojiro Toda et al. This is an open access article distributed under the Creative Commons Attribution License, which permits unrestricted use, distribution, and reproduction in any medium, provided the original work is properly cited.

Calcium channel blocker- (CCB-) associated peripheral edema does not resolve without CCB discontinuation or dose reduction. However, renin-angiotensin system (RAS) inhibitors have been reported to be effective for CCB-associated edema. We report a case of vasospastic angina with refractory CCB-associated edema. A 78-year-old man had refractory edema induced by a CCB. It was successfully treated with tolvaptan, an active vasopressin V2 receptor antagonist. The aim of this case report is to understand the mechanism and treatment of CCB-associated peripheral edema and how tolvaptan affects peripheral edema.

1. Introduction

Calcium channel blockers (CCBs) are commonly used anti-hypertensive drugs. Peripheral edema is a common dose-dependent adverse effect. CCB-associated peripheral edema is thought to result from preferential arteriolar dilatation. Renin-angiotensin system (RAS) inhibitors can reduce CCB-associated peripheral edema by decreasing postcapillary resistance, which normalizes intracapillary pressure and reduces fluid extravasation. No other medications for CCB-associated peripheral edema have been reported. We describe successful treatment of CCB-associated peripheral edema using tolvaptan, an active vasopressin V2 receptor antagonist, in a patient with vasospastic angina who had been resistant to conventional diuretic and RAS inhibitor therapy.

2. Case Presentation

A 78-year-old man was admitted to our hospital with bilateral lower extremity swelling. He could not put on shoes of his usual size due to severe edema. His blood pressure was 126/62 mmHg, and pulse was 83 beats/min. Compared to his usual body weight, there was a 10 kg increase, up to

71 kg. Physical examination was notable for pitting edema on both lower extremities (Figures 1(a) and 1(b)). Furthermore, he had edema on his face and upper extremities. His jugular veins were not dilated.

His medical history included vasospastic angina, chronic kidney disease, and paroxysmal atrial fibrillation. Two months prior, he was diagnosed with vasospastic angina because of transient ST-segment elevation on an electrocardiogram during a heart attack, which was relieved by sublingual nitroglycerin (Figures 2(a) and 2(b)). Coronary angiography showed stenosis of the left anterior descending artery, which improved with nitroglycerin injection into the left coronary artery via a catheter (Figures 3(a) and 3(b)). He was prescribed nifedipine 40 mg daily because he had experienced angina with amlodipine 5 mg per day, but angina with ST-segment elevation recurred several times. Finally, he was discharged after being gradually titrated to nifedipine 80 mg per day, diltiazem 200 mg per day, and nitroglycerin patch 27 mg per 24 hours.

The differential diagnosis included CCB-associated peripheral edema, congestive heart failure, kidney failure, cirrhosis, hypothyroidism, and deep venous thrombosis. Laboratory tests revealed elevated creatinine (1.25 mg/dL)

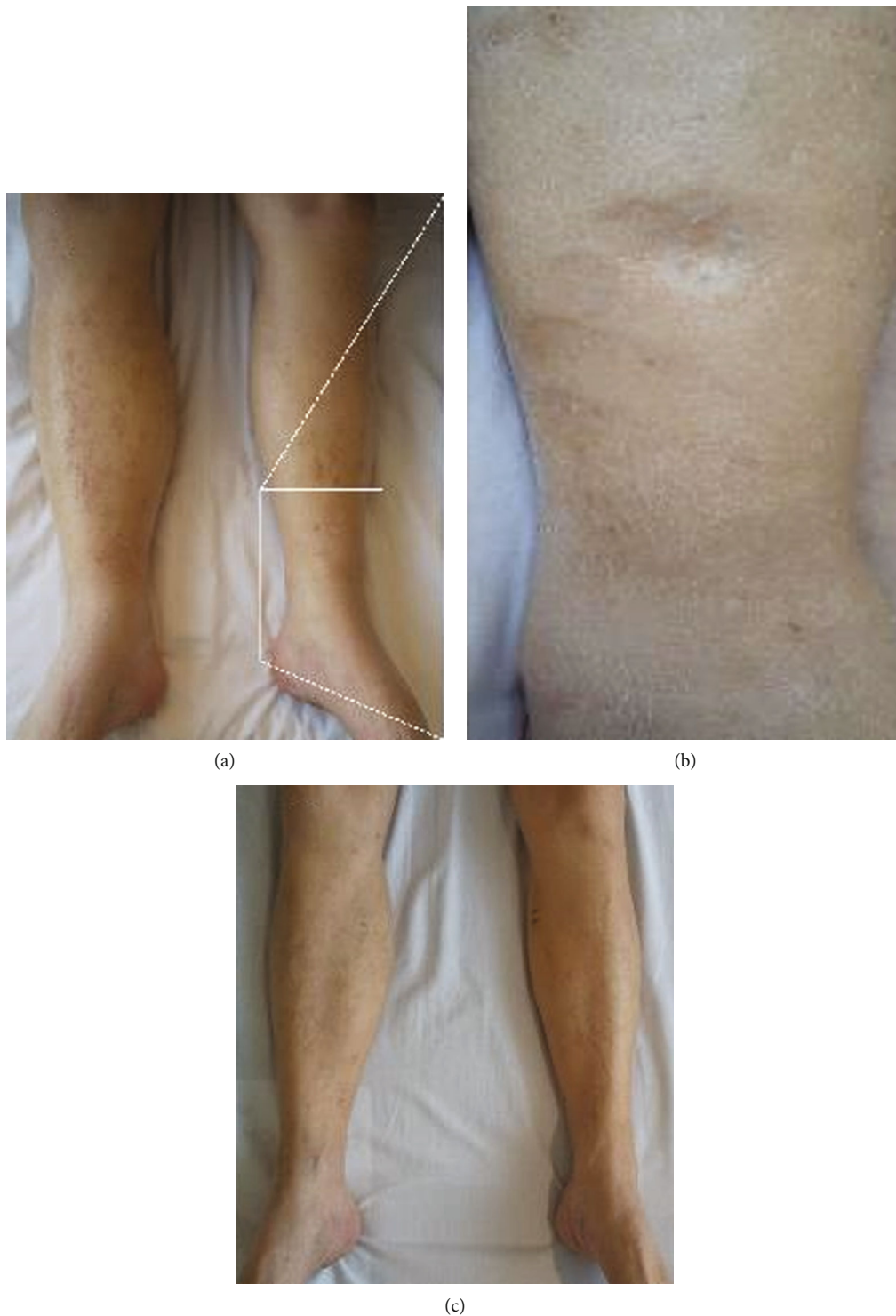

FIGURE 1: Photographs of the lower extremities. (a) Severe edema of the lower extremities. (b) Pitting edema in a magnified area of (a). (c) Tolvaptan reduced edema without side effects, leading to a body weight decrease of 12 kg.

and B-type natriuretic peptide (128 pg/mL; normal range < 18 pg/mL), but no significant changes from baseline. Albumin, liver function, and thyroid hormone levels were within normal limits. The electrocardiogram showed atrial fibrillation with no remarkable ST-segment changes. Chest radiog-

raphy revealed a cardiothoracic ratio of 48%, but both costophrenic angles were dull. Echocardiography revealed a normal left ventricular ejection fraction of 60%, left ventricular diastolic/systolic diameter of 51/33 mm, interventricular septum/posterior wall thickness of 10/9 mm, mild

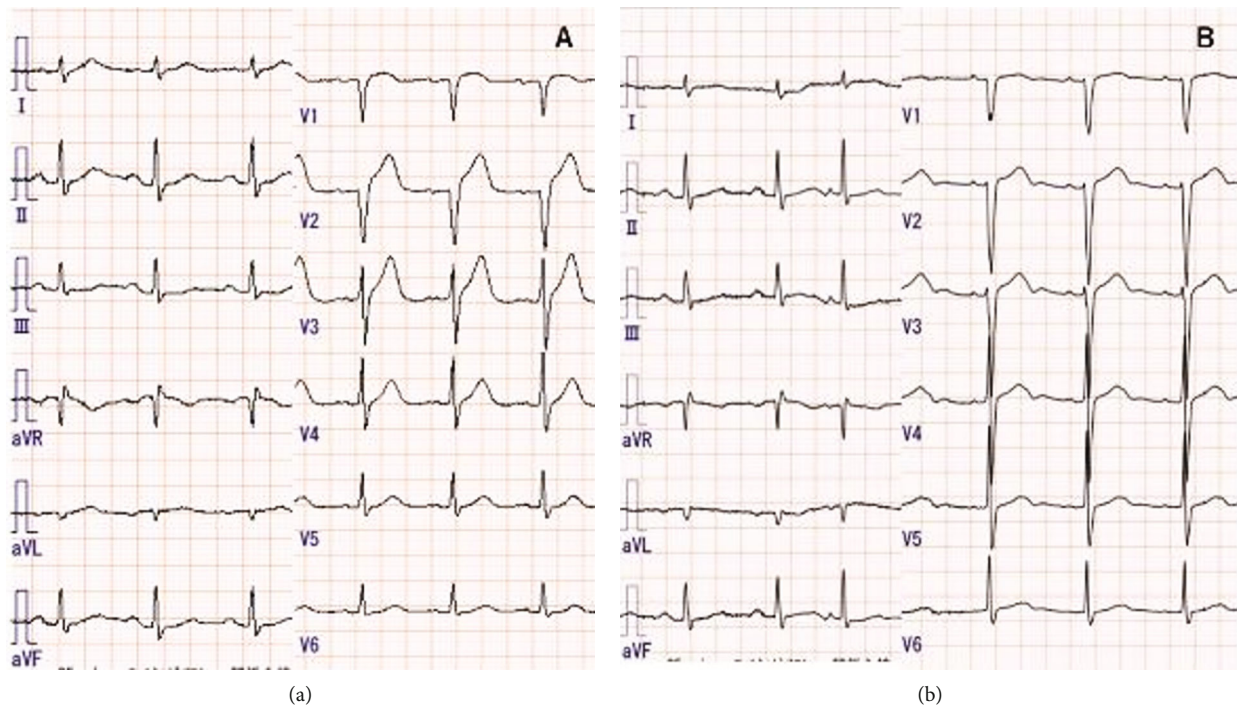


FIGURE 2: Electrocardiography findings. (a) ST-segment elevation in leads V2–4 during a heart attack. (b) After lingual nitroglycerin therapy, ST-segment elevations resolved.

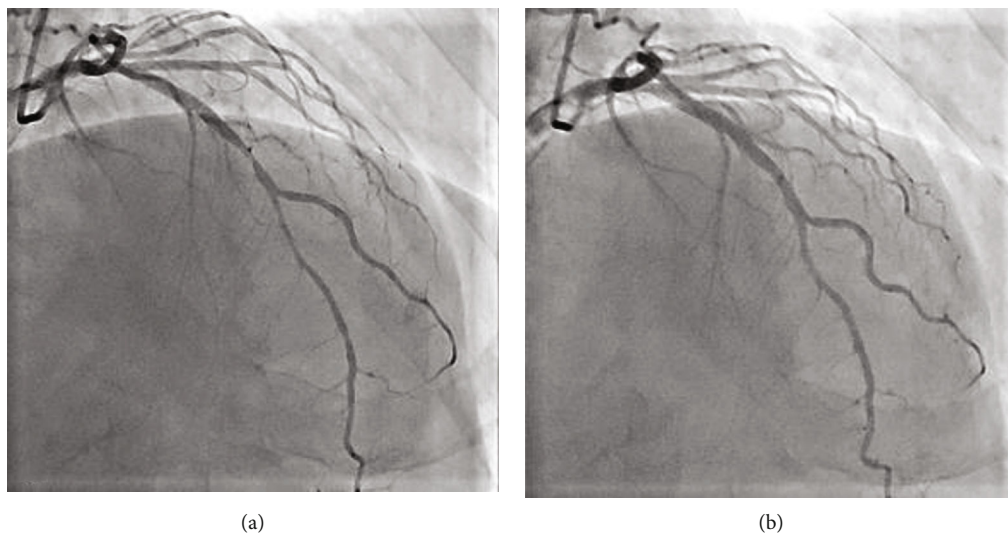


FIGURE 3: Coronary angiography findings. Left coronary angiography before (a) and after (b) nitroglycerin injection via a catheter, which dilated the stenosis in the middle of the left anterior descending coronary artery.

tricuspid regurgitation, and preserved function of the other cardiac valves. Based on these results, we made a diagnosis of CCB-associated peripheral edema.

As initial treatment, enalapril 2.5 mg per day and furosemide 20 mg per day were administered. The patient could not tolerate a higher dose of enalapril because of dizziness due to hypotension. Furosemide was discontinued because it decreased renal function. After adding spironolactone 25 mg per day, he lost 4 kg of body weight, but edema and

pleural effusion remained. Concerned about the recurrence of angina, the patient disagreed with CCB discontinuation or dose reduction. When we tried the active vasopressin V2 receptor antagonist tolvaptan at 7.5 mg per day, his urine output increased and his edema gradually resolved (Figure 1(c)). He lost 12 kg of body weight; his weight decreased to 59 kg. He had no adverse side effects while taking tolvaptan, such as hypernatremia. Renal function remained stable. After taking tolvaptan, laboratory tests revealed serum sodium of

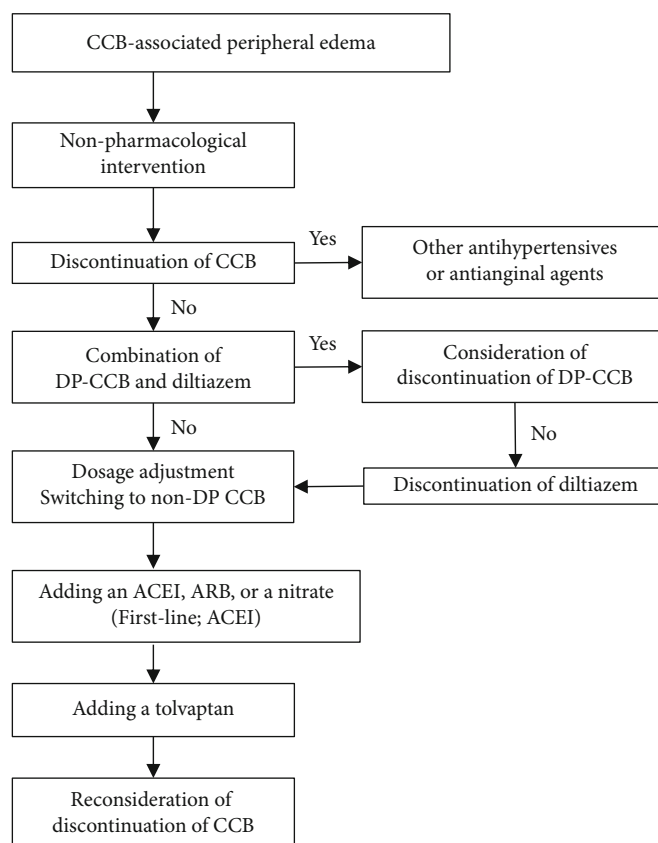


FIGURE 4: Treatment strategies for patients with CCB-associated peripheral edema. Abbreviations: ACE: angiotensin-converting enzyme; ARB: angiotensin II receptor blocker; CCB: calcium channel blocker; DP: dihydropyridine.

140 mEq/L, creatinine of 1.21 mg/dL, and B-type natriuretic peptide of 81.0 pg/mL. After discharge, the frequency of tolvaptan was decreased to every other day, with no recurrences of peripheral edema and no side effects from tolvaptan.

3. Discussion

This case indicated that tolvaptan has favorable effects on CCB-associated peripheral edema. Peripheral edema is a common adverse effect of CCBs. The incidence of peripheral edema is both dose- and duration-dependent. The incidence might exceed 80% with very high doses of dihydropyridine CCBs [1]. Furthermore, conventional racemic amlodipine causes edema more commonly than the S-isomer of amlodipine [2]. Treatment of CCB-associated peripheral edema consists of CCB dose reduction or discontinuation. A previous meta-analysis reported that combining angiotensin-converting enzyme (ACE) inhibitors or angiotensin II receptor blockers (ARBs) with CCBs reduces the incidence of CCB-associated edema by 38%. The CCB discontinuation rate due to peripheral edema with RAS inhibitors was 62% lower than with CCB monotherapy [3]. In addition, ACE inhibitors seem to be more effective than ARBs in reducing CCB-associated peripheral edema [3]. However, edema is sometimes refractory. Peripheral edema is considered to be the result of peripheral arteriolar dilatation, which increases the pressure gradient between arteriolar and venule capil-

laries and leads to extravasation of intravascular fluid. RAS inhibitors decrease postcapillary resistance, which normalizes intracapillary pressure and reduces fluid extravasation. This patient required high doses of nifedipine and diltiazem to control angina. The combination of these two drugs increases the blood concentration of nifedipine and potentiates its antihypertensive effects. Thus, he could not tolerate ACE inhibitors at a sufficiently high dose. Dihydropyridine-associated edema occasionally occurs despite the use of RAS inhibitors in addition to a diuretic. Exchanging nifedipine for extended-release diltiazem or felodipine led to patient tolerability and blood pressure control [4]. Although there has been a case report showing that the combination of dihydropyridine and diltiazem lowers blood pressure through their interaction [5], there have been no reports of refractory edema due to that interaction.

This patient was concerned about the recurrence of angina. Thus, he disagreed with CCB discontinuation or dose reduction. Furthermore, since he had mild chronic kidney disease, the edema was extremely severe and his response to conventional diuretics was poor. Refractory peripheral edema developed; low-dose RAS inhibitor therapy did not reduce the edema.

Tolvaptan has a diuretic effect with a mechanism that is different from that of conventional diuretics. Tolvaptan is an orally active vasopressin V2 receptor antagonist that blocks arginine vasopressin from binding to V2 receptors in the

distal nephron, which induces the excretion of electrolyte-free water without changing the total level of electrolyte excretion [6]. Although loop diuretics predominantly decrease extracellular water (ECW) rather than intracellular water (ICW), a previous study that involved bioimpedance analysis showed that tolvaptan ameliorates body fluid retention and induces equivalent reductions in ICW and ECW without worsening renal function [7]. Another study showed that tolvaptan restores body fluids by the efficient reduction of intracellular fluid than hemodialysis, by reducing the volume of intracellular fluid by a greater amount and maintaining more fluid in the extracellular space [8]. Tolvaptan induces diuresis of free water and an increase in serum sodium. Because the serum sodium concentration and the interstitial sodium concentration is identical, tolvaptan then induces an increase in the osmolarity of both the intravascular compartment and the interstitial compartment which would accelerate the oncotic forces leading to fluid movement from the intracellular compartment to the interstitial compartment. Tolvaptan helps maintain a lower intravascular volume and promote efficient diuresis, which ultimately decreases the fluid in the interstitium (i.e., edema). To treat CCB-associated peripheral edema, tolvaptan might work by helping fluid move from the intracellular compartment to the interstitial compartment. Furthermore, tolvaptan is reported to be effective for patients with chronic kidney disease [9]. In addition, dihydropyridine CCBs have a sodium diuretic effect; peripheral edema is not due to salt retention [10]. Therefore, classical diuretic treatment is not expected to be effective. However, tolvaptan was effective for this patient with CCB-associated peripheral edema. Figure 4 shows the strategy for patients with CCB-associated peripheral edema [11].

This case demonstrated that tolvaptan had a favorable effect on CCB-associated peripheral edema. It also suggested that an oral vasopressin V2 receptor antagonist could reduce CCB-associated peripheral edema in a patient with refractory edema even after CCB dose reduction or RAS inhibitor therapy.

Abbreviations

ACE: Angiotensin-converting enzyme
 ARB: Angiotensin II receptor blocker
 CCB: Calcium channel blocker
 ECW: Extracellular water
 ICW: Intracellular water
 RAS: Renin-angiotensin system.

Data Availability

The data used to support the findings of this study are included in the article.

Ethical Approval

The study was approved by the National Cerebral and Cardiovascular Center (case report 21-029).

Consent

The patient gave written consent for publication of this report.

Conflicts of Interest

The authors have no conflicts of interest to declare.

Acknowledgments

Masashi Fujino is supported by a Grant-in-Aid for Young Scientists from the Japan Society for the Promotion of Science (20K17138).

References

- [1] F. H. Messerli, "Vasodilatory edema: a common side effect of antihypertensive therapy," *Current Cardiology Reports*, vol. 4, no. 6, pp. 479–482, 2002.
- [2] J. Dalal, J. C. Mohan, S. S. Iyengar et al., "S-Amlodipine: an isomer with difference—time to shift from racemic amlodipine," *International Journal of Hypertension*, vol. 2018, Article ID 8681792, 14 pages, 2018.
- [3] H. Makani, S. Bangalore, J. Romero, O. Wever-Pinzon, and F. H. Messerli, "Effect of renin-angiotensin system blockade on calcium channel blocker-associated peripheral edema," *The American Journal of Medicine*, vol. 124, no. 2, pp. 128–135, 2011.
- [4] J. Handler, "Managing calcium channel blocker-related peripheral edema," *Journal of Clinical Hypertension*, vol. 6, no. 7, pp. 400–402, 2004.
- [5] J. C. Busse, R. E. de Velasco, and E. L. Pellegrini, "Combined use of nifedipine and diltiazem for the treatment of severe hypertension," *Southern Medical Journal*, vol. 84, no. 4, pp. 502–504, 1991.
- [6] R. W. Schrier, P. Gross, M. Gheorghiadu et al., "Tolvaptan, a selective oral vasopressin V2-receptor antagonist, for hyponatremia," *The New England Journal of Medicine*, vol. 355, no. 20, p. 2099, 2006.
- [7] T. Masuda, T. Murakami, Y. Igarashi et al., "Dual impact of tolvaptan on intracellular and extracellular water in chronic kidney disease patients with fluid retention," *Internal Medicine*, vol. 55, no. 19, p. 2759, 2016.
- [8] H. Kawabata, H. Iwatani, Y. Yamamichi, K. Shirahase, N. Nagai, and Y. Isaka, "Tolvaptan efficiently reduces intracellular fluid: working toward a potential treatment option for cellular edema," *Internal Medicine*, vol. 58, no. 5, pp. 639–642, 2019.
- [9] J. Sen, E. Chung, and D. McGill, "Tolvaptan for heart failure in chronic kidney disease patients: a systematic review and meta-analysis," *Heart, Lung & Circulation*, vol. 27, no. 8, pp. 928–939, 2018.
- [10] M. Epstein, G. D. M. Anna, and F. Hayley, "Natriuretic effects of calcium antagonists in humans: a review of experimental evidence and clinical data," *Cardiovascular Drug Reviews*, vol. 9, no. 4, pp. 398–412, 1991.
- [11] J. J. Saseen, "Pharmacologic treatment of hypertension," in *Cardiovascular Therapeutics (Fourth Edition) a Companion to Braunwald's Heart Disease*, pp. 474–489, Saunders, 2013.