



Egyptian Society of Cardiology  
The Egyptian Heart Journal

www.elsevier.com/locate/ehj  
www.sciencedirect.com



CASE REPORT

# Pattern of vascular remodeling of distal reference segment after recanalization of chronic total occlusion, long-term angiographic follow-up



Wassam El Din Hadad El Shafey \*

Cardiology Department, Faculty of Medicine, Menoufiya University, Shebin El Koom, Egypt

Received 3 June 2016; accepted 8 October 2016

Available online 18 December 2016

## KEYWORDS

Vascular remodeling;  
Distal reference segment;  
CTO;  
Recanalization

**Abstract** Chronic total occlusion (CTO) is probably caused by thrombus and lipid-rich cholesterol esters that are replaced over time by collagen and calcium deposition. Experimental models showed endothelial cell necrosis in response to vessel ligation, whereas more recent models suggest that the endothelium might retain viability guiding the subsequent development of CTO, including CTO neo-revascularization, which occurs within the lumen and in various layers of the vessel wall, by the release of paracrine substances. It is uncertain whether after CTO recanalization the recovery of anterograde reverses endothelial dysfunction, thus promoting vasodilation and positive remodeling.

© 2016 Production and hosting by Elsevier B.V. on behalf of Egyptian Society of Cardiology. This is an open access article under the CC BY-NC-ND license (<http://creativecommons.org/licenses/by-nc-nd/4.0/>).

## 1. Introduction

Vascular remodeling is a homeostatic response to changes in flow and circumferential stretch to maintain or restore normal shear stress and wall tension.<sup>1</sup>

In patients with a total occlusion of a coronary artery, reduced blood flow in distal reference segments might promote both negative vascular wall remodeling and plaque growth, as shown in animal models with carotid arteries.<sup>2</sup>

When recanalizing chronic total occlusion CTO segments, the distal reference segments in coronary angiograms usually appear very thin, inviting the question of whether flow restora-

tion of these tiny vessels will lead to any substantial improvement in cardiac function and justify the risk of this complex procedure at all, because CTO recanalization is more frequently associated with various complications during PCI.<sup>3</sup>

## 2. Case presentation

52 years old male patient known to be dyslipidemic but not diabetic, not hypertensive, and not smoker, presented with exertional angina symptoms and dyspnea grade II, resting ECG showed minor ST-T wave changes in pre-cordial chest leads, and Resting Echocardiography showed moderate hypokinesia of the territory of LAD, and borderline systolic function. Coronary angiography showed CTO of proximal LAD with retrograde filling of the distal LAD from RCA. CTO PCI to LAD was done in a separate session, Fielder XT-A supported by Fine-cross micro catheter was managed

\* Address: Faculty of Medicine, Menoufiya University, St. AL AMIN, ALHAYAA Pharmacy, Shebin El Koom, El Menoufiya, Egypt.

E-mail address: [dr\\_wesamhadad@yahoo.com](mailto:dr_wesamhadad@yahoo.com).

Peer review under responsibility of Egyptian Society of Cardiology.

<http://dx.doi.org/10.1016/j.ehj.2016.10.002>

1110-2608 © 2016 Production and hosting by Elsevier B.V. on behalf of Egyptian Society of Cardiology.

This is an open access article under the CC BY-NC-ND license (<http://creativecommons.org/licenses/by-nc-nd/4.0/>).

to cross the proximal cap of the CTO segment after several trials of sliding technique, small balloon trek was used to predilate the lesion; then up escalating balloons inflations were done before stenting the lesion, 2DES Xience primer was used to fix the lesion, and control angiography showed small distal reference segment of the whole LAD just distal to the stents. 6 months and 2.5 years follow-up coronary angiography was done and compared to the primary one showed gradual up escalating improvement of the distal reference vessel diameter (Fig. 1).

### 3. Discussion

Coronary CTO represents a unique in vivo pathophysiological model, in which alterations of segments distal to the occlusion are mainly determined by severe shear stress reduction. Indeed, in the distal coronary segments, the reduction in shear stress results in lesser endothelial release of vasodilators, in particular of nitric oxide<sup>4</sup> and greater release of vasoconstrictors, in particular endothelin-1, thus favoring vasoconstriction.<sup>5</sup> Moreover, the endothelium promotes the proliferation of “non-contractile” smooth muscle cells (SMCs) into the intima and structural alteration of extracellular matrix.

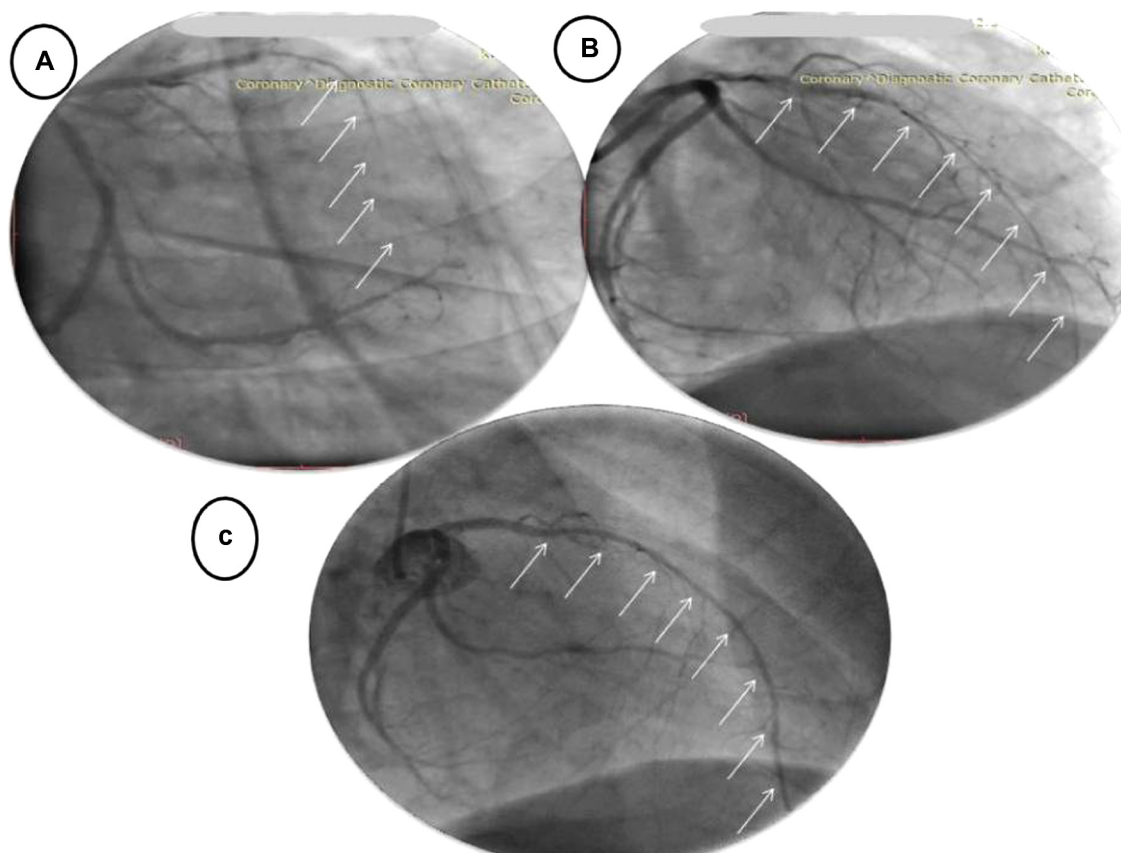
The improvement of distal vessel diameter size detected at follow-up after CTO recanalization can theoretically be explained by 3 different mechanisms: (1) impaired endothelium

dependent and/or -independent vasomotion immediately after CTO recanalization (hibernated vascular wall) and/or an intense vasoconstriction that improves at follow-up; (2) positive remodeling; or (3) a combination of both.<sup>6</sup>

In our case the immediate response of the distal reference segment to the opening of CTO segment was sluggish remodeling while at a follow-up period of 6 months and 2.5 years the response is much better.

In a study done by Park et al.<sup>7</sup> they found evidence of a flow-dependent vascular remodeling process in human coronary arteries after successful total occlusion recanalization that was associated with increases in lumen diameter, external elastic membrane (EEM) diameter, lumen area, EEM area, and LVEF. They also showed that more than two-thirds of the patients after recanalization showed lumen area increase in the distal reference segments along with improved LVEF 6 months after PCI. This vascular remodeling process with better coronary flow might contribute to improved myocardial function and clinical outcomes.<sup>7</sup>

It is interesting to note that administration of iodinated contrast media has complex vasomotor effects especially in CTO PCI procedures where large amounts of contrast are used.<sup>8</sup> Similarly, aggressive guide wires manipulation can determine an intense coronary vasoconstriction, which could be a reasonable factor of vessel diameter changes seen at late follow-up. Conversely, the distal stent diameter, and thus the coronary segment distal to it, yielded a significant effect on



**Figure 1** (A) Acute remodeling pattern of distal segment of CTO proximal lesion of LAD after stenting by DES. (B) 6 months control angiography of the same segment with little gain of diameter improvement. (C) Late remodeling pattern of the same segment after 2.5 years of angiographic follow-up.

diameter improvement. This finding might be related to the well-known association between shear stress and vessel diameter.<sup>9</sup> Accordingly, a larger vessel diameter in the distal stented segment might increase shear stress, thus facilitating the recovery of endothelial vasodilator function at follow-up.

#### 4. Conclusion

Recanalization of CTO lesions is sometimes followed immediately by poor positive remodeling of the distal reference segment which may be improved by time up to 2.5 years of follow-up that suggests recovery of a hibernation state of vascular wall.

#### Conflict of interest

There is no conflict of interest.

#### References

1. Langille BL. Arterial remodeling: relation to hemodynamics. *Can J Physiol Pharmacol* 1996;**74**:834–41.
2. Langille BL, O'Donnell F. Reductions in arterial diameter produced by chronic decreases in blood flow are endothelium-dependent. *Science* 1986;**231**:405–7.
3. Shimony A, Zahger D, Van Straten M, et al. Incidence, risk factors, management and outcomes of coronary artery perforation during percutaneous coronary intervention. *Am J Cardiol* 2009;**104**:1674–7.
4. Boo YC, Jo H. Flow-dependent regulation of endothelial nitric oxide synthase: role of protein kinases. *Am J Physiol Cell Physiol* 2003;**3**:499–508.
5. Morita T, Kurihara H, Maemura K, Yoshizumi M, Nagai R, Yazaki Y. Role of Ca<sup>2+</sup> and protein kinase C in shear stress-induced actin depolymerization and endothelin 1 gene expression. *Circ Res* 1994;**4**:630–6.
6. Galassi Alfredo R, Tomasello Salvatore D, Crea Filippo, Costanzo Maria Barbara, Campisano Maria Barbara, Marzá Francesco, et al. Transient impairment of vasomotion function after successful chronic total occlusion recanalization. *J Am Coll Cardiol* 2012;**59**(8):711–8.
7. Park JJ, Chae IH, Cho YS, Kim SW, Yang HM, Seo JB, et al. The recanalization of chronic total occlusion leads to lumen area increase in distal reference segments in selected patients. An intravascular ultrasound study. *JACC* 2012;**5**:827–36.
8. Limbruno U, De Caterina R. Vasomotor effects of iodinated contrast media: just side effects? *CurrVascPharmacol* 2003;**1**:321–8.
9. Dora KA. Coordination of vasomotor responses by the endothelium. *Circ J* 2010;**2**:226–32.