



CLINICAL PRACTICE ARTICLE

Case report: Percutaneous electrical neural field stimulation in two cases of sympathetically-mediated pain [version 1; referees: 1 approved, 2 approved with reservations]

Lynn Fraser¹, Anna Woodbury ^{2,3}

¹Department of Anesthesiology, University of North Carolina, Chapel Hill, NC, 27599, USA

²Department of Anesthesiology, Veterans Affairs Medical Center, Atlanta, GA, 30033, USA

³Pain Medicine, Anesthesiology, Emory University School of Medicine, Atlanta, Georgia, USA

v1 First published: 15 Jun 2017, 6:920 (doi: [10.12688/f1000research.11494.1](https://doi.org/10.12688/f1000research.11494.1))
 Latest published: 15 Jun 2017, 6:920 (doi: [10.12688/f1000research.11494.1](https://doi.org/10.12688/f1000research.11494.1))

Abstract

Background: Fibromyalgia and complex regional pain syndrome (CRPS) are both chronic pain syndromes with pathophysiologic mechanisms related to autonomic nervous system dysregulation and central sensitization. Both syndromes are considered difficult to treat with conventional pain therapies. **Case presentations:** Here we describe a female veteran with fibromyalgia and a male veteran with CRPS, both of whom failed multiple pharmacologic, physical and psychological therapies for pain, but responded to percutaneous electrical neural field stimulation (PENFS) targeted at the auricular branches of the cranial nerves. **Discussion:** While PENFS applied to the body has been previously described for treatment of localized pain, PENFS effects on cranial nerve branches of the ear is not well-known, particularly when used for regional and full-body pain syndromes such as those described here. PENFS of the ear is a minimally-invasive, non-pharmacologic therapy that could lead to improved quality of life and decreased reliance on medication. However, further research is needed to guide clinical application, particularly in complex pain patients.

Open Peer Review

Referee Status:

	Invited Referees		
	1	2	3
version 1 published 15 Jun 2017	 report	 report	 report

- 1 **Katie Schenning**, Oregon Health & Science University, USA
- Andrei Sdrulla**, Oregon Health & Science University, USA
- 2 **Albert Leung**, University of California, San Diego, USA
- 3 **Dalia Elmofty**, University of Chicago, USA

Discuss this article

Comments (0)

Corresponding author: Anna Woodbury (Anna.Woodbury@va.gov)

Competing interests: No competing interests were disclosed. The authors have no conflicts of interest and received no monetary funding from any sources to perform this research. Military Field Stimulators used for the two patients in these cases were provided free of charge from the manufacturer.

How to cite this article: Fraser L and Woodbury A. **Case report: Percutaneous electrical neural field stimulation in two cases of sympathetically-mediated pain [version 1; referees: 1 approved, 2 approved with reservations]** *F1000Research* 2017, 6:920 (doi: [10.12688/f1000research.11494.1](https://doi.org/10.12688/f1000research.11494.1))

Copyright: © 2017 Fraser L and Woodbury A. This is an open access article distributed under the terms of the [Creative Commons Attribution Licence](#), which permits unrestricted use, distribution, and reproduction in any medium, provided the original work is properly cited.

Grant information: The author(s) declared that no grants were involved in supporting this work.

First published: 15 Jun 2017, 6:920 (doi: [10.12688/f1000research.11494.1](https://doi.org/10.12688/f1000research.11494.1))

Introduction

Chronic pain syndromes encompass a poorly defined group of symptoms, including the chief perceptible state of ongoing pain. Patients often have comorbid findings, such as sleep disturbances, fatigue, headache, memory impairment, depression, anxiety, and bowel disturbance. All of these syndromes and associated symptoms can be precipitated by or worsened by stress and stressful life events, resulting in sympathetic nervous system activation¹⁻³. Therefore, modulation of the sympathetic nerve system, for example through vagal nerve stimulation or sympathetic nervous blockade, may help in reducing pain symptoms. Chronic pain syndromes significantly impact function and quality of life for these patients.

Fibromyalgia is among these syndromes that pose a challenge to pain specialists. Perhaps the difficulty in treating these patients lies in the lack of insight into the cause of fibromyalgia. Although the exact mechanism remains unknown, a central sympathetically-mediated mechanism is suspected⁴⁻⁶. This central sensitization and pain-induced brain changes can be visualized with neuroimaging⁷. Various psychological interventions for pain have therefore been employed to counter this sympathetic nervous system hyperactivity and central sensitization⁸.

Fibromyalgia, as a chronic, multi-system illness that can present with a variety of symptoms, ranging from decreased physical activity, sleep disturbances, fatigue, emotional disorders, memory loss, and the hallmark musculoskeletal pain, has generated hypotheses from initial theories of muscle inflammation towards a theory of central nervous system derangement⁹. In fact, using objective measures of activation of the sympathetic nervous system, Zamanuer *et al.* concluded that the degree of sympathetic activation was positively correlated with intensity of pain in fibromyalgia patients⁶. From this data, the investigators postulated that sympatholytic drugs may lessen pain intensity in fibromyalgia. It has even been proposed that fibromyalgia and related disease entities be referred to as “Central Sensitivity Syndrome.”¹⁰ Genetic, hormonal, psychosocial, and environmental factors may also play a role in this complex pathogenesis.

Similarly, complex regional pain syndrome (CRPS) is thought to have a mechanism of action involving dysfunction of the sympathetic nervous system, though its etiology is still poorly defined¹¹. It is believed there is a complex interplay between inflammatory mediators and the sympathetic nervous system, including sympathetic neurons releasing norepinephrine, which acts on adrenergic receptors, causing an increase in the amount of pro-inflammatory cytokines produced, ultimately leading to peripheral pain sensitization¹². Over time, maladaptive changes take place in the central nervous system, leading to central sensitization. While there is an increase in locally produced pro-inflammatory cytokines, interestingly, there is a lower level of norepinephrine measured in the affected limb¹³. The sympathetic overdrive seen in CRPS is believed to be due to “sympathetic sprouting” and up-regulation of alpha-adrenergic receptors, leading to increased sensitivity to sympathetic nervous system neurotransmitters¹³. Sympathetic blockade has been used in the treatment of CRPS, although it is unclear if this has long-term benefits¹⁴.

The impact of fibromyalgia, CRPS, and other chronic pain syndromes is widespread. The difficulty in treating these syndromes imparts a financial burden on the healthcare system, with an unsurprising increased utilization of healthcare services. Mean total healthcare costs are estimated to be about three times higher among fibromyalgia patients when compared to age- and sex-matched patients without fibromyalgia¹⁵.

We often find ourselves with limited tools in our armamentarium to effectively treat pain in this patient population. A multi-modal approach that includes non-pharmacologic therapy is desirable in addressing these elusive syndromes. Psychotherapy and physical therapy are considered fundamental in the treatment of fibromyalgia and CRPS, but are often insufficient as sole therapies to address the patient’s symptomatology. Among the minimally invasive non-pharmacologic therapies employed in chronic pain therapy are acupuncture¹⁶, transcutaneous electrical neural stimulation (TENS)¹⁷, percutaneous electrical neural stimulation (PENS)¹⁸, and more recently percutaneous electrical neural field stimulation (PENFS). Peri-auricular PENFS, which can be thought of as an evolution of auricular acupuncture and PENS to allow for stimulation of the entire ear, is thought to work by targeting the auricular branches of the cranial nerves. The auricular branches of the vagal nerve have previously been targeted for treatment of chronic pain syndromes¹⁹⁻²¹. Peri-auricular PENFS can plausibly exert a modulating effect on the central nervous system and on sympathetically-mediated pain through its access to auricular branches of the vagal nerve.

Here we present two cases of peri-auricular PENFS use in patients seen in our specialist pain medicine clinic at the Veterans Affairs Medical Center in Atlanta (GA, USA), with chronic pain syndromes refractory to multiple therapeutic interventions. The specific device used for PENFS in these patients was the Military Field Stimulator[®] (2016; Innovative Health Solutions INC.). Both patients gave written informed consent, in line with Declaration of Helsinki guidelines.

Case presentation

Case 1

A 56-year-old female veteran with a long-standing history of fibromyalgia and bipolar disorder, both diagnosed in 1990 following surgery for ovarian cancer, initially presented to the clinic on September 17, 2014 for interventional therapy for chronic low back pain of >10 years’ duration. She reported receiving epidural steroid injections and sacroiliac joint injections in the past, from which she had temporary relief of her low back pain. In addition to her chief complaint of low back pain, she reported diffuse pain, in areas including the head, neck, arms, hands, hips, and buttocks. She was under the care of a specialist for fibromyalgia and taking multiple daily prescription medications to control the pain, including meloxicam, amantadine, topiramate, hydrocodone/acetaminophen, duloxetine, cyclobenzaprine, tizanidine, and gabapentin. Her bipolar disorder was treated with lamotrigine. She was taking indomethacin and sumatriptan on an as needed basis for headache. In addition, she was taking herbs and supplements, including maca, garcinia, L-lysine, vitamin E, vitamin D, coral calcium, and niacin. She was evaluated by a rheumatologist

with inconclusive results regarding active inflammatory disease; she was previously on prednisone without reported benefit. Her daily function was significantly limited secondary to pain. She was unable to perform household chores and could not do physical activity for more than five minutes. If she over-exerted herself, she required one week without any physical activity. As a result, she reported poor quality of life. Her history was complicated by social issues, including strained relationships with her mother and daughter; she suffered a history of child abuse.

The patient agreed to try a series of acupuncture treatments. Pain scores were reported using the visual analog scale (VAS). After a series of acupuncture sessions between September 2014 and January 2015 (see Table 1), pain located in her head and neck was completely relieved, but the lower back pain persisted. She subsequently underwent a series of three peri-auricular PENFS applications (Table 1: January 21, 2015; January 28, 2015, February 3, 2015), per manufacturer recommendations (see Discussion), for initial treatment of complex pain. Follow-up visits after the first application revealed 100% relief of diffuse pain that she attributed to fibromyalgia. She stated that she no longer required hydrocodone/acetaminophen. However, she noted her sacroiliac joint pain remained. The second application of the peri-auricular PENFS yielded similar results. After the third and final application, she returned to the clinic stating she had on-going complete relief of pain attributed to fibromyalgia. Although she reported persistent sacroiliac joint pain, she noted she was able to go golfing again without issues, which was a significant functional improvement from initial presentation, and something she had not been able to do in almost a decade. The sacroiliac joint pain was successfully treated with radiofrequency ablation of the L5 dorsal ramus and S1 and S2 lateral branches, as she had previously undergone sacroiliac joint injections with significant, but unsustainable, relief from outside providers (series of 2 injections 1 month apart, multiple in 2014), and a repeated fluoroscopy-guided injection in our procedure suite on January 9, 2015 yielded similar results.

Follow-up (February 9, 2015; March 20, 2015; July 8, 2015) revealed three months' of >80% pain relief following peri-auricular PENFS treatment. The patient reported the return of diffuse pain coinciding with the death of her father, with whom she was close. She reported that her pain symptoms were exacerbated by anxiety and stress. At that time, a pain psychologist was included in her care. Acupuncture sessions were continued, and radiofrequency ablation of bilateral sacroiliac joints was continued. PENFS application was not repeated, (though recommendations from the manufacturer were that another one-time application could have resulted in alleviation of her symptoms again) as the patient felt that self-obtained cannabis oil had relieved the majority of her symptoms related to PTSD and pain. She felt that the device was bulky and difficult to wear, with adhesive that tended to entangle her hair, and preferred the combination of auricular acupuncture and cannabis oil for symptom management, despite decreased analgesic duration. The patient self-discontinued narcotic pain medications and pursued psychotherapy and auricular acupuncture, in combination with her own cannabis oil for the treatment of her symptoms.

Case 2

A 52-year-old visually-impaired male veteran, with a history of left toe non-union fracture, presented for evaluation of worsening left lower extremity pain on December 17, 2014. According to the patient, he was previously diagnosed with CRPS > 10 years prior. The pain was characterized as left foot and leg pain radiating to the left hip accompanied by intense burning. These symptoms were previously controlled with a combination of NSAIDs, acetaminophen, and meditation, but he attributed an acute worsening of pain due to inability to meditate and the added burdens of becoming a primary caregiver for his mother. He recently tried gabapentin without benefit, and with side effects of sedation and balance difficulties. He had acupuncture in the past for myofascial pain in the upper neck and trapezius with good relief, and presented to the clinic requesting a series of acupuncture treatments for his uncontrolled left lower extremity pain. His medical history also included traumatic

Table 1. Pain procedures performed in case 1. VAS, visual analog scale.

Date	Treatment Type	Starting VAS	Ending VAS	Duration of relief
24-Sep-14	Acupuncture	8	0	10 days
8-Oct-14	Acupuncture	7	0	>7 days
15-Oct-14	Acupuncture	5	2	4 days
19-Nov-14	Acupuncture	6	0	3 weeks
7-Jan-15	Acupuncture	8	4	2 days
9-Jan-15	Bilateral sacroiliac joint injections	8	0	10 days
21-Jan-15	PENFS	10	2	>7 days
28-Jan-15	PENFS	5	2	>5 days
3-Feb-15	PENFS	3	2	~ 3 months
8-Jul-15	Acupuncture	10	5	7 days
31-Jul-15	Bilateral sacroiliac joint radiofrequency Ablation	10	2	7 months

brain injury, chronic headaches, blindness, and “micro-seizures”, described as sensations of a shooting electrical and static electrical nature, all following a car accident with head impact.

Following his initial acupuncture treatment for CRPS on December 17, 2014, he had immediate pain relief on the day of therapy. On a follow-up visit, January 27, 2015, he endorsed >50% relief of the left lower extremity pain, as well as reduced intensity of the micro-seizures. At that time, the decision was made to begin a series of three placements of a peri-auricular PENFS device. Following the first application (January 27, 2015), he reported five days of >50% pain relief, accompanied by reduction of micro-seizures and an improvement in daily function. There was a noticeable increase in pain intensity when the battery life ended. He presented for a second application of the peri-auricular PENFS (February 3, 2015), after which he reported two days of 50% pain relief. After two days, he also reported return of micro-seizures that he noted seemed to correlate in intensity with left lower extremity pain. The final device application (February 9, 2015) resulted in two days of pain relief, at which time it came dislodged during visual evoked potential testing. He did state the needles stayed in place and seemed to give some relief despite not being connected to the stimulator.

After the final peri-auricular PENFS placement, the patient expressed a desire to continue with acupuncture sessions, which

seemed to provide longer-lasting relief with each subsequent session. He felt that the device did not stay in place as well as the auricular acupuncture needles, and that it only gave him relief while it was in place. He also believed that the battery ran out quicker than it should have, so did not wish to try it again, particularly given the expense of the device relative to auricular acupuncture. Pregabalin was added to his medications and use of a TENS unit was used as an adjunct in an effort to achieve satisfactory pain relief, though he did self-discontinue the pregabalin due to side effects (balance difficulties), maintaining that ibuprofen and acetaminophen were better-tolerated and helped to alleviate his symptoms.

Discussion

The Military Field Stimulator is an FDA-approved nerve stimulator that is meant to target both acute and chronic pain by creating a field stimulation around the auricle to peripheral auricular branches of the cranial nerves, including the vagus, trigeminal, facial, hypoglossal, and occipital nerves. Placement is minimally invasive and involves three stimulating electrodes and a grounding electrode. Electrodes are placed percutaneously and secured in place (Figure 1). A battery-operated generator is placed behind the ear that creates current that can be varied according to provider input. Stimulation is provided over a five-day period (120 hours) using a mild frequency between one and ten Hertz and amplitude of three Volts. A two-hour period of stimulation alternates with a two-hour period of rest for the treatment duration. Different

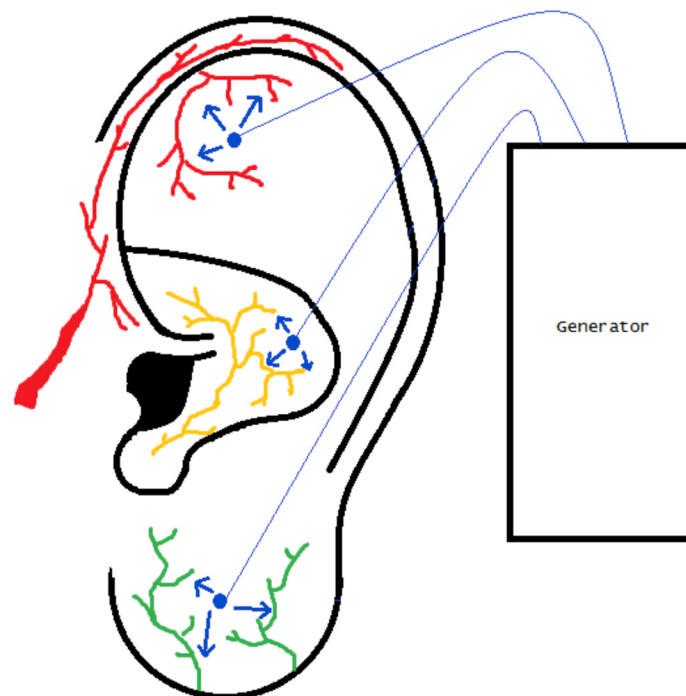


Figure 1. Example placement of percutaneous electrical neural field stimulation device. Electrode placement is provided in blue. Electrical field stimulation (blue arrows) of auricular branches of the trigeminal (red), vagus (yellow) and greater auricular (green) nerves is also depicted. Electrode placement can be varied to specifically target different points on the ear, though field stimulation provides broader coverage, regardless of placement.

treatment regimens exist, but for chronic pain, it is recommended that the patient have a series of three device placements, with each new trial occurring every seven days. The patient then has a rest period of seven days without the device. If pain increases during the rest period, the series of three device placements is repeated every seven days. Maximum analgesic benefit is achieved after six total placements.

The two patients described both obtained 50–100% relief of their chronic pain symptoms with utilization of peri-auricular PENFS. However, due to the discomfort associated with the device, both patients opted for alternate therapies (including auricular acupuncture) upon return of their symptoms. The patient in Case 1 achieved long-term (3 months' relief) following her PENFS series, until she experienced a life stressor. Manufacturer recommendations suggest that the device should be replaced for a five-day period should breakthrough pain occur after a period of analgesic effect. Had the patient chosen this option, it could have potentially restored her relief, but she had obtained cannabis oil from an unknown source, which she felt also gave her adequate relief of her pain. The patient in Case 2 could not complete the series, as the PENFS device became repeatedly dislodged. It is possible that he could have achieved longer-term relief, had he been able to complete the series in full. PENFS is distinct from manual acupuncture, electroacupuncture and TENS, although physiological effects may be related. In both Case 1 and Case 2, acupuncture had been performed prior to placement of peri-auricular PENFS, though results lasted for <30 days with each acupuncture treatment. It is possible that acupuncture may have primed these two patients for success with the PENFS device through neuro-modulatory mechanisms^{22,23}.

At the time of this case report, there has been only one study published using a PENFS device in patients with persistent, non-malignant, chronic pain²⁴. In this study of 20 chronic pain patients with non-specific pain diagnoses, a significant decrease (average 65% improvement) in the VAS score was found after four treatments with the device. Though many studies have employed PENS at various body parts for localized pain, these studies did not use PENFS (which employs broader field stimulation), did not specifically target the cranial nerve branches in the ear, and did not employ PENFS/PENS for complex, widespread pain syndromes, such as CRPS or fibromyalgia. It is possible that the mechanism of action in which PENFS is applied to the ear can create a broader effect that alleviates not just regional, but full-body pain, perhaps through its action on the vagus nerve.

Stimulation of afferent nerves, particularly the vagus nerve, could modulate the autonomic nervous system, such that sympathetic or centrally-mediated chronic pain syndromes could benefit from the device^{6,13,19–21}. Stimulation of the vagus nerve has been shown to inhibit spinal cord neurons below C3, but excite neurons between C1 and C3, suggesting that these areas may play a role in pain relief. Percutaneous stimulation of the auricular branches of the vagus nerve has been used to treat cervical dystonia²⁵. There is also evidence that stimulating the vagus nerve affects both the thalamus

and hypothalamus, areas where pain modulation has been shown to occur²⁶.

The cases discussed here involve patients in which a specific FDA-approved PENFS unit, the Military Field Stimulator, was placed in an attempt to control chronic pain secondary to fibromyalgia and CRPS. Both patients had persistent pain despite initial treatment modalities and agreed to a trial of PENFS. Both patients arguably had some element of sympathetically-mediated pain, which may explain why field stimulation of the auricular branches of the cranial nerves, including the vagus (i.e. increasing parasympathetic nervous system stimulation) may have modulated their pain. Of note, the patient in Case 1 did not experience relief of her sacroiliac joint pain using the PENFS device. This may indicate that, while PENFS could be helpful in sympathetically-mediated pain states with central sensitization, it may not be as effective in arthritic pain.

As noted previously, vagus nerve stimulation has been shown to have effects on the thalamus and hypothalamus²⁶. In addition to the favorable impact on reported pain levels, the impact of vagal nerve stimulation on these brain segments is believed to counteract chemically induced nausea and vomiting due to the connection of the thalamus and hypothalamus to the “vomiting center” of the brain. Transcutaneous vagal nerve stimulation has also been shown to improve gastric motility²⁷. While further studies are needed to validate these initial findings, there appears to be promising possibilities for the use of PENFS devices or similar means of vagal nerve stimulations as adjuncts for multiple perceptible states.

This report describes an abbreviated trial of the PENFS device in two patients with sympathetically-mediated chronic pain syndromes. Further directions include recruiting a larger sample size and prolonged series of treatments (6 placements). However, based on our experiences with the Military Field Stimulator device, patients showed poor tolerance to repeated placement of the device due to its poor wearability, and thus showed a preference for alternative treatments, such as auricular and body acupuncture, despite the short-term duration of these treatments. A more wearable and user-friendly PENFS device is likely needed for increased patient compliance. It may be interesting to do a comparative study with PENFS and electroacupuncture or auricular acupuncture. Neuroimaging could also be employed to explore the neural mechanisms of PENFS effects in central pain states. A cost-benefit analysis should also be performed, as the Military Field Stimulator requires multiple applications with an indeterminate duration of relief. However, the costs of pharmacologic therapy and pain-related disability is also high. Well-designed, randomized controlled trials evaluating long-term pain and functional improvements related to PENFS use are needed.

Auricular PENFS is a promising therapeutic modality that requires further investigation. Further delineation of appropriate applications for peri-auricular PENFS is necessary to determine in which pain syndromes it would be most useful. It may be a useful adjunct

in pain syndromes that have been otherwise difficult to control, but more studies are needed.

Consent

Written informed consent for publication of their clinical details was obtained from the patients.

Author contributions

Lynn Marie Fraser reviewed all notes and procedural details regarding the cases and wrote the majority of the clinical case report under the supervision of Dr. Woodbury.

Anna Woodbury saw and examined the patients, documented details in progress notes, and provided guidance to Dr. Fraser.

She also personally contributed to much of the discussion section regarding the mechanisms of PENFS action in these patients.

Competing interests

No competing interests were disclosed. The authors have no conflicts of interest and received no monetary funding from any sources to perform this research. Military Field Stimulators used for the two patients in these cases were provided free of charge from the manufacturer.

Grant information

The author(s) declared that no grants were involved in supporting this work.

Acknowledgements

We are grateful to the patients and caregivers for their participation.

References

- Lerman I, Davis BA, Bertram TM, *et al.*: **Posttraumatic stress disorder influences the nociceptive and intrathecal cytokine response to a painful stimulus in combat veterans.** *Psychoneuroendocrinology*. 2016; **73**: 99–108.
[PubMed Abstract](#) | [Publisher Full Text](#)
- Heidari J, Mierswa T, Kleinert J, *et al.*: **Parameters of low back pain chronicity among athletes: Associations with physical and mental stress.** *Phys Ther Sport*. 2016; **21**: 31–37.
[PubMed Abstract](#) | [Publisher Full Text](#)
- Burke NN, Finn DP, McGuire BE, *et al.*: **Psychological stress in early life as a predisposing factor for the development of chronic pain: Clinical and preclinical evidence and neurobiological mechanisms.** *J Neurosci Res*. 2016; **95**(6): 1257–1270.
[PubMed Abstract](#) | [Publisher Full Text](#)
- Kosek E, Altawil R, Kadetoff D, *et al.*: **Evidence of different mediators of central inflammation in dysfunctional and inflammatory pain—interleukin-8 in fibromyalgia and interleukin-1 β in rheumatoid arthritis.** *J Neuroimmunol*. 2015; **280**: 49–55.
[PubMed Abstract](#) | [Publisher Full Text](#) | [Free Full Text](#)
- Kang JH, Kim JK, Hong SH, *et al.*: **Heart Rate Variability for Quantification of Autonomic Dysfunction in Fibromyalgia.** *Ann Rehabil Med*. 2016; **40**(2): 301–309.
[PubMed Abstract](#) | [Publisher Full Text](#) | [Free Full Text](#)
- Zamunér AR, Barbic F, Dipaola F, *et al.*: **Relationship between sympathetic activity and pain intensity in fibromyalgia.** *Clin Exp Rheumatol*. 2015; **33**(1 Suppl 88): S53–57.
[PubMed Abstract](#)
- Cagnie B, Coppieeters I, Denecker S, *et al.*: **Central sensitization in fibromyalgia? A systematic review on structural and functional brain MRI.** *Semin Arthritis Rheum*. 2014; **44**(1): 68–75.
[PubMed Abstract](#) | [Publisher Full Text](#)
- Thieme K, Turk DC, Gracely RH, *et al.*: **Differential psychophysiological effects of operant and cognitive behavioural treatments in women with fibromyalgia.** *Eur J Pain*. 2016; **20**(9): 1478–89.
[PubMed Abstract](#) | [Publisher Full Text](#)
- Sluka KA, Clauw DJ: **Neurobiology of fibromyalgia and chronic widespread pain.** *Neuroscience*. 2016; **338**: 114–129.
[PubMed Abstract](#) | [Publisher Full Text](#) | [Free Full Text](#)
- Yunus MB: **Central sensitivity syndromes: a new paradigm and group nosology for fibromyalgia and overlapping conditions, and the related issue of disease versus illness.** *Semin Arthritis Rheum*. 2008; **37**(6): 339–352.
[PubMed Abstract](#) | [Publisher Full Text](#)
- Kuttikat A, Noreika V, Shenker N, *et al.*: **Neurocognitive and Neuroplastic Mechanisms of Novel Clinical Signs in CRPS.** *Front Hum Neurosci*. 2016; **10**: 16.
[PubMed Abstract](#) | [Publisher Full Text](#) | [Free Full Text](#)
- Li W, Shi X, Wang L, *et al.*: **Epidermal adrenergic signaling contributes to inflammation and pain sensitization in a rat model of complex regional pain syndrome.** *Pain*. 2013; **154**(8): 1224–1236.
[PubMed Abstract](#) | [Publisher Full Text](#) | [Free Full Text](#)
- Schlereth T, Drummond PD, Bircklein F: **Inflammation in CRPS: role of the sympathetic supply.** *Auton Neurosci*. 2014; **182**: 102–107.
[PubMed Abstract](#) | [Publisher Full Text](#)
- O'Connell NE, Wand BM, McAuley J, *et al.*: **Interventions for treating pain and disability in adults with complex regional pain syndrome.** *Cochrane Database Syst Rev*. 2013; (4): CD009416.
[PubMed Abstract](#) | [Publisher Full Text](#)
- Berger A, Dukes E, Martin S, *et al.*: **Characteristics and healthcare costs of patients with fibromyalgia syndrome.** *Int J Clin Pract*. 2007; **61**(9): 1498–1508.
[PubMed Abstract](#) | [Publisher Full Text](#) | [Free Full Text](#)
- Deare JC, Zheng Z, Xue CC, *et al.*: **Acupuncture for treating fibromyalgia.** *Cochrane Database Syst Rev*. 2013; (5): CD007070.
[PubMed Abstract](#) | [Publisher Full Text](#) | [Free Full Text](#)
- Gozani SN: **Fixed-site high-frequency transcutaneous electrical nerve stimulation for treatment of chronic low back and lower extremity pain.** *J Pain Res*. 2016; **9**: 469–479.
[PubMed Abstract](#) | [Publisher Full Text](#) | [Free Full Text](#)
- Rossi M, DeCarolis G, Liberatoscioli G, *et al.*: **A Novel Mini-invasive Approach to the Treatment of Neuropathic Pain: The PENS Study.** *Pain Physician*. 2016; **19**(1): E121–128.
[PubMed Abstract](#)
- Napadow V, Edwards RR, Cahalan CM, *et al.*: **Evoked pain analgesia in chronic pelvic pain patients using respiratory-gated auricular vagal afferent nerve stimulation.** *Pain Med*. 2012; **13**(6): 777–789.
[PubMed Abstract](#) | [Publisher Full Text](#) | [Free Full Text](#)
- Yuan H, Silberstein SD: **Vagus Nerve and Vagus Nerve Stimulation, a Comprehensive Review: Part I. Headache.** 2016; **56**(1): 71–78.
[PubMed Abstract](#) | [Publisher Full Text](#)
- Yuan H, Silberstein SD: **Vagus Nerve and Vagus Nerve Stimulation, a Comprehensive Review: Part III. Headache.** 2016; **56**(3): 479–490.
[PubMed Abstract](#) | [Publisher Full Text](#)
- Wang SM, Kain ZN, White PF: **Acupuncture analgesia: II. Clinical**

- considerations. *Anesth Analg*. 2008; **106**(2): 611–621, table of contents.
[PubMed Abstract](#) | [Publisher Full Text](#)
23. Hui KK, Marina O, Claunch JD, *et al.*: **Acupuncture mobilizes the brain's default mode and its anti-correlated network in healthy subjects.** *Brain Res*. 2009; **1287**: 84–103.
[PubMed Abstract](#) | [Publisher Full Text](#) | [Free Full Text](#)
24. Roberts A, Brown C: **Decrease in VAS Score Following Placement of a Percutaneous Peri-Auricular Peripheral Nerve Field Stimulator.** *Clinical Medicine and Diagnostics*. 2015; **5**(2): 17–21.
[Reference Source](#)
25. Kampusch S, Kaniusas E, Széles JC: **Modulation of Muscle Tone and Sympathovagal Balance in Cervical Dystonia Using Percutaneous Stimulation of the Auricular Vagus Nerve.** *Artif Organs*. 2015; **39**(10): E202–212.
[PubMed Abstract](#) | [Publisher Full Text](#)
26. Chakravarthy K, Chaudhry H, Williams K, *et al.*: **Review of the Uses of Vagal Nerve Stimulation in Chronic Pain Management.** *Curr Pain Headache Rep*. 2015; **19**(12): 54.
[PubMed Abstract](#) | [Publisher Full Text](#)
27. Frøkjær JB, Bergmann S, Brock C, *et al.*: **Modulation of vagal tone enhances gastroduodenal motility and reduces somatic pain sensitivity.** *Neurogastroenterol Motil*. 2016; **28**(4): 592–598.
[PubMed Abstract](#) | [Publisher Full Text](#)

Open Peer Review

Current Referee Status:   

Version 1

Referee Report 04 October 2017

doi:10.5256/f1000research.12413.r23904



Dalia Elmofty

Department of Anesthesia & Critical Care, University of Chicago, Chicago, IL, USA

Stimulation of the auricular branch of the vagal nerve for the treatment of chronic pain has been reported in the literature. Percutaneous electrical neural field stimulation has been approved by the FDA and is classified as a minimal-risk device for the treatment of chronic pain. The exact mechanism is unknown, yet it is believed that the external ear contains branches of cranial nerves that project to brainstem nuclei involved in pain processing. Dr. Fraser and Woodbury provide an interesting description on the use of PEFNS for two cases of sympathetically-mediated pain.

Editorial Comments

Introduction:

1. The authors gave a detailed description on the pathophysiology of fibromyalgia and CRPS. The authors should consider providing a brief description on the mechanism of action of auricular stimulation.

Case 1:

1. The authors should consider stating that PENFS did not provide relief for pain from sacroiliitis and no need to further discuss other management (RFA). Does the author have any data on objective improvement in pain after PENFS therapy for case 1 (fibromyalgia patient).

Case 2:

1. The authors should consider providing information regarding sympathetic-mediated symptoms and signs of CRPS for case 2 and if PENFS treatment reduced any of the sympathetic-mediated symptoms and signs.
2. The authors should consider providing a table for treatment modalities performed for case 2 and outcomes (as done for Case 1).

Discussion:

1. The authors should consider discussing any potential side-effects from PENFS (exp. vaso-vagal response).
2. The authors should consider providing a more detailed explanation of the mechanism of action. This is a fairly new device. There is evidence that it works on the NTS, RVM, hypothalamus, amygdale and spinal cord.

Is the background of the cases' history and progression described in sufficient detail?

Yes

Are enough details provided of any physical examination and diagnostic tests, treatment given and outcomes?

Partly

Is sufficient discussion included of the importance of the findings and their relevance to future understanding of disease processes, diagnosis or treatment?

Yes

Is the conclusion balanced and justified on the basis of the findings?

Yes

Competing Interests: No competing interests were disclosed.

I have read this submission. I believe that I have an appropriate level of expertise to confirm that it is of an acceptable scientific standard, however I have significant reservations, as outlined above.

Referee Report 06 September 2017

doi:10.5256/f1000research.12413.r23509



Albert Leung

Department of Anesthesiology, University of California, San Diego, La Jolla, CA, USA

This is a very interesting case series documenting the efficacy PENFS in treating two complex chronic pain conditions. While the clinical outcome and potential related mechanisms are well described, it will be interesting for the reader if the authors can discuss the duration of pain relief from the treatment, which can vary from days to months as noted in table 1.

Is the background of the cases' history and progression described in sufficient detail?

Yes

Are enough details provided of any physical examination and diagnostic tests, treatment given and outcomes?

Partly

Is sufficient discussion included of the importance of the findings and their relevance to future understanding of disease processes, diagnosis or treatment?

Yes

Is the conclusion balanced and justified on the basis of the findings?

Yes

Competing Interests: No competing interests were disclosed.

I have read this submission. I believe that I have an appropriate level of expertise to confirm that it is of an acceptable scientific standard, however I have significant reservations, as outlined above.

Referee Report 11 July 2017

doi:[10.5256/f1000research.12413.r24043](https://doi.org/10.5256/f1000research.12413.r24043)



Katie Schenning , Andrei Sdrulla

Department of Anesthesiology & Perioperative Medicine, Oregon Health & Science University, Portland, OR, USA

The case series describes the use of a Federal Drug Administration-approved electroacupuncture device, the Military Field Stimulator, which is a type of percutaneous electrical neural field stimulation (PENFS), for the treatment of patients with sympathetically mediated chronic pain syndromes. This is a novel approach to treat chronic pain, by stimulating auricular branches of cranial nerves and likely modulating and normalizing the autonomic systems in the brain. Overall, this is an interesting and well-written description of 2 patient cases.

Introduction

The introduction describes well the complexity of fibromyalgia and complex regional pain syndrome (CRPS), including the hypotheses these syndromes are sympathetically mediated entities. However, we believe the introduction would be greatly improved by decreasing some of the details regarding fibromyalgia and CRPS, and instead focusing more on PENFS. For example, paragraphs two and three are repetitive and could be condensed into a single paragraph. On the other hand, PENFS is new technology and unfamiliar to most readers. The authors describe it later, in the Discussion section, however, the article would flow better if PENFS was introduced earlier. For example, Figure 1 could be part of the introduction.

Case Presentation- Case 1

The first patient has fibromyalgia, as well as sacroiliac joint dysfunction and comorbid mood disorder. The patient in case one had a drastic, sustained improvement in her pain, as well as her functional status.

Case Presentation- Case 2

For the patient with CRPS (case two) there is no mention of abnormal sympathetic tone in the affected extremity: swelling, edema, skin color changes, and temperature changes. This is important, as normalization of such findings (i.e. temperature difference between affected and unaffected leg during PENFS application) would support the notion that PENFS works by decreasing sympathetic tone, possibly in a similar way as a sympathetic block would act.

Discussion

PENFS shows potential as a novel, non-pharmacological, low side-effect profile, treatment for patients with complex pain syndromes that are refractory to other therapies. The two cases responded well to this therapy, despite not using it as recommended by the manufacturer. Both patients had significant pain relief from acupuncture, before initiation of PENFS, and the authors mention that "... acupuncture might have primed these two patients for success with the PENFS device ...". The authors should also discuss the possibility that these patients responded to PENFS because they had good pain relief with acupuncture (selection bias). The authors should consider explaining the rationale for choosing these

patients for PENFS trials. Was it because these patients had previously responded well to acupuncture? It may be that certain patients and possibly certain subtypes of fibromyalgia and CRPS respond to acupuncture, whereas others do not. The authors should also comment more broadly on the use of acupuncture for chronic pain syndromes in the discussion.

Minor points:

- Remove **the** from “auricular branches of **the** cranial nerves” in abstract and discussion.
- “Zamanuer et al.” is misspelled.

Is the background of the cases’ history and progression described in sufficient detail?

Yes

Are enough details provided of any physical examination and diagnostic tests, treatment given and outcomes?

Yes

Is sufficient discussion included of the importance of the findings and their relevance to future understanding of disease processes, diagnosis or treatment?

Yes

Is the conclusion balanced and justified on the basis of the findings?

Yes

Competing Interests: No competing interests were disclosed.

We have read this submission. We believe that we have an appropriate level of expertise to confirm that it is of an acceptable scientific standard.
