

Research Paper

The Harrington plus reconstruction for pelvic and acetabular metastases

Mukai Chimutengwende-Gordon*, Ross Coomber, Fidel Peat, Nadim Tarazi, Daud Chou, Andrew Carrothers

Cambridge Orthopaedic Pelvic Unit (COPU), Addenbrookes Major Trauma Centre, Cambridge University Hospitals NHS Foundation Trust, United Kingdom

ARTICLE INFO

Article history:

Received 6 November 2021

Revised 24 January 2022

Accepted 24 January 2022

Available online 3 February 2022

Keywords:

Pelvic and acetabular metastases

Harrington procedure

Suprapectineal plate

ABSTRACT

Background: Surgical management of periacetabular bone metastases is challenging. The Harrington Plus reconstruction is a modification of the original Harrington rod technique. An intrapelvic suprapectineal plate is used, with the aim of reconstructing a disrupted anterior column and reducing the risk of failure in cases where there is extensive medial bone loss.

Methods: A retrospective review of the 13 patients who have undergone the Harrington Plus procedure to date was performed. Mobility status, EQ5D and Oxford Hip scores were assessed.

Results: There was a significant improvement in mobility status, EQ5D and Oxford Hip Scores at 6 months postoperatively ($p < 0.05$). Two patients returned to theatre for debridement of infection. There were no postoperative dislocations, cup medialisation or cases of loosening of the prosthesis. No patient required revision arthroplasty surgery.

Conclusion: The Harrington Plus procedure produces a reliable construct that allows patients with extensive periacetabular metastatic defects to fully weight-bear. Careful patient selection and multidisciplinary management is essential.

© 2022 The Author(s). Published by Elsevier GmbH. This is an open access article under the CC BY-NC-ND license (<http://creativecommons.org/licenses/by-nc-nd/4.0/>).

1. Introduction

Bone is the third most common site for metastases from all cancers after the lungs and liver [1]. Following the spine, the pelvis is the site most commonly affected by bone metastases [2]. Metastatic disease of the pelvis and acetabulum significantly decreases quality of life for patients [3]. The life expectancy of many patients with metastatic disease has improved considerably due to advances in oncological management. This is associated with an increased number of patients with advanced metastatic bone disease and patients at higher risk of sustaining pathological fractures. As a result, there is a greater need for surgical intervention to achieve bony mechanical stabilisation of the pelvic ring and inherently reliable hip joints; allowing pain control and the ability to mobilise.

Surgical management is indicated in cases with pain resistant to nonsurgical management, extensive acetabular lesions compromising the stability of the hip joint and ability to weight bear, pathological fractures, radioresistant tumours or cases where radiotherapy is not adequate for stability [4]. Surgical reconstruction is often challenging due to extensive bone destruction, the effects of previous radiotherapy, the vascularity of the metastases leading to a high risk of non-cell salvageable intraoperative blood loss and patient

immunocompromise [5]. Conventional total hip arthroplasty with or without a cup cage may be indicated in cases with acetabular metastases with sufficient bone stock available for stable fixation [6]. In metastatic disease, with the inherent abnormal bone and abnormal bone physiology, there is concern of any uncemented hip replacement strategy failing with poor osteointegration of the construct with the host. Without adequate bone stock within the ilium and ischium, fixation of the flanges of a cup cage is not possible. Harrington described a technique for reconstruction of pelvic bone metastases using threaded pins inserted in a retrograde fashion through the superior acetabulum and into the iliac wings. The pins are cemented together with an acetabular support ring and a total hip replacement is then implanted [7]. Several groups have described modifications of pin placement [8–14]. Tillman et al described the use of pins inserted antegrade from the iliac crest to pass anteriorly, posteriorly and medially to the acetabulum, providing a scaffold onto which the acetabular component of the total hip replacement can be cemented [9]. This construct may fail either due to rod breakage, medialisation or progressive bone loss due to disease progression. Houdek et al performed 78 Harrington procedures and 21 (27%) of patients underwent re-operations, including revision of the acetabular component in 13 (11%) [3]. The Harrington Plus procedure developed by the senior author (AC) is a modification of the technique described by Tillman et al. The technique includes the use of an intrapelvic suprapectineal plate, which acts as both a

* Corresponding author.

E-mail address: mukai.c-gordon@nhs.net (M. Chimutengwende-Gordon).

tension band of the anterior column and a buttress of the medial wall, with the aim of providing a more robust construct in cases with extensive medial bone loss and to overcome the risk of failure in the face of further metastatic bone loss [15].

This paper describes the clinical and functional outcomes of patients who have undergone the Harrington Plus procedure.

2. Methods and patients

A retrospective review of all patients who have undergone the Harrington Plus reconstruction was conducted. The technique was developed at our institution and to our knowledge has not been performed in other centres. Patients were identified from an institutional database of pelvic and acetabular surgical cases, which has ethical approval for research included. Informed patient consent was obtained for surgery, follow up and research. There were 13 patients who have undergone the procedure to date, between 2016 and 2020. Inclusion criteria were previously mobile patients who had pelvic metastases involving the acetabulum with pain that was not controlled by nonoperative management. Additionally, patients offered the procedure had insufficient periacetabular bone stock for stability to weight-bear or for reconstruction with conventional total hip arthroplasty. Patients were excluded if they were not medically fit for surgery or their life expectancy was estimated to be less than six months. Previous extensive abdominal or pelvic surgery was considered a relative contraindication to performing an anterior intrapelvic approach.

2.1. Preoperative evaluation

Preoperative radiological assessment was performed with plain anteroposterior radiographs of the pelvis, a lateral view of the affected hip, long leg views of the femur and a CT scan of the pelvis. An MRI scan of the pelvis and femur was performed to further determine the extent of the metastases and angiography considered for lesion vascularity surgical planning when needed. Acetabular lesions were classified using the Harrington classification [7]. Metastases at risk of bleeding were considered for pre-operative embolisation. Four units of red blood cells were cross-matched pre-operatively.

2.2. Surgical procedure

Patients were initially positioned supine on a radiolucent pelvic table. A urinary catheter was inserted. Intravenous antibiotics and tranexamic acid were administered. A flowtron was placed on the contralateral lower limb. Cell salvage was not used due to the theoretical risk of metastatic seeding. The first stage of the procedure consisted of insertion of a suprapectineal plate (Stryker Ltd) via the anterior intrapelvic (modified Stoppa) approach. The design of the plate allows the quadrilateral surface/medial wall of the acetabulum to be buttressed with fixation into the anterior and posterior columns via screws into the superior pubic rami and sciatic buttress respectively.

Patients are positioned in the lateral decubitus position and re-prepped and draped for the second stage of the procedure. The posterior approach to the hip is used and the acetabulum is fully exposed and assessed. The tumour is debulked prior to reaming the acetabulum. A limited lateral window is performed for insertion of the Harrington rods. 4 mm fully-threaded Steinmann pins are inserted antegrade into the iliac crest; positioned anterior, posterior and medial to the floor of the acetabulum as described by Tillman et al [9]. The pins are initially inserted so that they are visible in the floor of the acetabulum to allow a reference for adjusting their position [9].

The acetabular component of the total hip replacement is then cemented into the acetabulum. With the suprapectineal plate (Stryker Ltd) medial wall buttress, mesh may be used to reconstruct the acetabular floor prior to implantation of the prosthesis. We use a dual mobility cup (Avantage, Biomet, UK) and a cemented femoral component (CPT, Zimmer, UK or MP Link, Link, UK). If there are femoral metastases, a long stemmed prosthesis is used to bypass this by at least two cortical diameters.

Postoperatively, patients were mobilised fully weight-bearing as tolerated. Patients were followed up in the outpatient clinic at 3 months, 6 months and 1 year postoperatively.

2.3. Outcomes

Outcomes reviewed were pre- and postoperative mobility status, intraoperative and postoperative complications, patient survival, quality of life and functional outcome. The mobility status was divided into 7 categories: 0 = bedridden, 1 = wheelchair bound, 2 = frame with assistance, 3 = use of a frame independently, 4 = use of 2 sticks, 5 = use of 1 stick, 6 = independent, without walking aids. The EQ5D and Oxford Hip Scores were collected prospectively to assess quality of life and functional outcomes.

2.4. Statistical analysis

This was performed using SPSS version 21.0 software (IBM, Armonk, New York). The Kolmogorov Smirnov test indicated that the data did not fit the assumptions for parametric testing ($p < 0.05$). Therefore, nonparametric tests were performed. Kruskal Wallis and Mann-Whitney U tests were used to determine differences between pre- and postoperative mobility, quality of life and functional status. A p value of <0.05 was considered to be statistically significant result. The Spearman's rho analysis was used to assess correlation between preoperative factors and complications.

3. Results

3.1. Patient characteristics

There were 8 male and 5 female patients, with a median age of 69 years (range 56 to 84 years). The median body mass index (BMI) was 26.7 (range 20.4 to 37.4). The primary tumour was known in all cases. Prostate carcinoma was the most common diagnosis (6 cases, 46.1%). Breast cancer was the primary tumour in 2 cases, myeloma in 2 cases, renal cell carcinoma in 2 cases and adrenal cortical carcinoma in 1 case. There was one grade II lesion, 6 grade III lesions and 6 grade IV lesions. Six patients had metastases within their ipsilateral proximal femur and 1 patient had a presenting pathological fractured neck of femur in addition. Seven patients had a pathological acetabular fracture (Fig. 1). One patient with adrenal cortical carcinoma underwent preoperative embolisation due to mineralocorticoid excess with uncontrolled hypertension (Fig. 2). No other patient underwent preoperative embolisation. All cases had undergone prior oncological treatment in the form of chemotherapy, radiotherapy, immunotherapy or hormonal therapy. Nine patients had preoperative radiotherapy (69.2%). This is summarised in Table 1.

3.2. Surgical outcomes

The median operative duration was 326 min (range 243 to 486). This operative duration included the time for re-positioning and re-draping in between the two surgical stages. The median number of units of red blood cells (RBCs) transfused was 2 units (583 mL)

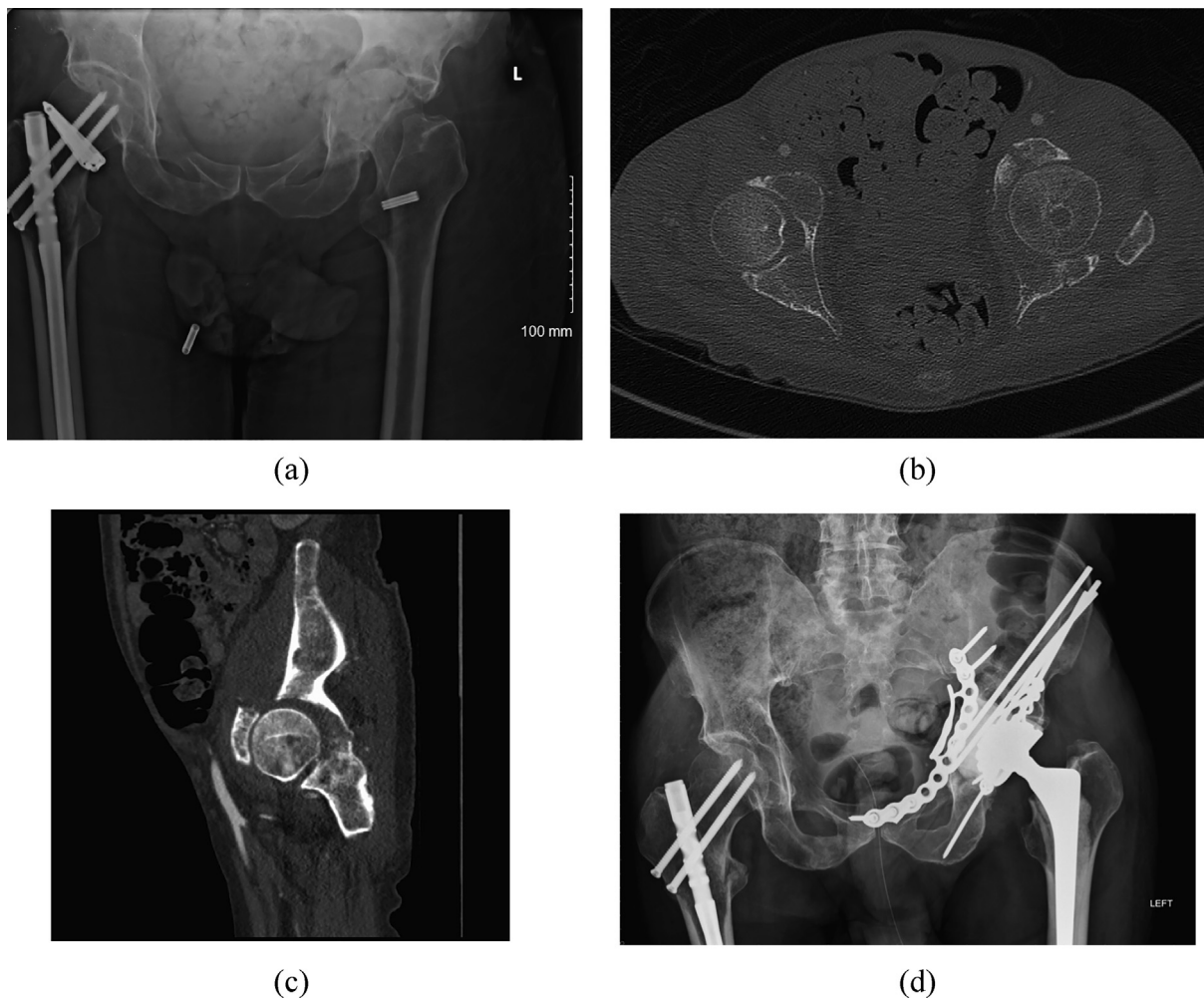


Fig. 1. (a to c) Preoperative radiographs and CT scan images of a 58 year old with prostate cancer and a pathological acetabular fracture (d) Postoperative radiographs following Harrington Plus Reconstruction.

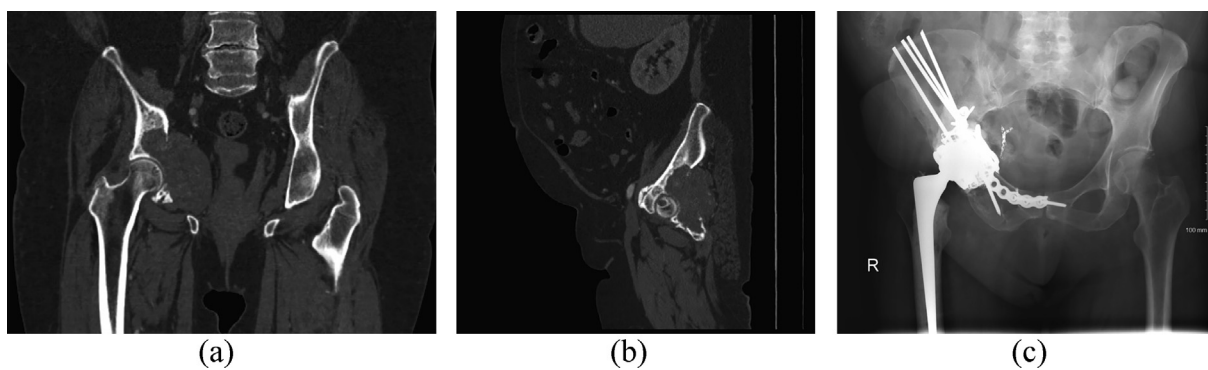


Fig. 2. (a and b) Preoperative CT scan of a 77 year old female with metastatic adrenal cortical carcinoma (c) Postoperative radiograph following Harrington Plus Reconstruction.

(range 0–14 units, 0–4087 mL). In two cases fresh frozen plasma and platelets were transfused in addition to RBCs (3 units of FFP and 1 unit of platelets in one patient and 8 units of FFP and 1 unit of platelets in the second patient). Two cases were complicated by infection and required a return to theatre. In both cases, the patients returned to theatre twice for irrigation and debridement of the anterior intrapelvic approach wound in the early postoperative period. Five patients developed postoperative acute renal

impairment, which resolved in all cases. One patient developed a pulmonary embolus five months postoperatively. There were no postoperative dislocations and no cases of loosening or medialisation of the prosthesis. None of the patients in our series have required revision surgery. One patient went into hypovolaemic shock intraoperatively and recovered following administration of intravenous adrenaline and blood transfusion. There were no intraoperative deaths.

Table 1
Patient characteristics.

	No. of patients (%)
Age	
55–64	5 (38.5)
65–74	4 (30.8)
75–85	4 (30.8)
BMI	
20–24	5 (38.5)
25–29	6 (46.1)
30–34	1 (7.7)
>35	1 (7.7)
Primary tumour	
Prostate	6 (46.1)
Breast	2 (15.4)
Renal cell carcinoma	2 (15.4)
Myeloma	2 (15.4)
Adrenal cell carcinoma	1 (7.7)
Harrington grade	
I	0 (0)
II	1 (7.7)
III	6 (46.1)
IV	6 (46.1)
Pathological fracture	
Acetabular	7 (53.8)
Femoral neck	1 (7.7)
Oncological treatment	
Chemotherapy	8 (61.5)
Radiotherapy	9 (69.2)
Immunotherapy	1 (7.7)
Hormonal Therapy	6 (46.1)

The median length of postoperative hospital stay was 10 days (range 4 to 41 days). The patient with adrenal cortical carcinoma had a prolonged hospital stay of 41 days under the Endocrinologists for management of mineralocorticoid excess and developed chest and urinary infections and small bowel enteritis. Six of the 13 patients have subsequently died due to disease progression. The median survival of the patients who died was 7.5 months (range 4.6 to 17.3 months). EQ5D and Oxford Hip Scores were not collected for the six patients who died. No other patients were lost to follow-up.

3.3. Mobility

Patients began to mobilise fully weight-bearing at a median of 2.5 days postoperatively (range 1 to 20 days). The patient with adrenal cortical carcinoma who had a complicated medical postoperative course as discussed above did not mobilise until 20 days postoperatively. The patient who became *peri-arrest* intraoperatively, mobilised at 8 days postoperatively. All other patients mobilised fully weight-bearing within 6 days. Six patients mobilised fully weight-bearing within two days postoperatively.

There was a significant improvement in mobility status at 3 months postoperatively, compared to preoperatively ($p = 0.003$). This improvement was maintained at 6 months in surviving patients ($p = 0.002$). At the final follow-up (range 3 to 36 months), the metastatic disease had progressed and resulted in a deterioration in mobility in two cases; however, the improvement compared to pre-operatively was maintained ($p = 0.009$) (Fig. 3).

3.4. Quality of life and functional outcomes

There was a significant improvement in EQ5D at 6 months postoperatively compared to preoperatively ($p = 0.006$) (Fig. 4). Simi-

larly, the Oxford Hip Score was improved at 6 months postoperatively ($p = 0.021$) (Fig. 5).

3.5. Correlation

There was no relationship between patient BMI, age, gender or the type of oncological treatment and clinical outcomes. Preoperative mobility status, EQ5D and Oxford Hip Score did not correlate with postoperative scores ($p > 0.05$). Increased Harrington grade was associated with an increased likelihood of the presence of a pathological acetabular fracture ($p = 0.04$, correlation coefficient 0.574). Increased Harrington grade and the presence of a pathological acetabular fracture both correlated with an increased length of surgery ($p = 0.028$, correlation coefficient 0.605, $p = 0.008$, correlation coefficient 0.701 respectively). Furthermore, there was a significant positive correlation between the Harrington grade, the presence of an acetabular fracture, the length of surgery and the quantity of blood transfused ($p = 0.001$, correlation coefficient 0.791, $p = 0.037$, correlation coefficient 0.582, $p = 0.025$, correlation coefficient 0.615 respectively).

4. Discussion

The key finding from this series is that the Harrington Plus reconstruction is an effective method for surgical management of advancing periacetabular metastases. This procedure resulted in improvements in mobility, quality of life and function. In all cases, a stable construct was achieved that enabled patients to mobilise fully weight-bearing in the early postoperative period, with no cases of medialisation or construct failure. There were no cases of rod fracture or reconstruction failure that has previously been described in up to 11% of cases with the original Harrington procedure or other modifications that do not include the use of a suprapectineal plate [3,7,9,12,16]. Although a key aim of the Harrington Plus procedure is to provide medial support, ischial deficiency is addressed in an indirect manner by locking the posterior column into the anterior column by the plating system, with the Harrington rods and the cementoma, which is often used initially when required before the reconstruction with the total hip replacement.

The Harrington Plus reconstruction is technically challenging with a high risk of anaesthetic and surgical complications. Patient selection is a key factor in determining the clinical outcomes following this procedure. It is less suitable for very frail patients who may not be medically fit for the procedure. Patients should have an anticipated life expectancy of at least six months in order to benefit following the recovery period. Previous extensive abdominal or pelvic surgery may compromise the ability to perform the anterior intrapelvic approach safely due to the presence of dense scar tissue and the high risk to neurovascular and genitourinary structures. The original Harrington procedure may be indicated in cases where an anterior intrapelvic approach is considered to be unsafe.

Importantly, this series has demonstrated that the Harrington Plus procedure may be used successfully in cases with advanced metastatic disease. The majority of patients were Harrington grade III or IV, with 46.1% of cases being Harrington grade IV. Charles et al reported outcomes following a modified Harrington procedure and included a similar proportion of cases with Harrington grade IV metastatic disease (44%) [11]. Other studies on a range of modified Harrington procedures have included patients with less advanced disease than in our series, i.e. predominantly Harrington grade II and III lesions [9,17–19]. Charles et al reported that 71% of postoperative complications occurred in the patients with Harrington grade IV lesions [11]. The finding from our series that an increased Harrington grade and the presence of a pathological acetabular

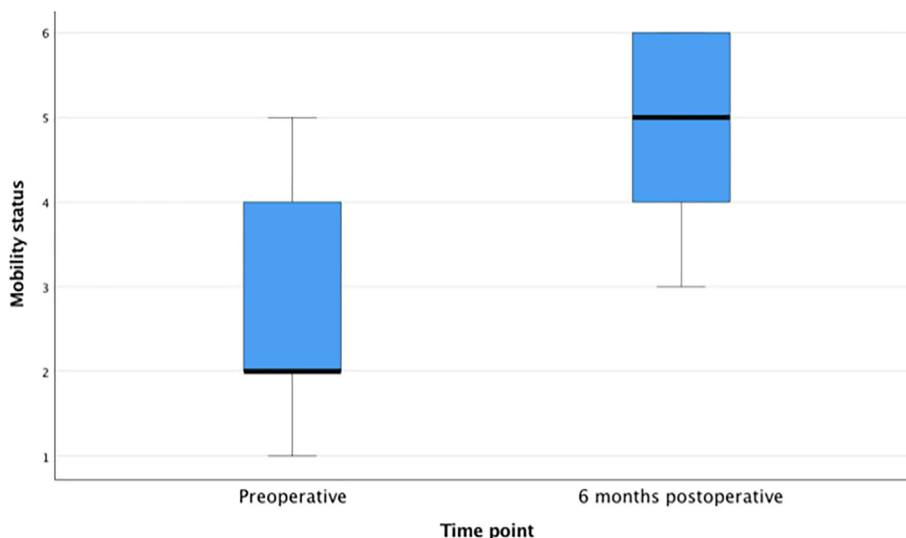


Fig. 3. Box plot showing preoperative and postoperative mobility status. 0 = bedridden, 1 = wheelchair bound, 2 = frame with assistance, 3 = use of a frame independently. 4 = use of 2 sticks, 5 = use of 1 stick, 6 = independent, without walking aids.

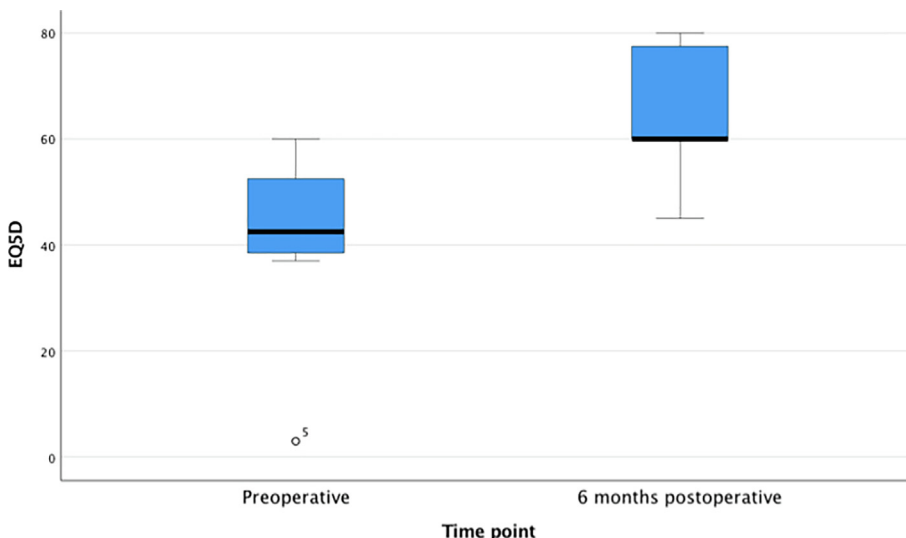


Fig. 4. Box plot showing preoperative and postoperative EQ5D scores.

fracture are associated with increased blood loss and length of postoperative hospital stay is in keeping with this. Despite the increased risks, it is postulated that patients with more advanced disease are the group of patients most likely to require the additional stability provided by the Harrington Plus procedure. Reassuringly, the complication rate from our series is not greater than reported by other groups who have included patients with less advanced disease [9,11,12,14,17–20]. Although all patients in this series survived more than three months, other series with patients with less advanced metastatic disease survived longer as expected. It is possible that this contributed to a lower rate of long term complications in our series. The significant blood loss and the transient acute renal failure that was observed in some patients is likely to be due to the prolonged surgery with a dual approach. However, despite the longer operative time due to an additional surgical stage, intraoperative blood transfusion requirements were overall not greater compared to these other series. One patient in our series required a massive blood transfusion. This patient had an old pathological acetabular fracture and a significant amount of the

bleeding occurred during the second stage of the procedure from extensive femoral metastases. Factors such as the vascularity of the tumour, the presence of femoral metastases and the degree of scar tissue are expected to affect blood loss. In this series, only one patient underwent preoperative embolisation. Preoperative embolisation for both acetabular and femoral metastases is an intervention that could be considered to reduce blood loss for future cases [16,21]; although the evidence for the effectiveness of embolization for pelvic metastases, particularly with primary tumour types other than renal cell carcinoma is limited and not conclusive [22–25]. Embolisation was not performed for the two patients with renal cell carcinoma in this series. Both cases had been referred to the interventional radiologists pre-operatively; however, the interventional radiologists did consider this to be appropriate for either case. This is because the acetabular circulation is often not easily embolized without significant morbidity. Additionally, earlier referral is likely to be beneficial, which requires increasing awareness of Oncologists and Orthopaedic Surgeons about this surgical option.

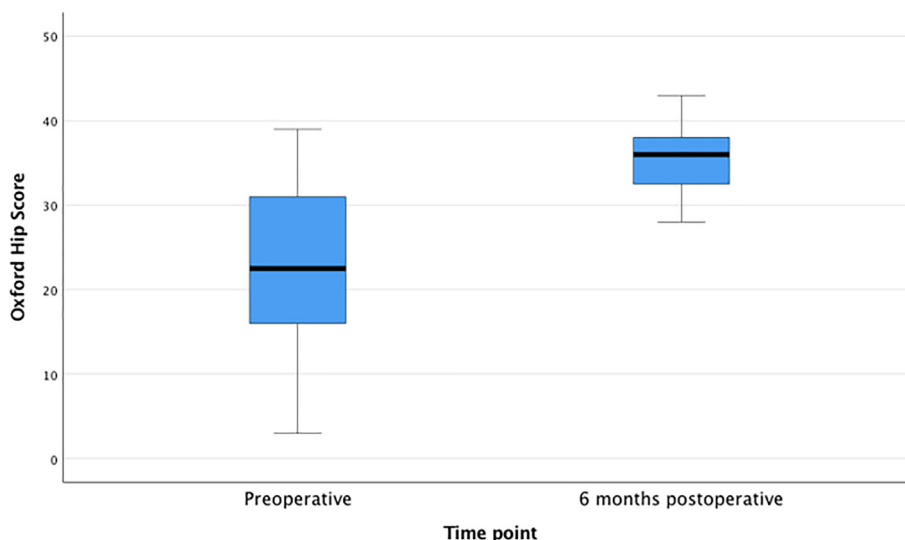


Fig. 5. Box plot showing preoperative and postoperative Oxford Hip Scores.

The 'ice-cream' cone prosthesis is an alternative to the Harrington Plus procedure for the reconstruction of extensive periacetabular defects [26,27]. A potential advantage of this procedure is that it involves a single stage and a shorter operative duration [27]. Fixation of the acetabular component is achieved with a stem introduced into the LC2 corridor of the ilium and therefore this implant may not be suitable in cases with extensive metastases within this corridor. Additionally, the smallest cup size available for the cone prostheses is 50 mm, which could necessitate unnecessary removal of non-metastatic bone and lead to anterior psoas impingement in small patients [28]. As there are limited revision options, cone prostheses may be best avoided in patients with a life expectancy of more than five years. Furthermore, despite the shorter operative duration, significant morbidity has been reported with the use of these prostheses. For example, Fisher et al found that complications occurred in 37% of cases, including dislocation in 14.8% [29]. The use of constrained liners may be needed particularly in cases where the stability is compromised due to the approach and bone excision required.

A limitation of this paper is that it is a retrospective review without a control group. However, a control group would pose ethical issues as the risk of failure with a less robust construct as a control would be devastating in this group of patients. This group of patients were palliative cases whose disease was considered too advanced for the Harrington procedure to be likely to be successful. Their disease had been considered unreconstructable otherwise and so a comparison group was not included. The small number of patients is due to the fact that this is a new technique that has only been performed in our institution. As this is not a common condition and few patients are likely to have extensive pelvic metastases that preclude other less complex surgical procedures, collaborative efforts with other units may be of value to increase the sample size for future study. It could be argued that as pain control is one of the main aims of the procedure, assessment of pre- and postoperative pain scores would have been of value. However, we have chosen to focus on mobility and overall quality of life. This is because it is likely that as the patients had limited mobility and were often not able to weight-bear preoperatively, postoperative pain scores may not provide an accurate picture of the level of improvement.

In conclusion, this paper has shown that the Harrington Plus reconstruction may be used to reconstruct significant periacetabular metastatic defects in patients. The additional stability provided

by the use of a suprapectineal plate to prevent medialisation may be particularly advantageous for advanced metastatic disease of the pelvis, including cases that traditionally have been considered un-reconstructable. The procedure is associated with significant risks; but the complication rate was not found to be greater than the original Harrington procedure and subsequent modifications. Careful patient selection and multidisciplinary management is essential.

Declaration of Competing Interest

The authors declare that they have no known competing financial interests or personal relationships that could have appeared to influence the work reported in this paper.

References

- [1] A. Piccioli, G. Maccauro, M.S. Spinelli, R. Biagini, B. Rossi, Bone metastases of unknown origin: epidemiology and principles of management, *J. Orthop. Traumatol.* 16 (2) (2015) 81–86.
- [2] A. Clain, Secondary malignant disease of bone, *Br. J. Cancer* 19 (1) (1965) 15–29.
- [3] M.T. Houdek, P.C. Ferguson, M.P. Abdel, A.M. Griffin, M. Hevesi, K.I. Perry, P.S. Rose, J.S. Wunder, D.G. Lewallen, Comparison of porous tantalum acetabular implants and Harrington reconstruction for metastatic disease of the acetabulum, *J. Bone Joint Surg. Am.* 102 (14) (2020) 1239–1247.
- [4] P.S. Issack, S.Y. Kotwal, J.M. Lane, Management of metastatic bone disease of the acetabulum, *J. Am. Acad. Orthop. Surg.* 21 (11) (2013) 685–695.
- [5] N.M. Bernthal, S.L. Price, M.J. Monument, B. Wilkinson, K.B. Jones, R.L. Randall, Outcomes of modified Harrington reconstructions for nonprimary periacetabular tumors: an effective and inexpensive technique, *Ann. Surg. Oncol.* 22 (12) (2015) 3921–3928.
- [6] P. Rowell, M. Lowe, S. Sommerville, I. Dickinson, Is an acetabular cage and cement fixation sufficiently durable for the treatment of destructive acetabular metastases?, *Clin Orthop. Relat. Res.* 477 (6) (2019) 1459–1465.
- [7] K.D. Harrington, The management of acetabular insufficiency secondary to metastatic malignant disease, *J. Bone Joint Surg.* 63 (4) (1981) 653–664.
- [8] D.G. Allan, R.S. Bell, A. Davis, F. Langer, Complex acetabular reconstruction for metastatic tumor, *J. Arthroplasty* 10 (3) (1995) 301–306.
- [9] R.M. Tillman, G.J.C. Myers, A.T. Abudu, S.R. Carter, R.J. Grimer, The three-pin modified 'Harrington' procedure for advanced metastatic destruction of the acetabulum, *J. Bone Joint Surg. Br.* 90-B (1) (2008) 84–87.
- [10] R.H. Walker, Pelvic reconstruction/total hip arthroplasty for metastatic acetabular insufficiency, *Clin. Orthop.* 294 (1993) 170–175.
- [11] T. Charles, L. Amey, M. Gebhart, Surgical treatment for periacetabular metastatic lesions, *Eur. J. Surg. Oncol.* 43 (9) (2017) 1727–1732.
- [12] R.A.W. Marco, D.S. Sheth, P.J. Boland, J.S. Wunder, J.A. Siegel, J.H. Healey, Functional and oncological outcome of acetabular reconstruction for the treatment of metastatic disease, *J. Bone Joint Surg.-Am.* Volume 82 (5) (2000) 642–651.

- [13] W.I. Faisham, D.A.J. Muslim, V.M.K. Bhavaraju, et al., Modified Harrington procedure for acetabular insufficiency due to metastatic malignant disease, *Malays Orthop. J.* 3 (1) (2009) 36–41.
- [14] G. Kask, J. Nieminen, V. van Iterson, M. Naboistsikov, T.-K. Pakarinen, M.K. Laitinen, Modified Harrington's procedure for periacetabular metastases in 89 cases: a reliable method for cancer patients with good functional outcome, especially with long expected survival, *Acta Orthop.* 91 (3) (2020) 341–346.
- [15] R. Coomber, D. Lopez, A. Carrothers, Advancement of the Harrington technique for reconstruction of pathological fractures of the acetabulum, *BMJ Case Rep.* (2018).
- [16] M. Shahid, T. Saunders, L. Jeys, R. Grimer, The outcome of surgical treatment for peri-acetabular metastases, *Bone Joint J.* 96-B (1) (2014) 132–136.
- [17] P. Tsagozis, R. Wedin, O. Brosjö, et al., Reconstruction of metastatic acetabular defects using a modified Harrington procedure, *Acta Orthop.* 86 (2015) 690–694.
- [18] J. Wegrzyn, M. Malatray, T. Al-Qahtani, V. Pibarot, C. Confavreux, G. Freyer, Total hip arthroplasty for periacetabular metastatic disease: an original technique of reconstruction according to the Harrington classification, *J. Arthroplasty* 33 (8) (2018) 2546–2555.
- [19] J. Nilsson, P. Gustafson, P. Fornander, E. Ornstein, The Harrington reconstruction for advanced periacetabular metastatic destruction: good outcome in 32 patients, *Acta Orthop. Scand.* 71 (6) (2000) 591–596.
- [20] P. Lavignac, J. Prieur, T. Fabre, J. Descamps, L. Niglis, C. Carlier, C. Bouthors, T. Baron-Trocellier, F. Sailhan, P. Bonneville. Surgical treatment of periacetabular metastatic disease: retrospective, multicenter study of 91 THA cases. *Orthopaedics Traumatol.: Surg. Res.* 20In Press.
- [21] T. Ji, W. Guo, R.-L. Yang, S. Tang, X. Sun, Clinical outcome and quality of life after surgery for peri-acetabular metastases, *J. Bone Joint Surg. Br.* 93-B (8) (2011) 1104–1110.
- [22] T. Pazonis, I. Papanastassiou, M. Maybody, J.H. Healey, Embolization of hypervascular bone metastases reduces intraoperative blood loss: a case-control study, *Clin. Orthop. Relat. Res.* 472 (2014) 3179–3187.
- [23] S. Geraets, P. Koen Bos, J. Van der Stok. Preoperative embolization in surgical treatment of long bone metastasis: a systematic literature review.
- [24] W. Kim, I. Han, H.J. Jae, S. Kang, S. Lee, M.S. Kin, H. Kim, Preoperative embolization for bone metastasis from hepatocellular carcinoma, *Orthopedics* 38 (2015) e99–e105.
- [25] M. Ratasvuori, N. Sillanpää, R. Wedin, C. Trovik, B.H. Hansen, M. Laitinen, Surgery of non-spinal skeletal metastases in renal cell carcinoma: no effect of preoperative embolization?, *Acta Orthop* 87 (2) (2016) 183–188.
- [26] I. Barrientos-Ruiz, E.J. Ortiz-Cruz, M. Peleteiro-Pensado, Reconstruction after hemipelvectomy with the ice-cream cone prosthesis: what are the short-term clinical results?, *Clin Orthop. Relat. Res.* 475 (2017) 735–741.
- [27] M. Shahid, T. Saunders, L. Jeys, R. Grimer, The outcome of surgical treatment for peri-acetabular metastases, *Bone Joint J.* 96-B (1) (2014) 132–136.
- [28] LUMIC® Surgical Technique, *Implant Cast*. <https://www.implantcast.de/en/for-medical-professionals/products/standard-tumour-prosthetics/pelvis-and-hip-endoprosthesis/revision-and-tumour-endoprosthesis/mutarsr-lumicr/>.
- [29] N.E. Fisher, J.T. Patton, R.J. Grimer, D. Porter, L. Jeys, R.M. Tillman, A. Abudu, S.R. Carter, Ice-cream cone reconstruction of the pelvis: a new type of pelvic replacement: early results, *J. Bone Joint Surg. Br.* 93-B (5) (2011) 684–688.