

## Oncology

## A rare presentation of hidradenocarcinoma within the penis

Paul Cleaveland<sup>a,\*</sup>, Prakhar Srivastava<sup>b</sup>, Pedro Oliveira<sup>a</sup>, Arie Parnham<sup>a</sup>, Tony Elliott<sup>a</sup>, Vijay Sangar<sup>a</sup>

<sup>a</sup> Christie NHS Foundation Trust, Wilmslow Road, Manchester, M20 4BX, United Kingdom

<sup>b</sup> University of Manchester, Oxford Road, M13 9PL, United Kingdom



## ARTICLE INFO

## Keywords:

Cutaneous adnexal tumour

Hidradenocarcinoma

Penile cancer

Tumour penis

## Introduction

Penile carcinoma is a rare malignancy representing 1% of male cancers. Squamous cell carcinoma accounts for 95% of all penile cancers.<sup>1</sup>

Cutaneous adnexal tumours can be benign or malignant lesions and tend to present on the head, neck and extremities. Cutaneous adnexal tumours of the penis are extremely rare and have only been reported once in the literature.<sup>2</sup> To our knowledge, metastatic spread from these tumours on the penis has never been reported before. We present a case of a malignant cutaneous adnexal tumour of the penis with progressive metastatic spread.

## Case presentation

A 46-year-old man presented with a cystic mass on the shaft of his penis. He had no significant co-morbidities. On examination, there was a mobile nodule over the left side of the distal shaft of the penis, proximal to the coronal sulcus near the frenulum, measuring 8mm in diameter. There was no palpable groin lymphadenopathy. He underwent a wide local excision of the lesion. Histological examination revealed a multi-nodular, solid-cystic and poorly differentiated carcinoma located within the dermis, measuring 15mm by 10mm with a margin of less than 5mm. On closer evaluation, the tumour resembled a high-grade and malignant cutaneous adnexal tumour of hidradenocarcinoma sub-type. It was characterised by large lobulated islands of basaloid cells, an abundance of mitotic figures and multiple foci of necrosis.

Lymphovascular invasion was present but perineal invasion was not (Figs. 1 and 2).

On immunohistochemical analysis, the tumour cells stained strongly for p16, p63, s100, MIB-1, and MNF-116, with weaker staining for 34βE12 and scanty focal staining for AE1/3, CK14, BerEP4 and epithelial membrane antigen (Fig. 3). We also performed cytogenetic analysis to search for MYB-NFIB gene fusion products which was negative, ruling out adenoid cystic carcinoma.

Initially there was no metastatic disease on imaging and surveillance was started after supra-regional multi-disciplinary cancer meeting discussion. Two years later, he developed a local recurrence that was treated with a partial penectomy. Histological examination revealed a lesion consistent with his previous disease, which was distributed within the corporal tissue and in one area of the para-urethral corpus spongiosum of the glans. There was vascular invasion and clear resection margins. Subsequent bilateral radical groin node dissection was negative for disease but one year later he developed a recurrence on the penile stump. He proceeded to have a total penectomy and perineal urethrostomy. Histological examination revealed a single well-circumscribed focus of poorly differentiated adenocarcinoma within the corpus cavernosum on the left side. Two months later he went on to develop small lung metastases which were initially observed. He then developed a left inguinal node recurrence (18 months later) which was excised. He underwent palliative radiotherapy to the left groin and lung (10 fractions to each area). A solitary metastatic deposit in the L3 vertebral body was found which compressed the cauda equine leading to surgical decompression and palliative radiotherapy. Histological

\* Corresponding author.

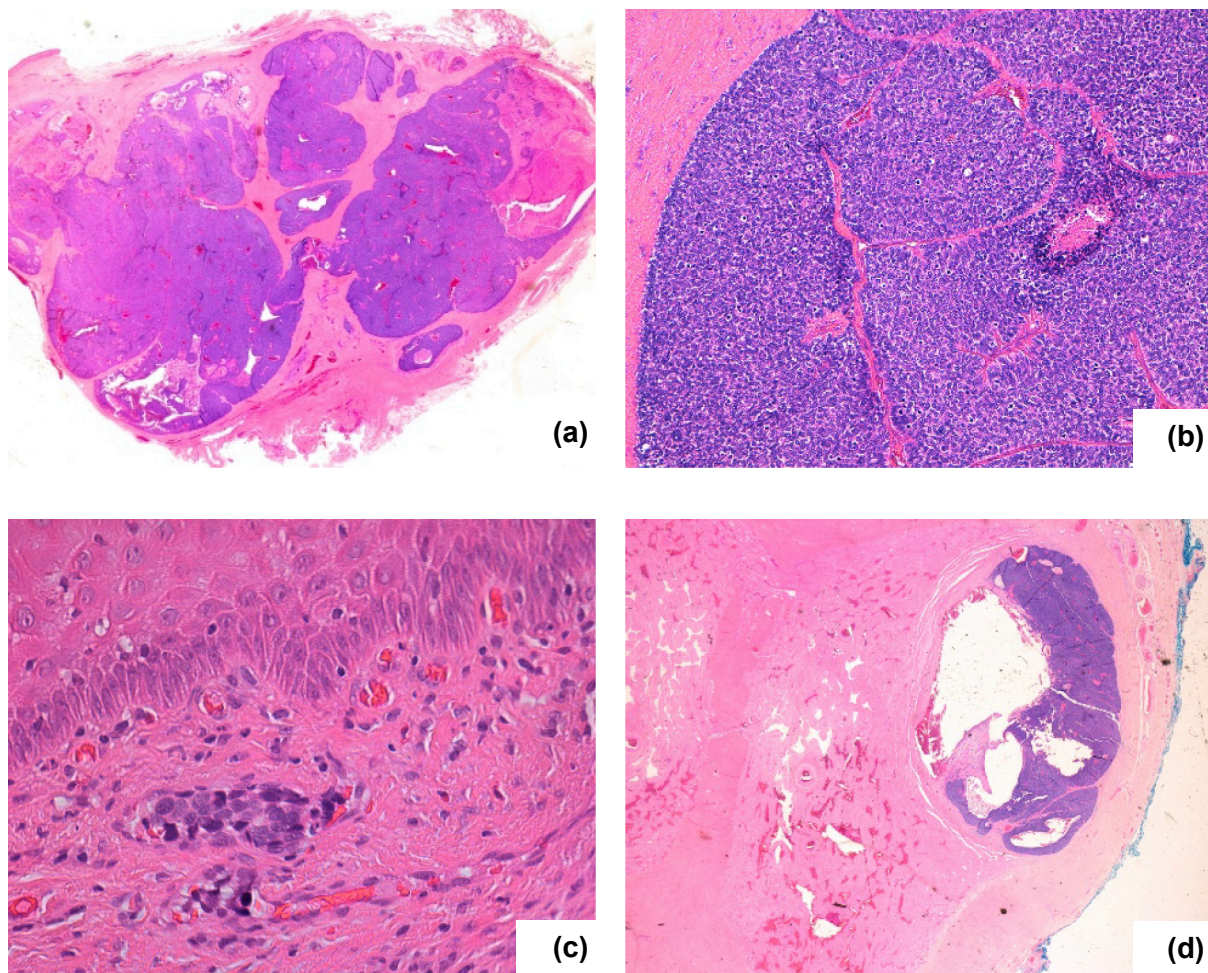
E-mail addresses: [paul.cleaveland@doctors.org.uk](mailto:paul.cleaveland@doctors.org.uk) (P. Cleaveland), [prakhar.srivastava@student.manchester.ac.uk](mailto:prakhar.srivastava@student.manchester.ac.uk) (P. Srivastava), [Pedro.Oliveira@christie.nhs.uk](mailto:Pedro.Oliveira@christie.nhs.uk) (P. Oliveira), [Arie.Parnham@christie.nhs.uk](mailto:Arie.Parnham@christie.nhs.uk) (A. Parnham), [Tony.Elliott@christie.nhs.uk](mailto:Tony.Elliott@christie.nhs.uk) (T. Elliott), [vijay.sangar@christie.nhs.uk](mailto:vijay.sangar@christie.nhs.uk) (V. Sangar).

<https://doi.org/10.1016/j.eucr.2018.10.016>

Received 27 September 2018; Accepted 23 October 2018

Available online 25 October 2018

2214-4420/© 2018 Published by Elsevier Inc. This is an open access article under the CC BY-NC-ND license (<http://creativecommons.org/licenses/by-nc-nd/4.0/>).



**Fig. 1.** H&E (haematoxylin & eosin) staining showing (a) primary lesion seen on low power view; (b) primary lesion seen on high power view; (c) primary lesion demonstrating lymphovascular invasion; (d) recurrent lesion presenting with corpora cavernosa.

examination revealed a lesion consistent with his previous disease. Finally, a right tibial metastases was irradiated.

### Discussion

Cutaneous adnexal tumours are a wide group of benign and malignant neoplasms that show morphological differentiation towards a specific type of adnexal epithelium found in the skin. They can be eccrine, apocrine, sebaceous, follicular or they can express more than one line of differentiation<sup>3</sup>. They are thought to originate from pluripotent stem cells.<sup>3</sup> Most of these tumours are benign and can be cured with local excision however, they have the potential to be metastatic<sup>3</sup>. Due to their rarity, they can pose a diagnostic challenge for pathologists.

In this unusual case, the combined histological, immunohistochemical and cytogenetic findings favoured a diagnosis of hidradenocarcinoma. Additionally, the tumour was shown to strongly express p16, a cell cycle regulatory protein whose overexpression has been associated with human papilloma virus (HPV) induced carcinogenesis within the ano-genital tract.<sup>4</sup> However, the tumour also demonstrated Ki-67 positivity in greater than 60% of cells and there is evidence indicating that this degree of proliferation is also associated with overexpression of p16, a detail which diminishes the possibility of HPV involvement.<sup>5</sup>

Given the rarity of hidradenocarcinomas, there is no consensus the best treatment regime. However, the propensity for local recurrence

and metastasis demonstrated in this case indicates that an early diagnosis followed by surgical elimination of disease is critical for optimising the prognosis. Beyond this, the use of lymph node dissection, radiation therapy and chemotherapy for either local or metastatic disease has no evidence base to work with and hence, therapeutic choices are made on a case by case basis. In this case, systemic chemotherapy had been considered for the treatment of metastatic disease but was deferred as the metastatic deposits were asymptomatic. Conversely, palliative radiotherapy was administered with success. An approach of surveillance has been taken for the remaining lung disease.

### Conclusion

Malignant adnexal tumours of the penis are rare and can exhibit very aggressive behaviour with a high proportion leading to distant metastasis<sup>3</sup>. Oncologists, Surgeons and Pathologists must have a raised awareness of these tumours which necessitate an aggressive therapeutic approach.

### Conflicts of interest

None of the contributing authors have any conflict of interest, including specific financial interests or relationships and affiliations relevant to the subject matter or materials discussed in the manuscript.



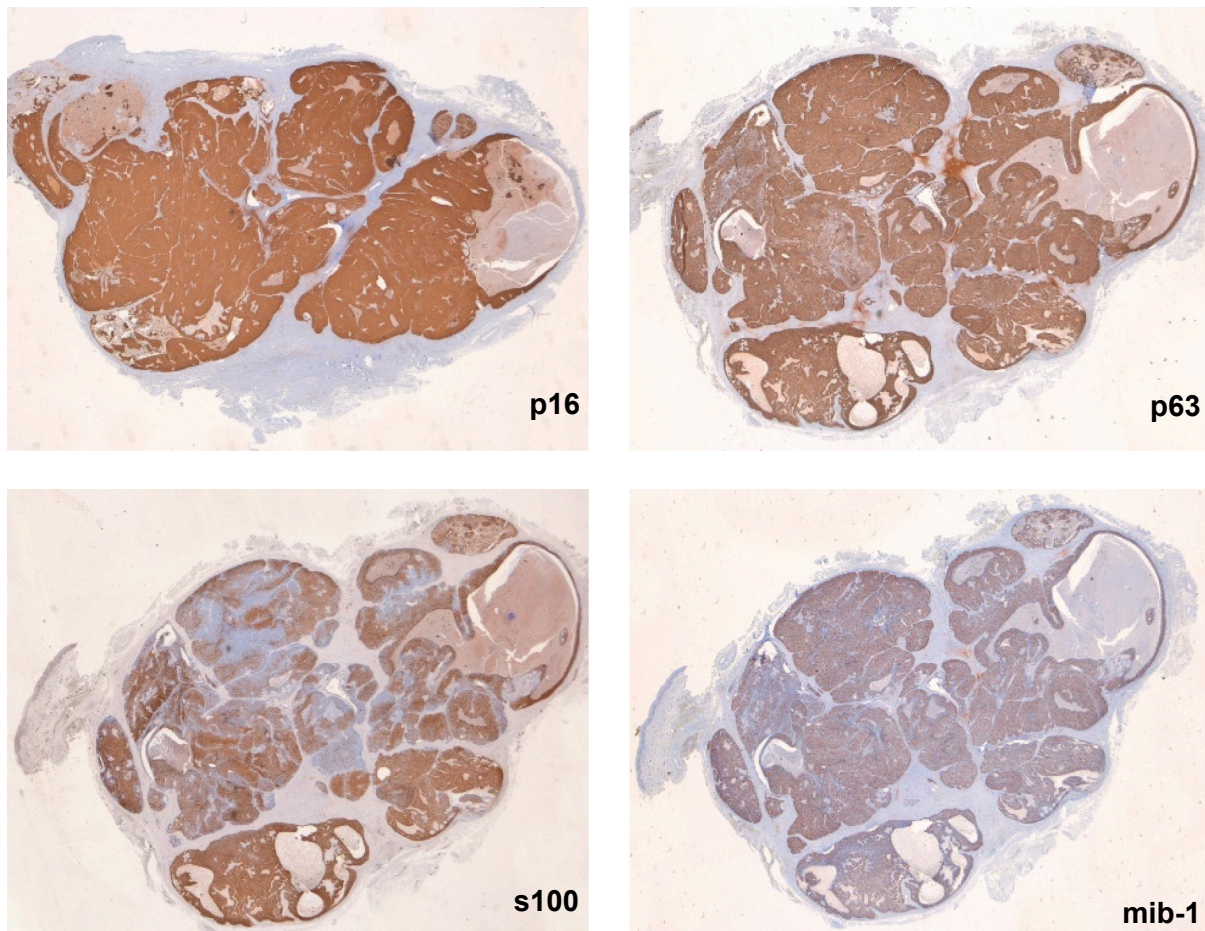


Fig. 2. Immunohistochemical analysis of the primary lesion. Strong staining was noted for the markers p16, p63, s100 and mib-1.

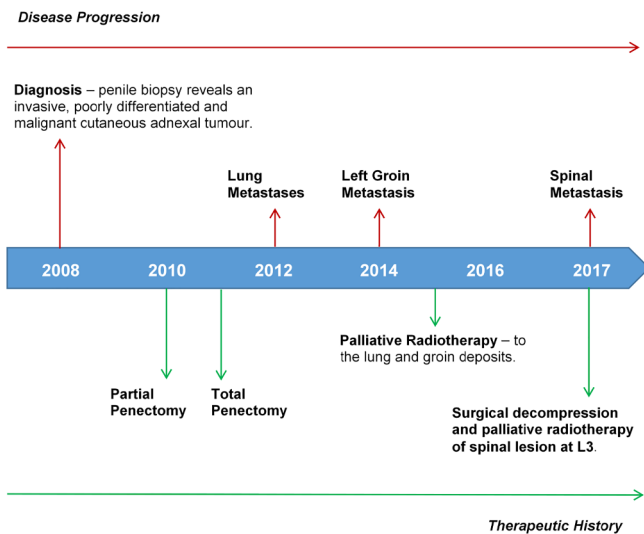


Fig. 3. A timeline of the disease evolution and therapeutic history.

### Acknowledgements

PC and PS wrote the manuscript. PS and PO provided the images and reviewed the histology. PO, AP, TE and VS reviewed and amended the manuscript.

This research did not receive any specific grant from funding agencies in the public, commercial, or not-for-profit sectors.

### References

1. European Association of Urology Guidelines on Penile Cancer. August 2017; August 2017.
2. Obaidat N, Ghazarian M. A proliferating composite adnexal tumour of the penis: report of the first case. *J Clin Pathol.* 2007;60:567–569.
3. Cotton D. Troublesome tumours 1: adnexal tumours of the skin. *J Clin Pathol.* 1991;44:543–548.
4. Sano T, Oyama T, Kashiwabara K, Fukuda T, Nakajima T. Expression status of p16 protein is associated with human papillomavirus oncogenic potential in cervical and genital lesions. *Am J Pathol.* 1998;153(6):1741–1748.
5. Conscience I, Jovenin N, Coissard C, et al. P16 is overexpressed in cutaneous carcinomas located on sun-exposed areas. *Eur J Dermatol: EJD.* 2006;16(5):518–522.