

## Case report

# A male with recurrent infections and mediastinal mass

A 63-year-old-male ex-smoker presented with a 2-week history of productive cough and shortness of breath. He had a history of coronary artery bypass grafting (CABG) surgery 20 years ago. He was diagnosed with ocular and bulbar myasthenia gravis 12 years ago with a positive anti-acetylcholine receptor antibody. He had no history of dyspnoea at rest, orthopnoea, paroxysmal nocturnal dyspnoea, cough, wheezing, or chest pain. He had three previous admissions for lower respiratory tract infections in the past 6 months. At two of the admissions, blood culture yielded *Campylobacter jejuni* and *Streptococcus pneumoniae*, respectively, which were treated accordingly. Sputum culture was negative. On clinical examination, he was conscious and orientated, temperature was 37.8°C, tachypnoeic (respiratory rate 25 breathes·min<sup>-1</sup>), tachycardic (heart rate 101 beats·min<sup>-1</sup>), blood pressure 120/70 mmHg and oxygen saturation 93% on room air. He had a normal jugular venous pressure and no pitting oedema around the ankles. Chest examination revealed reduced breath sounds and diffuse coarse crepitations in the middle and lower zones of the right lung. Blood tests showed: haemoglobin 12.4 g·dL<sup>-1</sup>, white cell count 21.9 ×10<sup>9</sup> L<sup>-1</sup> and platelets 660×10<sup>9</sup> L<sup>-1</sup>. A chest radiograph was performed (figure 1).

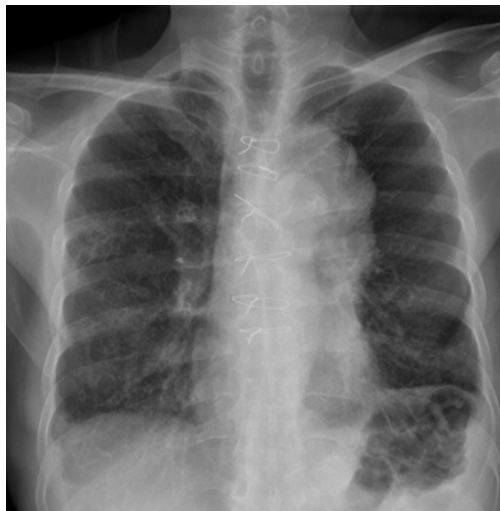

Figure 1 Chest radiograph.

**Cite as:** Hamid FA, Hasbullah AHH, Ban AYL. A male with recurrent infections and mediastinal mass. *Breathe* 2020; 16: 200065.

### Task 1

What is your provisional clinical diagnosis?

### Task 2

Can you describe the chest radiograph taken on admission (figure 1)?

**Answer 1**

Community acquired pneumonia (CAP).

This patient was started on amoxicillin/clavulanate and azithromycin. This empiric antibiotic combination was chosen as he had non-severe CAP without risk factors for *Pseudomonas aeruginosa*. This is following the American Thoracic Society/Infectious Disease Society of America clinical guidelines on CAP [1]. He was also initiated on oxygen therapy to keep his saturation >94%. The British Thoracic Guidelines for CAP recommend initial oxygen saturation to be kept between 94 to 98% when a patient with pneumonia is hypoxic [2]. In this patient blood and sputum culture was negative.

**Answer 2**

The chest radiograph shows air space opacities in the right middle zone. There is presence of sternal wires in keeping with past history of CABG. There is also an incidental finding of a widened mediastinum.

The mediastinum is said to be widened when the width is >6-8 cm. The mediastinum is an anatomic space which contains vital structures. It can be divided into the pre-vascular (anterior), visceral (middle) and paravertebral (posterior). The pre-vascular component contains the thymus, fat, lymph nodes and left brachiocephalic vein. The visceral components are trachea, carini, oesophagus, lymph nodes, heart, aorta, superior vena cava, intrapericardial pulmonary arteries and thoracic duct. The paravertebral component is paravertebral soft tissues [3].

The patient may likely have a pre-vascular (anterior) tumour. In view of the history of myasthenia gravis we entertained the diagnosis of a thymoma. He improved after 5 days of amoxicillin/clavulanate and azithromycin.

**Task 3**

What investigation can be done to evaluate the widened mediastinum?

**Answer 3**

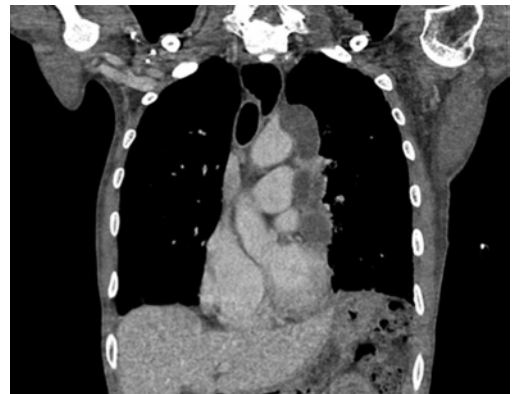Contrasted computed tomography (CT) of the thorax.

A contrasted CT of the thorax was performed (figure 2) and showed a pre-vascular (anterior) mediastinal mass measuring 3.0×7.0×12.0 cm with foci of calcification within, with possible invasion to the left brachiocephalic vein.

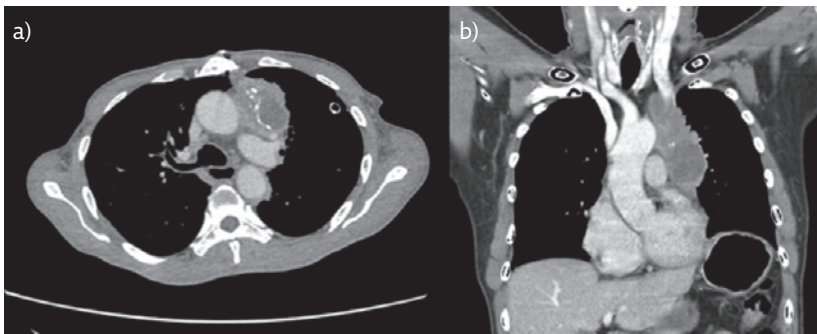
The differential diagnosis of pre-vascular mediastinal tumours include thymoma, teratoma/germ cell tumour and lymphoma. In this patient, the anti-striated antibody was positive. Both serum beta-human chorionic gonadotrophin and alpha feto-protein level were normal. The likely diagnosis was a thymoma.

**Task 4**

Describe the CT scan of the thorax (figure 3).



**Figure 3** Computed tomography of the thorax mediastinal window (coronal view).



**Figure 2** Computed tomography of the thorax mediastinal window. a) Axial view and b) coronal view.

**Answer 4**

A CT scan of the thorax mediastinal window (coronal view) revealed a left pre-vascular (anterior) mediastinal mass with poor demarcation with mediastinal great vessels, and mass effect onto the left brachiocephalic vein.

On further questioning, the patient gave a history of video-assisted thoracoscopic surgery performed 12 years ago. Histopathological examination showed a thymic lipoma. On comparison of the CT scans, the thymoma had increased in size. In view of the increase in size of the thymoma and the recurrent symptoms of myasthenia gravis, he was scheduled for a repeat resection of the residual tumour. However, intraoperatively the tumour was inoperable due to its invasiveness involving the pericardium and major vessels, thus surgery was abandoned. Histopathological examination from the biopsy of the tumour showed thymoma AB variant.

He declined chemotherapy and was maintained on a steroid sparing agent, azathioprine 100 mg daily and pyridostigmine 60 mg twice daily. He went on to have three separate episodes of chest infections requiring hospital admissions over a period of 6 months. Sputum culture from one of the admissions grew *Pseudomonas aeruginosa* and despite treatment he was readmitted with pneumonia within 1 month.

**Task 5**

What diagnostic investigation would you consider at this point?

**Answer 5**

Immunoglobulin (Ig) levels.

In view of the history of recurrent episodes of chest infections the Ig levels were checked. The Ig panel showed: IgG  $542 \text{ mg}\cdot\text{dL}^{-1}$  (normal range  $700\text{--}1600 \text{ mg}\cdot\text{dL}^{-1}$ ), IgA  $26 \text{ mg}\cdot\text{dL}^{-1}$  ( $70\text{--}400$ ), and IgM  $16.8 \text{ mg}\cdot\text{dL}^{-1}$  ( $40\text{--}230$ ). There was an increase in CD8+ T-cells and absence of B-cells with an inverted CD4:CD8 ratio. In this patient, decreased Ig levels suggest a secondary cause of immune deficiency.

**Task 6**

What is the likely diagnosis?

### Answer 6

Good syndrome.

With the evidence of hypogammaglobulinaemia, thymoma and multiple episodes of chest infections, we made a diagnosis of Good syndrome. Good syndrome is a rare disease characterised by adult-onset immunodeficiency with co-existing thymoma and hypogammaglobulinaemia. He was initiated on periodic intravenous Ig (IVIg) to maintain adequate Ig levels. He received a total of 18 cycles of IVIg, with significant reduction of recurrent infections.

## Discussion

Good syndrome is a rare association of thymoma and immunodeficiency first described in 1954 by Robert Good [4]. The reported incidence is 0.15 cases per 100000 population per year in the USA [5]. Patients usually present in the fourth to fifth decade of life either with the diagnosis of thymoma or with severe or chronic infections complications secondary to their immunodeficiency. Pulmonary infection is the most common infectious complication [6]. Bronchiectasis has been reported in up to 45% of patients with Good syndrome [7].

Thymomas are rare slow growing tumours which metastasises to the pleural, pericardium or diaphragm and less commonly to extrathoracic regions [8]. The widely used classification is the four clinical stage Masaoka staging which is based on the extent of local extension. The treatment ranges from complete resection of the thymus in stage 1, combination of chemotherapy neoadjuvant or adjuvant with or without surgery to sequential chemotherapy followed by radiation to individualised therapy in stage IVB [9]. The tumour, node, metastasis staging has also been proposed for evaluating thymoma and thymic carcinoma [10]. It provides information on nodal

involvement and dissemination of the tumour which can be clinically useful to direct therapy.

Thymomas can recur even after complete resection has been performed [11]. The diagnosis of thymoma may precede the diagnosis of hypogammaglobulinaemia from as little as 3 months to 18 years and the most common reported histologic type is the AB variant [12].

This syndrome was initially classified as a subset of common variable immunodeficiency [12]. The immunological findings are hypogammaglobulinaemia, few or absent B-cells, an abnormal CD4+:CD8+ T-cell ratio, CD4 T-cell lymphopenia with impaired T-cells mitogenic responses. Patients with Good syndrome usually have reduced serum IgG, IgA and IgM [6]. Good syndrome should be suspected in patients aged >40 years with evidence of antibody deficiency.

The reported mortality for Good syndrome is 46% with the prognosis depending on the severity of associated infectious, haematologic and autoimmune diseases [12]. The prognosis is believed to be worse than other immunodeficiencies [13]. The mainstay of management is thymectomy or debulking of the thymus and Ig replacement [12]. Treatment with Ig maintains a certain level of Ig and prevents infections whilst thymectomy prevents locally invasive growth and metastasis of thymoma.

The aim of IVIg treatment is to bring the IgG trough level >500 mg·dL<sup>-1</sup>. This has been found to decrease infections and improve lung function in primary immunodeficiency [14]. A recent study by PEREZ *et al.* [15] recommended the dosage of IVIg be dependent on a patient's clinical outcome. This suggests that different patients may need higher trough levels to maintain a stable clinical condition.

Good syndrome should be suspected in a patient aged >40 years with thymoma and recurrent infections and unexplained antibody deficiency. It has a significant mortality, therefore, early detection is important. A high index of suspicion and relevant investigations are required to diagnose and treat infections appropriately.

### Affiliations

Faisal Abdul Hamid, Ahmad Hadyan Husainy Hasbullah, Andrea Yu-Lin Ban

Respiratory Unit, Dept of Medicine, Faculty of Medicine, Universiti Kebangsaan Malaysia Medical Centre, Kuala Lumpur, Malaysia.

### Conflict of interest

F.A. Hamid has nothing to disclose. A.H.H. Hasbullah has nothing to disclose. A. Y-L. Ban has nothing to disclose.

### References

1. Metlay JP, Waterer GW, Long AC, *et al.* Diagnosis and treatment of adults with community-acquired pneumonia. An official clinical practice guideline of the American Thoracic Society and Infectious Diseases Society of America. *Am J Respir Crit Care Med* 2019; 200: e45–e67.
2. Levy ML, LeJeune I, Woodhead MA, *et al.* Primary care summary of the British Thoracic Society Guidelines for the management of community acquired pneumonia in adults: 2009 update. Endorsed by the Royal College of General Practitioners and the Primary Care Respiratory Society UK. *Prim Care Respir J* 2010; 19: 21–27.
3. Carter BW, Tomiyama N, Bhora FY, *et al.* A modern definition of mediastinal compartments. *J Thorac Oncol* 2014; 9: Suppl. 2, S97–S101.

4. Kelleher P, Misbah SA. What is Good's syndrome? Immunological abnormalities in patients with thymoma. *J Clin Pathol* 2003; 56: 12–16.
5. Malphettes M, Gérard L, Galicier L, *et al.* Good syndrome: an adult-onset immunodeficiency remarkable for its high incidence of invasive infections and autoimmune complications. *Clin Infect Dis* 2015; 61: e13–e19.
6. Tarr PE, Sneller MC, Mechanic LJ, *et al.* Infections in patients with immunodeficiency with thymoma (Good syndrome): report of 5 cases and review of the literature. *Medicine (Baltimore)* 2001; 80: 123–133.
7. Fox MA, Lynch DA, Make BJ. Thymoma with hypogammaglobulinemia (Good's syndrome): an unusual cause of bronchiectasis. *AJR Am J Roentgenol* 1992; 158: 1229–1230.
8. Regnard JF, Magdeleinat P, Dromer C, *et al.* Prognostic factors and long-term results after thymoma resection: a series of 307 patients. *J Thorac Cardiovasc Surg* 1996; 112: 376–384.
9. Falkson CB, Bezjak A, Darling G, *et al.* The management of thymoma: a systematic review and practice guideline. *J Thorac Oncol* 2009; 4: 911–919.
10. Dettnerbeck F, Stratton K, Giroux D, *et al.* The IASLC/ITMIG Thymic Epithelial Tumors Staging Project: proposal for an evidence-based stage classification system for the forthcoming (8th) edition of the TNM classification of malignant tumors. *J Thorac Oncol* 2014; 9: Suppl. 2, S65–S72.
11. Awad WI, Symmans PJ, Dussek JE. Recurrence of stage I thymoma 32 years after total excision. *Ann Thorac Surg* 1998; 66: 2106–2108.
12. Kelesidis T, Yang O. Good's syndrome remains a mystery after 55 years: a systematic review of the scientific evidence. *Clin Immunol* 2010; 135: 347–363.
13. Tarr PE, Sneller MC, Mechanic LJ, *et al.* Infections in patients with immunodeficiency with thymoma (Good syndrome): report of 5 cases and review of the literature. *Medicine (Baltimore)* 2001; 80: 123–133.
14. Roifman CM, Schroeder H, Berger M, *et al.* Comparison of the efficacy of IGIV-C, 10% (caprylate/chromatography) and IGIV-SD, 10% as replacement therapy in primary immune deficiency: a randomized double-blind trial. *Int Immunopharmacol* 2003; 3: 1325–1333.
15. Perez EE, Orange JS, Bonilla F, *et al.* Update on the use of immunoglobulin in human disease: a review of evidence. *J Allergy Clin Immunol* 2017; 139: S1–S46.