

# Mandibular regeneration after immediate load dental implant in a periodontitis patient

## A clinical and ultrastructural case report

Maurizio Catinari, MD<sup>a</sup>, Manuel Scimeca, PhD<sup>b,c,\*</sup>, Massimo Amorosino, MD<sup>a</sup>, Mario Marini, Doctor<sup>d</sup>, Elena Bonanno, MD, PhD<sup>b</sup>, Virginia Tancredi, MD<sup>d</sup>

### Abstract

**Rationale:** In this case study, we characterized from radiographic, morphological and elemental point of view the mandibular reconstruction that occur in patients affects by periodontitis after application of endosseous titanium implants. In particular, we verified that the bone load applied by titanium implant was able to induce the mandibular osteogenic reconstruction.

**Patient concern:** A 57-year-old female active smoker with no contraindications for dental implants and 3 unstable dental prostheses, underwent open surgery for the application of endosseous titanium implants (BANP IMPLANT S.R.L., Milan, MI, Italy) with Immediate load dental implant technique. At the time of presentation, patient was under treatment  $\beta$ - beta-adrenergic agents.

**Diagnoses:** Patient was affected by grade II periodontitis according to Armitage classification.

**Intervention:** Patient underwent open surgery for the application of endosseous titanium implants (BANP IMPLANT S.R.L., Milan, MI, Italy) with Immediate load dental implant technique. Implant placement was performed under local anesthesia after premedication with diazepam (0.2 mg/kg), given orally 30 minutes before surgery. After crestal incision, a meticulous cleaning of the oral cavity was carried out. We removed necrotic tissues and all inflammatory residues. Then, the bone cavity was extended gradually, according to the intended implant diameter. Inserted titanium implants were placed 8–12 mm subcrestally.

**Outcomes:** We demonstrated that the bone load applied by titanium implant was able to induce the mandibular osteogenic reconstruction in a periodontitis patient.

**Lessons:** This case study can lay the foundation to improve understanding of the relationship between the immediate load dental implant and the mandibular regeneration.

**Abbreviations:** ATW = atmospheric thin window, EDX = energy-dispersive X-ray, IIs = interleukins, SEM = scanning electron microscopy.

**Keywords:** bone regeneration, endosseous titanium implants, immediate load dental implant, osteoblasts, osteogenic stimulation, periodontitis

Editor: Li Wu Zheng.

The study is original and the manuscript has not been published yet and is not being considered for publication elsewhere in any language either integrally or partially except as an abstract.

All the authors have agreed with the submission in its present (and subsequent) forms.

MC and MS equally contributed to the work.

This work was supported by BANP IMPLANT SRL, Milan (MI), Italy.

The authors have no conflicts of interest to disclose.

<sup>a</sup> Studio Dentistico Catinari, <sup>b</sup> Department of Experimental Medicine and Surgery, University of Rome Tor Vergata, <sup>c</sup> Orchidea Lab S.r.l., <sup>d</sup> Department of Systems' Medicine, University of Rome Tor Vergata, Rome, Italy.

\* Correspondence: Manuel Scimeca, Department of Experimental Medicine and Surgery, University of Rome Tor Vergata, Via Montpellier 1, Rome 00133, Italy; Orchidea Lab S.r.l., via del Grecale 6, Morlupo, Rome (RM), Italy (e-mail: manuel.scimeca@uniroma2.it).

Copyright © 2017 the Author(s). Published by Wolters Kluwer Health, Inc. This is an open access article distributed under the terms of the Creative Commons Attribution-NonCommercial-ShareAlike 4.0 License, which allows others to remix, tweak, and build upon the work non-commercially, as long as the author is credited and the new creations are licensed under the identical terms.

Medicine (2017) 96:15(e6600)

Received: 17 January 2017 / Received in final form: 17 March 2017 / Accepted: 19 March 2017

<http://dx.doi.org/10.1097/MD.0000000000006600>

## 1. Introduction

Periodontitis is defined as an inflammatory disease of the supporting tissues of the tooth, caused especially by gram-negative bacteria, resulting in progressive destruction of the bone-supporting tissues of the tooth.<sup>[1]</sup> The undeniable role of bacterial infection in the pathogenesis of the periodontitis is known to be accompanied by the individual's immune and inflammatory response under the influence of external, such as dental plaque, and internal factors.<sup>[2]</sup> However, the dental plaques represent the main risk factors related to periodontitis occurrence and development.<sup>[3]</sup>

From the epidemiological point of view, there are an increasing proportion of adults retaining their teeth until late in life,<sup>[4]</sup> and, nowadays, periodontal disease is a serious problem in older adults.<sup>[5]</sup> Moreover, the risk of the concomitants oral problems, such as root caries, tooth mobility, and tooth loss, can be increased by the presence of periodontal disease, which has also been associated with a growing list of chronic systemic diseases and impaired cognition.<sup>[3]</sup>

Dental implant science has rapidly moved into the mainstream of dentistry in the last 10 years with a phenomenal growth based on rapidly expanding technology, increasing public interest, and the reporting of sound scientific data.<sup>[6]</sup> Indeed, dental implants have been widely used to retain and support cross-arch fixed

dentures.<sup>[6]</sup> The introduction of immediate loading was a paradigm shift in implant dentistry as it was previously believed that an unloaded period was essential for bone healing to promote osseointegration. However, this belief could not be confirmed by clinical studies or by human histology.<sup>[7]</sup> Immediate load dental implant is a surgical technique that allows the placement of a temporary tooth during the same appointment as dental implant placement.<sup>[7]</sup> Several studies demonstrated that the use of immediate implant loading reported has a similar success rate if compared with the traditional approach.<sup>[6,7]</sup> Despite the numerous clinical evidence, the cellular and molecular mechanisms in which the immediate load applied by dental implant can induce the bone reconstruction are still unknown.

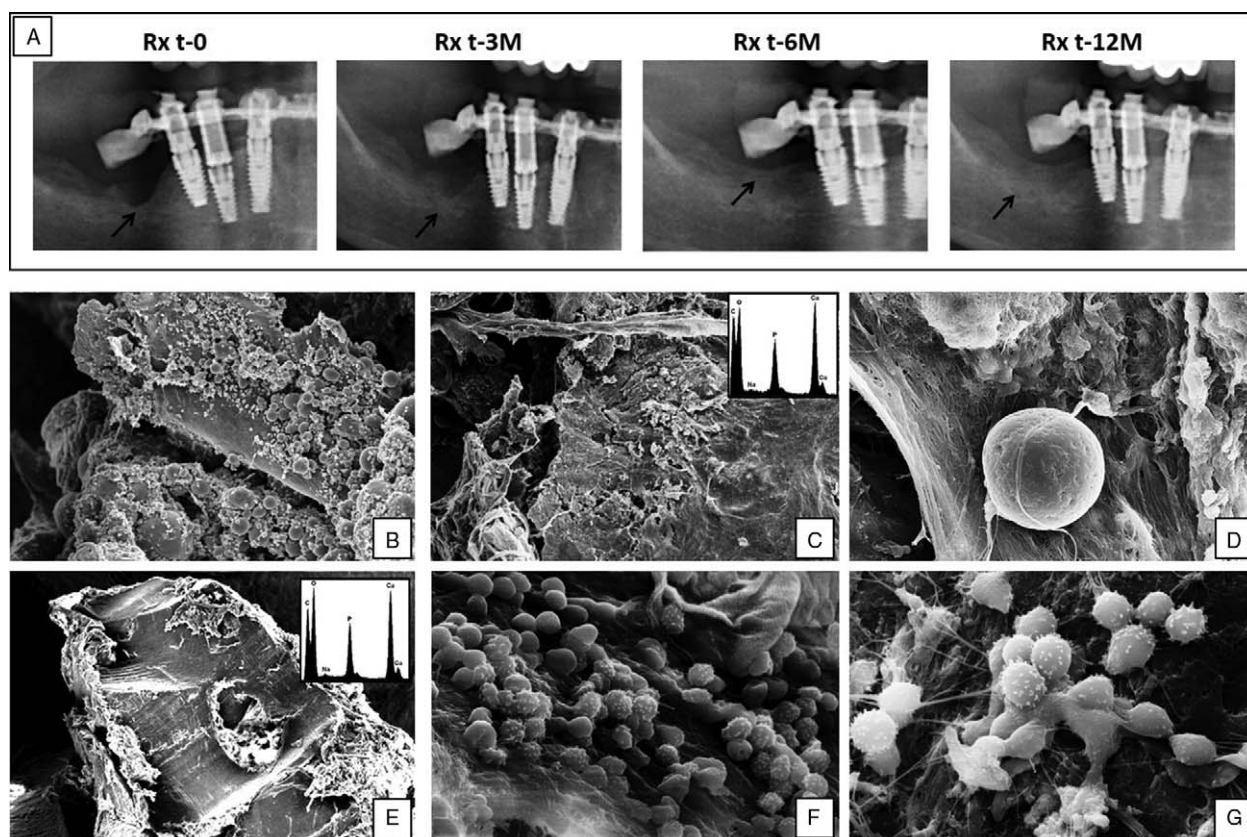
In this case study, we characterized from radiographic, morphological, and elemental points of view the mandibular reconstruction that occurs in patients affected by periodontitis after application of endosseous titanium implants. In particular, we verified that the bone load applied by titanium implant was able to induce the mandibular osteogenic reconstruction.

## 2. Cases report

A 57-year-old female affected by grade II periodontitis according to Armitage classification,<sup>[8]</sup> active smoker with no contraindications for dental implants and 3 unstable dental prostheses,

underwent open surgery for the application of endosseous titanium implants (BANP IMPLANT SRL, Milan, MI, Italy) with Immediate load dental implant technique. At the time of presentation, the patient was under treatment  $\beta$ -adrenergic agents. Anatomic conditions and pathology of the mandible were evaluated by panoramic radiograph. In particular, the panoramic radiograph provided information about jaw size, bone volume, jaw relations, intermaxillary distance, occlusal relation, and conditions of the opposing dentition or jaw. Implant placement was performed under local anesthesia after premedication with diazepam (0.2 mg/kg), given orally 30 minutes before surgery. After crestal incision, a meticulous cleaning of the oral cavity was carried out. We removed necrotic tissues and all inflammatory residues. Then, the bone cavity was extended gradually, according to the intended implant diameter, following the manufacturer's instructions.<sup>[9]</sup> Inserted titanium implants were placed 8 to 12 mm subcrestally. Postoperative medications included antibiotics (1000 mg amoxicillin and clavulanic acid twice daily for 7 days, starting on the day of surgery); an analgesic (600 mg ibuprofen as required every 6 hours); and 0.2% chlorhexidine mouthwash twice daily for 2 weeks, starting on the day after surgery.

Radiological digital images were acquired at the time of surgery and after 24 hours, 40 days, 3, 6, and 12 months by using a Digital Cephalometric + Panoramic X Ray (Orthoralix 9200,



**Figure 1.** Radiographic and ultrastructural evidence of mandibular regeneration. A, Radiological analysis demonstrates the increase of both bone mass and density after the application of endosseous titanium implants. Arrows indicate the areas of bone regeneration. B–D, Scanning electron microscopy analysis of biopsy withdrawn at the time of surgery. B, Electron micrograph shows the presence of numerous macrophages, lymphocyte, and cells detritus on degenerated bone surface ( $\times 70$ ). C, High magnification displays a cluster of osteoclast cells ( $\times 300$ ). Energy-dispersive X-ray spectrum demonstrates that the analyzed sample is made of hydroxyapatite. D, Image shows an isolated osteoclast on bone surface ( $\times 1000$ ). E–G, Scanning electron microscopy analysis of biopsy withdrawn at the control visit (12 mo). E, Bone biopsy is characterized by compact bone with typical lamellar structure ( $\times 70$ ). F, Energy-dispersive X-ray spectrum demonstrates that the lamellar structure is made of hydroxyapatite ( $\times 120$ ). G, Image displays several osteoblast cells on the bone surface ( $\times 300$ ).

DentalPlanet's Corporate, Wichita Falls, TX). Digital images were used to evaluate mandibular reconstruction and bone density. Radiological analysis showed a constant increase of mandibular area in all control visits (Fig. 1A). Noteworthy, it was possible to observe an increase of both mandibular area and density already after 90 days (Fig. 1A). No inflammation or other side effects were observed. All the implants had a satisfactory primary stability. At 12 months of follow-up, all the implants were considered to be successful. At the time of surgery and at the visit control (12 months) small fragments of mandibular bone, not helpful for diagnostic or surgical procedure, were collected for ultrastructural and microanalytical analysis. In particular, the small fragments of mandibular bone were withdrawn during the open surgery by using bur bone and surgical tweezers. At T0 mandibula fragment of 1 to 3 mm in diameters was withdrawn in correspondence of the coring carried out for the implant. Conversely, during control visit mandibula fragment of 1 to 3 mm in diameters was withdrawn at a maximum distance of 15 mm of the implant. For scanning electron microscopy (SEM) procedure, mandibular biopsies were fixed in 4% (v/v) paraformaldehyde for 24 hours. After washing with 0.1 M phosphate buffer, the sample was dehydrated by a series of incubations in 30%, 50%, and 70% (v/v) ethanol. Dehydration was continued by incubation steps in 95% (v/v) ethanol, absolute ethanol, and acetone. Critical point drying (Agar Scientific, Essex, UK; Elektron Technology UK Ltd, Cambridge, UK) with supercritical carbon dioxide was then performed to prevent cell deformation.<sup>[10]</sup> A SEM LEO 1450VP (Carl Zeiss Meditec, Oberkochen, Germany) was employed to acquire backscattered electron images using 20 keV electrons leading to an information depth of about 1.5  $\mu$ m. Images with a scan size of 30  $\times$  30  $\mu$ m were acquired, at a resolution of 1024  $\times$  1024 pixels. The energy-dispersive X-ray (EDX) microanalysis performs the chemical analysis of a sample describing the elemental composition of a tissue utilizing electron microscopy techniques. When the electron beam in an electron microscope hits a thin sample, some atoms of the sample will be excited or ionized. When they return into their ground state, they will emit characteristic X-rays.<sup>[11]</sup> The X-ray emission at different wavelengths may then be measured by a photon-energy-sensitive detector. EDX microanalysis was performed on unpost-fixed and uncoated mandibular biopsies were placed on specific stub using a liquid N<sub>2</sub>-cooled Si detector with a super-ultrathin Be window. Spectra were collected by a SEM LEO 1450VP scanning electron microscope at an acceleration voltage of 5 KeV employing an area scan mode (640  $\times$  640  $\mu$ m sampling area), 300 seconds acquisition time, and 32% to 37% detector dead time. Analysis of acquired spectra was performed under a nonstandard mode using atomic number-absorption-fluorescence correction methods using Inca Energy software (Oxford Instruments Ltd, High Wycombe, UK; Si(Li) detector, atmospheric thin window (ATW), resolution 133 eV for MnK $\alpha$  at 10,000 counts). For each specimen, we acquire at least 2 spectra on 8 mm<sup>2</sup> of sample surface in total.

All experimental procedures were carried out in accordance with the approved guidelines. Informed consent was obtained from patient prior to surgery. Specimens were handled and carried out in accordance with the approved guidelines.

### 2.1. Ultrastructural and pathological evaluation

Scanning electron microscopy analysis allowed us to characterize the ultrastructure of mandibular biopsies of a patient who underwent open surgery for the application of endosseous titanium implants (Fig. 1). The bone fragments withdrawn at the

time of surgery showed the presence of several micro-fractures, osteoblasts, osteoclasts, inflammatory cells, mainly macrophages, and numerous cellular debris (Fig. 1B–D). These morphological appearances were compatible with the bone loss observed at the radiographic examinations. Indeed, the presence of several macrophages and osteoclasts suggests an active phase of bone resorption. On note, ultrastructural analysis confirmed the bone regeneration induced by the application of endosseous titanium implants in a mandibular biopsy withdrawn 12 months after surgery. In particular, bone biopsy was characterized by compact bone with typical lamellar structure (Fig. 1E). As concern cells population, the sample displayed numerous clusters of osteoblast cells (Fig. 1F and G). Noteworthy, no osteoclast cells were observed. Thanks to SEM-EDX microanalysis, we demonstrated that both the samples withdrawn at the time of surgery and after 12 months were made of hydroxyapatite (Fig. 1C and F). These data confirmed that the immediate load applied by endosseous titanium implants induces the bone regenerations and matrix deposition in patients affected by periodontitis.

### 3. Discussions

Periodontitis is a dental disease characterized by bone tissue destruction that mainly occurs in adults  $\geq 65$  years.<sup>[12]</sup> The older adult population is growing rapidly in the industrialized countries and it is expected that by 2040 the number of elders will have increased by about 50%.<sup>[12]</sup> The increase of life expectation in the world population makes the oral health status a very important factor for the quality of life. Today, the new advanced surgical techniques in dental implantology allow us to reestablish the most important functions of dental apparatus. In this context, the application of immediate load dental implant represents one of the most promising surgical options for periodontitis patients with severe bone loss. Indeed, numerous clinical studies reported the reconstruction of mandibular after open surgery.<sup>[7,13]</sup> Notwithstanding this clinical evidence, the cellular and molecular mechanisms in which the immediate load applied by dental implant can induce the bone reconstruction are still unknown. In addition, to the best of our knowledge, no study reported histological or ultrastructural proofs of the bone reconstruction induced by immediate load. In this case study, we performed SEM and EDX analysis in order to characterize the elemental composition, ultrastructural characteristics, and cell population of new formed bone. To this end, we analyzed the mandibular biopsies of a 57-year-old female who underwent open surgery for the application of endosseous titanium implants with Immediate load dental implant technique. Results of our study demonstrated that the immediate load technique is able to induce the bone reconstruction influencing the composition of bone population. The mandibular biopsy withdraws at the time of surgery showed many similarities with the bone of osteoporotic patients. Indeed, we observed an imbalance between the rates of osteoblasts and osteoclasts. The presence of numerous osteoclast cells suggests that the bone loss, typical of periodontitis patients, is due to bone resorption mediated by activated osteoclasts. This phenomenon can be linked to the presence of inflammatory cells on bone surface. Indeed, it knows that inflammatory cytokines, such as interleukines (ILs), are potent osteoclasts activator.<sup>[14]</sup> The antibiotic therapy and the deletion of all inflammatory sites during open surgery could represent a fundamental step for mandibular regeneration. Indeed, in our experience, a meticulous cleaning of the oral cavity accelerates the

bone reconstruction and the implant stability. The ultrastructural analysis of newly formed bone showed the absence of inflammatory cells and no/rare osteoclasts. Thus, we can speculate that the application of immediate load dental implant influences bone metabolism inducing the recruitment and differentiation of osteoblasts. Indeed, as shown in Fig. 1, the surface of new bone presents numerous clusters of these cells. The finding of mechanoreceptors on the surface of bone cells (osteoblasts, osteoclast, and osteocytes)<sup>[15,16]</sup> could be the biological connection between the application of immediate load dental implant and the bone reconstruction. In fact, the stimulation of osteoblasts mechanoreceptors can explain the reactivation of bone metabolism and the production of bone matrix. Then, the formation of the new bone matrix can explain the stability of dental implants that we observed in all control visits.

Summing up, in this case study, for the first time we described the cellular and ultrastructural change induced by immediate load dental implant on the mandibular of a periodontitis patient. Nevertheless, further studies are needed to elucidate the cellular and molecular mechanisms of the bone regeneration observed in patients who underwent open surgery for the application of endosseous titanium implants.

#### 4. Conclusions

This case study can lay the foundation to improve understanding of the relationship between the immediate load dental implant and the mandibular regeneration.

##### 4.1. Strengths and limitations

The strengths of the management of this case are represented by the possibility to follow the clinical course of the patient 12 months. Such a period of follow-up enabled us to evaluate the mandibular regeneration and the stability of the implants during a long period with accuracy and precision. Conversely, the limitation of the management of this case may be represented by the absence of a case control.

#### References

- [1] Saini R, Marawar PP, Shete S, et al. Periodontitis, a true infection. *J Glob Infect Dis* 2009;1:149–50.
- [2] Bolerázska B, Mareková M, Markovská N. Trends in laboratory diagnostic methods in periodontology. *Acta Medica (Hradec Kralove)* 2016;59:3–9.
- [3] Van Dyke TE, Sheilesh D. Risk factors for periodontitis. *J Int Acad Periodontol* 2005;7:3–7.
- [4] Bullon P, Pugnali A, Gallardo I, et al. Ultrastructure of the gingiva in cardiac patients treated with or without calcium channel blockers. *J Clin Periodontol* 2003;30:682–90.
- [5] Machuca G, Segura-Egea JJ, Jiménez-Beato G, et al. Clinical indicators of periodontal disease in patients with coronary heart disease: a 10 years longitudinal study. *Med Oral Patol Oral Cir Bucal* 2012;17:e569–74.
- [6] McKinney RV Jr, Stefflick DE, Koth DL, et al. The scientific basis for dental implant therapy. *J Dent Educ* 1988;52:696–705.
- [7] De Bruyn H, Raes S, Ostman PO, et al. Immediate loading in partially and completely edentulous jaws: a review of the literature with clinical guidelines. *Periodontol* 2000 2014;66:153–87.
- [8] Armitage GC. Development of a classification system for periodontal diseases and conditions. *Ann Periodontol* 1999;4:1–6.
- [9] IL RUOLO DELLA GENGIVA ADERENTE SU IMPIANTI PLATFORM SWITCHING A CONNESSIONE C-E (CONOMETRICA-ESAGONALE). Available at: <http://banpimplant.com/News/il-ruolo-della-gengiva-aderente-su-impianti-platform-switching-a-connes-sione-c-e-conometrica-esagonale-8>. [Accessed January 2013].
- [10] Scimeca M, Feola M, Romano L, et al. Heavy metals accumulation affects bone microarchitecture in osteoporotic patients. *Environ Toxicol* 2016;32:1333–42.
- [11] Scimeca M, Pietroiusti A, Milano F, et al. Elemental analysis of histological specimens: a method to unmask nano asbestos fibers. *Eur J Histochem* 2016;60:2573.
- [12] Barbato L, Francioni E, Bianchi M, et al. Periodontitis and bone metabolism. *Clin Cases Miner Bone Metab* 2015;12:174–7.
- [13] Gapski R, Wang HL, Mascarenhas P, et al. Critical review of immediate implant loading. *Clin Oral Implants Res* 2003;14:515–27.
- [14] Weitzmann MN. The role of inflammatory cytokines, the RANKL/OPG axis, and the immunoskeletal interface in physiological bone turnover and osteoporosis. *Scientifica (Cairo)* 2013;2013:125705.
- [15] Thompson WR, Rubin CT, Rubin J. Mechanical regulation of signaling pathways in bone. *Gene* 2012;503:179–93.
- [16] Klopp E, Graff D, Struckmeier J, et al. The osteoblast mechano-receptor, microgravity perception and thermodynamics. *J Gravit Physiol* 2002; 9:269–70.